

A Case of Osseous Metaplastic Paraprostatic Cyst in a Boxer Dog

M. Maden, O. Ozdemir, O.F. Hatipoglu, A.S. Ozturk and M. Arican
Department of Veterinary Clinical Science, Veterinary Internal Medicine,
Oveterinary Pathology, Veterinary Surgery, University of Selcuk, Konya, Turkey

Abstract: This report describes a paraprostatic cyst in a sexually intact 7 years old Boxer. The clinical history of the dog revealed dysuria, hematuria, constipation and lameness in the right hind leg. An abdominal mass were discovered on clinical examination of the dog. Transabdominal ultrasonographic examination showed an abdominal mass with a cavernous pattern and a hyperechoic wall. The mass was filled with anechoic fluid and was observed to be related to the prostate and adjacent to the urinary bladder. It was decided to remove the mass surgically. Microscopic evaluation of the cystic mass revealed necrotic debris in the lumen along with fibrin; the cyst wall was rich in fibrous tissue and contained bony structures. The prostatic cyst described in this study was identified as an osseous metaplastic paraprostatic cyst on the basis of the clinical, laboratory, ultrasonographic and microscopic findings.

Key words: Cyst, prostate, abdominal mass, ultrasonography, osseous metaplasia, dog

INTRODUCTION

Diseases of the prostate gland are seen in intact male dogs, especially of middle-sized and large breeds (Krawiec and Heflin, 1992). Prostatic disorders include benign prostatic hyperplasia, squamous metaplasia, prostatic cyst, acute or chronic bacterial prostatitis, prostatic abscess and neoplasia (Paclicova *et al.*, 2006).

Prostatic cysts in dogs have been divided into two classes: Parenchymal and non-parenchymal cysts (Jubb *et al.*, 1985; Gorman, 1996). An alternative classification divides prostatic cysts in dogs into 4 types: multiple cysts associated with prostatic hypertrophy, retention cysts, paraprostatic cysts and cysts associated with squamous metaplasia (Barsanti and Finco, 1995). The prevalence of prostatic cysts in adult, intact male dogs has been reported to be 2.6-5.3% (Weaver, 1978), 2 (1.13%) of 177 cases (Krawiec and Heflin, 1992) and 12 (14%) of 85 dogs (Black *et al.*, 1998).

Paraprostatic cysts are large structures that develop between the prostate gland and the urinary bladder (Olson *et al.*, 1987). Paraprostatic cysts have very little to do with the prostate gland directly (Johnston *et al.*, 2000) but a close association is not necessary (Wallace, 2001). Mineralization may be seen in the cyst wall (Barr, 1990; Girard and Despots, 1995; Zekas *et al.*, 2004; Paclicova *et al.*, 2006) and cartilaginous or osseous

metaplasia can occasionally be observed in the walls of these cystic structures (Girard and Despots, 1995; Gorman, 1996; Wright *et al.*, 1996; Zekas *et al.*, 2004). Radiography and diagnostic ultrasonography along with clinical and laboratory findings have been used successfully in the diagnosis of prostatic disease (Weaver, 1978; Jubb *et al.*, 1985; Maden *et al.*, 2000; Head and Francis, 2002; Paclicova *et al.*, 2006). Ultrasonography allows much more sensitive imaging of the prostate than radiology and facilitates very detailed inspection of the inner structure and morphology of the gland (Johnston *et al.*, 1989).

Paraprostatic cysts can be seen as an additional fluid-filled sac, commonly adjacent to the urinary bladder (Barr, 1990; Mattoon and Nyland, 1995; Miyabayashi, 2001). Basic treatment methods for paraprostatic cysts include resection, marsupialization or partial prostatectomy (Weaver, 1978; Bakalov *et al.*, 2004).

CASE STUDY

In this report, a case of osseous metaplastic paraprostatic cyst was defined on the basis of clinical, laboratory, ultrasonographic and histopathologic findings in a boxer dog. The dog was seven years old, male and sexually intact when it was admitted to the Department of Internal Medicine at the Faculty of Veterinary Medicine, University of Selcuk, Konya, Turkey.

Table 1: Laboratory findings

Blood/Serum	Values	Urine	Values
WBC (10^3 mm^{-3})	9.7	pH	7.5
RBC (10^6 mm^{-3})	7.64	Specific gravity	1015
PCV (%)	48.3	Protein	-
HGB (g dL ⁻¹)	16.2	Oculta blood	-
MCV (um ³)	63.1	Nitrite	-
MCH (pg)	21.2	WBC/HPF	TNTC*
MCHC (g dL ⁻¹)	33.6	RBC/HPF	TNTC*
PLT (10^3 mm^{-3})	435	Transitional epithel	1-3
BUN (mg dL ⁻¹)	16.9	Renal epithel	3-5
CR (mg dL ⁻¹)	1.80	Casts/HPF	1-2 granular

*TNTC = Too Numerous To Count, HPF = High Power Field (WBC: White Blood Cell, RBC: Red Blood Cell, PCV: Packed Cell Volume, HGB: Haemoglobin, MCV: Mean Corpuscular Volume, MCH: Mean Cell Haemoglobin, MCHC: Mean Corpuscular Haemoglobin Concentration, PLT: Platelet, BUN: Blood Urea Nitrogen, CR: Creatinine)

History: The presenting complaints were a swelling the size of an egg located in the left abdominal wall, anorexia and cachexia. The clinician was informed that the dog had been suffering from dysuria and bloody urine for 2 d together with constipation and lameness in the right hind leg.

Physical examination findings: Hypertrophy of the left inguinal lymph node and an intra-abdominal mass the size of a handball (50-60 cm diameter) were found on clinical examination of the dog. The prostate gland was painless, immobile, asymmetric and elongated. Its border with the horizontal right lobe of the prostate gland was indistinct on rectal examination.

Laboratory findings: Pyuria and hematuria were found on examination of a urine sample while the hematologic findings were normal (Table 1). A sample of fluid was obtained by ultrasound-guided needle aspiration of the abdominal mass. The fluid was reddish-brown and a large number of erythrocytes and several leukocytes were seen on cytological examination. No bacteria were isolated by bacteriologic culture of fluid aspirated from the abdominal mass.

Ultrasonographic examination findings: Hypertrophy of the left inguinal lymph node and an abdominal mass connected to the prostate gland and adjacent to urinary bladder were demonstrated on ultrasonographic examination. The intra-abdominal mass had a cavernous structure and its wall was hyperechoic while its contents were anechoic (Fig. 1a, b).

Surgical findings: During the surgical operation, it was discovered that the intra-abdominal mass was connected to the prostate gland and adjacent to the urinary bladder (Fig. 2a, b). The mass contained 2.5-3 L of reddish-brown fluid. This fluid was emptied and the mass was

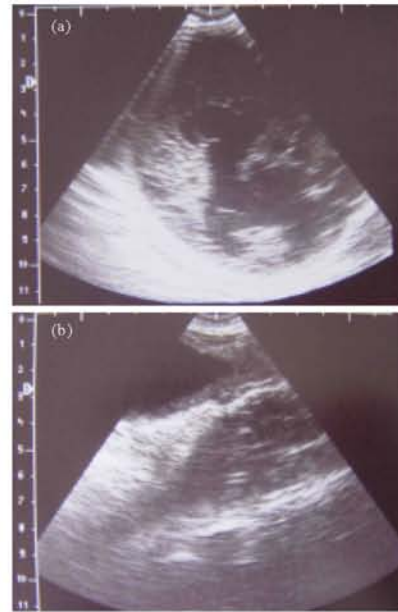


Fig. 1: (a) Abdominal mass adjacent to urinary bladder and (b) Intra-abdominal mass with cavernous structure

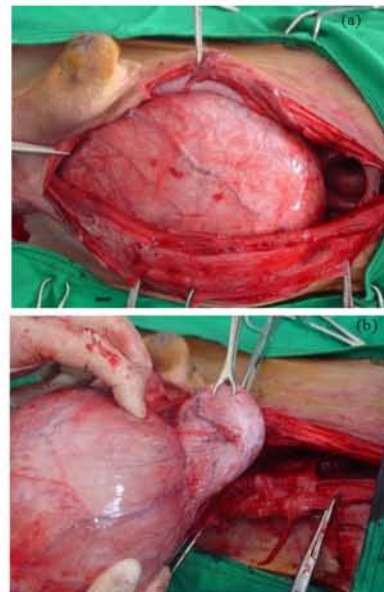


Fig. 2: (a) Intra-abdominal mass and (b) The mass adjacent to urinary bladder

excised from the prostate by ligation. The wall of the mass which was totally extirpated was hard with osseous structures (Fig. 3a). The neck part of the mass was observed bony formed cystic wall when removed from the prostate, the lumen of the mass was found to be filled with necrotic tissue (Fig. 3b).

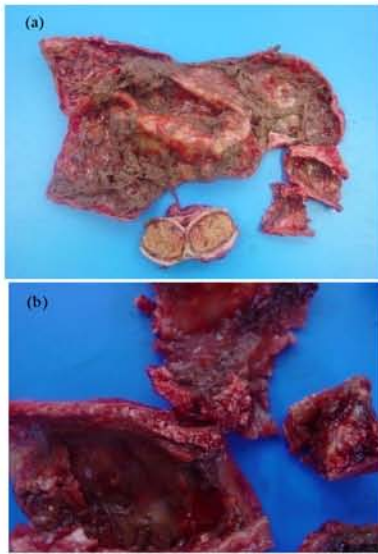


Fig. 3: (a) Internal structure of intra-abdominal mass and hypertrophic left inguinal lymph node and (b) The wall structure of intra-abdominal mass

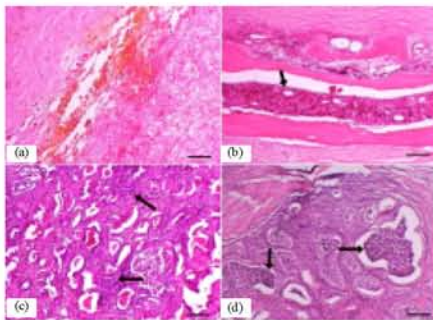


Fig. 4: (a) Fibrous cyst wall and necrotic debris in the lumen, (b) Myeloid tissue (black arrow) and bony structures in the cyst wall, (c) Fibrous tissue increase in the interstitium along with mononuclear cell infiltration (arrows) and (d) Neutrophil accumulations in the lumen (arrows) H and E, Bar: 200 micron

Histopathologic findings: Microscopic evaluation of the cystic mass revealed necrotic debris in the lumen along with fibrin; the cyst wall was rich in fibrous tissue and contained bony structures. The hyperplastic prostate was characterized by increased epithelial tissue and papillar formations while fibrous tissue was increased in the interstitium and mononuclear cell infiltration and neutrophil accumulations were detected in the lumen (Fig. 4a-d).

This study describes the diagnosis of an osseous metaplastic paraprostatic cyst, a type of prostatic cyst which is reported only occasionally in a sexually intact 7 years old boxer dog. The clinical findings

associated with paraprostatic disease previously reported in dogs include systemic signs, gastrointestinal signs, lower urinary tract disorders, musculoskeletal manifestations and reproductive problems (Barsanti and Finco, 1993; Gorman, 1996; Johnston *et al.*, 2000; Head and Francis, 2002; Paclicova *et al.*, 2006).

In two case reports of mineralized paraprostatic cysts it was noted that abdominal distention, pollakuria, hematuria, bloody urethral discharge and mild proteinuria are common clinical findings. These researchers also reported the finding of an intra-abdominal mass in the caudal abdomen that had mineralization and hyperechogenicity in the wall structure on radiographic and ultrasonographic examination (Girard and Despots, 1995; Mattoon and Nyland, 1995; Zekas *et al.*, 2004).

In the case reported herein, anorexia, cachexia, dysuria, hematuria, pyuria, constipation, locomotory disorders and lameness in right hind leg, together with an immobile, painless and asymmetric prostate gland on rectal palpation were the clinical findings associated with prostatic disease. The normal hematologic findings and the palpation of a painless and immobile prostate gland suggested a non-inflammatory process in the prostate gland. The asymmetry in the right lobe of the prostate gland was interpreted to represent intra-abdominal progression of the paraprostatic cyst while the hematuria and pyuria were considered to be the results of secondary lower urinary tract infection.

On clinical examination, hypertrophy of the left inguinal lymph node and an intra-abdominal mass were detected in this case. It was determined that the intra-abdominal mass was connected to the prostate gland and adjacent to the urinary bladder on ultrasonographic examination. Ultrasonography is a useful tool in the assessment of prostatic size, surface contour and parenchymal pattern (Barsanti and Finco, 1993; Miles, 1989; Cartee *et al.*, 1998; Dorfman and Barsanti, 1995; Mattoon and Nyland, 1995; Maden *et al.*, 2000).

An increase in the echogenicity of the prostate gland can be observed in most prostatic disorders including stromal proliferation, chronic inflammation, neoplasia, fibrosis and hyperplasia while a decrease in echogenity may indicate a retention cyst, abscess, acute inflammation or parenchymal oedema (Feeney *et al.*, 1985, 1987; Adams and Evans, 1989; Barsanti and Finco, 1993; Barr, 1990). Mineralization can be seen occasionally and segments of cartilaginous or osseous metaplasia may be found within the wall of the cystic structure (Girard and Despots, 1995; Wright *et al.*, 1996; Zekas *et al.*, 2004).

The intra-abdominal paraprostatic cyst reported here was connected with the prostate gland. Ultrasonographic examination showed that it had a cavernous structure and

its wall was hyperechoic while its contents were anechoic. The ultrasonographic findings and negative bacteriologic culture of the contents of the abdominal mass supported the diagnosis.

The intra-abdominal mass was diagnosed as an osseous metaplastic paraprostatic cyst because of its bony structure and the presence of myeloid tissue in the wall of cyst, observed on histopathologic examination.

CONCLUSION

Researchers recommend that clinical and laboratory findings along with ultrasonographic and histopathologic examinations should be evaluated in the diagnosis of prostate diseases. Ultrasonographic examination can be useful in the differential diagnosis of intra-abdominal masses and prostatic hypertrophy.

REFERENCES

- Adams, C.D. and L.E. Evans, 1989. Ultrasound as a diagnostic tool in equine and small animal. *Medicine*, 51: 43-47.
- Bakalov, D., N. Goranov and R. Simeonov, 2004. Canine paraprostatic cyst-a case report. *Vet. Arch.*, 74: 85-94.
- Barr, F.J., 1990. *Diagnostic Ultrasound in the Dog and Cat*. The Blackwell Science Ltd., London, PA., pp: 65-77.
- Barsanti, A.B. and D.R. Finco, 1995. Prostatic Diseases. In: *Textbook of Veterinary Internal Medicine*, Ettinger, S.J. and E.C. Feldman (Eds.). 4th Edn., WB Saunders Comp., Philadelphia, PA., pp: 1662-1685.
- Barsanti, J.A. and D. Finco, 1993. Canine Prostatic Diseases. In: *Textbook of Veterinary Internal Medicine*, Ettinger S.J. (Ed.). 3rd Edn., WB Saunders Company, Philadelphia, PA., pp: 1859-1880.
- Black, G.M., G.V. Ling, T.G. Nyland and T. Baker, 1998. Prevalence of prostatic cysts in adult, large-breed dogs. *J. Am. Anim. Hosp. Assoc.*, 34: 177-180.
- Cartee, R.E., P.F. Rumph, D.C. Kenter, J.C. Cooney and D. Frank *et al.*, 1998. Evaluation of drug-induced prostatic involution in dogs by transabdominal B-mode ultrasonography. *Am. J. Vet. Res.*, 51: 1773-1778.
- Dorfman, M. and J.A. Barsanti, 1995. Diseases of the canine prostate gland. *Compend. Contin. Edu. Pract. Vet.*, 17: 791-810.
- Feeney, D.A., G.R. Johnston and J.S. Klausner, 1985. Two-dimensional grayscale abdominal ultrasonography: Applications in canine prostatic disease. *Vet. Clin. North Am., Small Anim. Pract.*, 15: 1159-1176.
- Feeney, D.A., G.R. Johnston and J.S. Klausner, 1987. Canine prostatic disease-comparison of ultrasonographic appearance with morphologic and microbiologic findings: 30 cases (1981-1985). *J. Am. Vet. Med. Assoc.*, 190: 1027-1034.
- Girard, C. and J. Despots, 1995. Mineralized paraprostatic cysts in a dog. *Can. Vet. J.*, 36: 573-574.
- Gorman, N.T., 1996. Diagnosis and Management of Canine Prostatic Disease. In: *BSAVA Manual of Canine and Feline Nephrology and Urology*, Bainbridge, J. and J. Elliot (Eds.). 1st Edn., British Small Animal Veterinary Association, Kingsley House, PA., pp: 174-184.
- Head, L.L. and D.A. Francis, 2002. Mineralized paraprostatic cyts as a potential contributing factor in the development of perineal hernias in a dog. *J. Am. Vet. Med. Assoc.*, 221: 533-535.
- Johnston, G.R., J.S. Klausner and F.W. Bell, 1989. Canine prostatic ultrasonography. *Seminars Vet. Med. Surg.*, 4: 44-49.
- Johnston, S.D., K. Kamolpatana, M.V. Root-Kustritz and G.R. Johnston, 2000. Prostatic disorders in the dog. *Anim. Reprod. Sci.*, 60-61: 405-415.
- Jubb, K.V.F., P.C. Kennedy and N. Palmer, 1985. *Pathology of Domestic Animals*. 3rd Edn., Academic Pres Inc., California, PA., pp: 450-454.
- Krawiec, D.R. and D. Heflin, 1992. Prostatic diseases in dogs: 177 cases (1981-1986). *J. Am. Vet. Med. Assoc.*, 200: 1119-1122.
- Maden, M., F.M. Birdane and I. Sen, 2000. The role of ultrasonography in the diagnosis of bacterial prostatitis in dogs. *Indian Vet. J.*, 77: 1073-1077.
- Mattoon, J.S. and T.G. Nyland, 1995. *Veterinary Diagnostic Ultrasound*. W.B. Saunders Company, Philadelphia, PA., pp: 157-158.
- Miles, G.M., 1989. Basic principles and clinical applications of diagnostic ultrasonography. *Compend. Contin. Edu. Pract. Vet.*, 11: 609-624.
- Miyabayashi, T., 2001. Urogenital ultrasound. *Proceedings of the 26th Congress World Small Animal Veterinary Association*, Aug. 8 -11, Vancouver, British Columbia, Canada, pp: 282-285.
- Olson, P.N., R.H. Wrigley, M.A. Thrall and P.W. Husted, 1987. Disorders of canine prostate gland: Pathogenesis, diagnosis and medical therapy. *Compend. Contin. Edu. Pract. Vet.*, 9: 613-624.

- Paclicova, K., P. Kohout and M. Vlasin, 2006. Diagnostic possibilities in the management of canine prostatic disorders. *Vet. Med.*, 51: 1-13.
- Wallace, M.S., 2001. Diagnosis and medical management of canine prostatic disease. *Proceedings of the Atlantic Coast Veterinary Conference*, Oct. 9-11, Atlantic City, New Jersey, pp: 55-82.
- Weaver, A.D., 1978. Discrete prostatic (paraprostatic) cysts in the dog. *Vet. Record*, 102: 435-440.
- Wright, K.N., R.C. Jr., DeNovo, C.S. Patton, J.E. Sackman, B. Wilkens and R.E. Gompf, 1996. Effusive-constrictive pericardial disease secondary to osseous metaplasia of the pericardium in the dog. *J. Am. Vet. Med. Assoc.*, 209: 2091-2095.
- Zekas, L.J., L.J. Forrest, S. Swainson and L.A. Phillips, 2004. Radiographic diagnosis: Mineralized paraprostatic cyst in a dog. *Vet. Radiol. Ultrasound*, 45: 310-311.