



## Management of AO Type B&C Fractures of Distal Humerus in Adults with Two Column Fixation

Manjit S. Daroch, Deepak Vashisht, Sanjjiv Sreen, Parveen Puri, K.S. Sandhu and Gaganpreet singh  
*Department of Othopaedics, Govt. Medical College and Rajindra Hospital, Patiala, Punjab, India*

**Key words:** Adults, distal humerus, type C fractures, olecranon, posterior approach

**Abstract:** Accurate reconstruction of articular surface of distal humerus by closed manipulation is not possible. The recent trend for displaced intra-articular fractures of the distal humerus is open reduction and stable osteosynthesis with early rehabilitation. The best exposure of both columns of the distal part of the humerus and articular surface is achieved through trans-olecranon approach. To evaluate the management and outcome of two column fixation of intra-articular fracture of distal humerus in adults by posterior approach via. olecranon osteotomy and to restore early elbow joint function. Twenty-five cases of intra-articular fractures of distal humerus were treated by open reduction and internal fixation. All the patients were of adult age group.. Chevron type olecranon osteotomy was performed and fixed with tension band wiring in all cases and follow-up period was upto 36 months. Regular clinical examination and periodical radiological evaluation were done. All fractures united within average duration of 3 months. Results were evaluated as per Mayo Elbow performance score. According to this criteria, excellent result was achieved in 8 patients (32%), good in 13 (52%), fair in 3 (12%) and poor in 1 (4%) patients. Thus, satisfactory result was obtained in 96% cases. The critical factors for a successful outcome of intra-articular fractures of the distal humerus depends upon severity of fracture, meticulous surgical technique, stable internal fixation, surgical experimentation and early controlled postoperative mobilization.

### Corresponding Author:

Deepak Vashisht  
#1575A, Sector-20B, 160020 Chandigarh, India

Page No.: 1-13

Volume: 13, Issue 1-4, 2018

ISSN: 1816-3211

Surgery Journal

Copy Right: Medwell Publications

## INTRODUCTION

Distal humerus fractures remain one of the most difficult injuries to manage. They are commonly multifragmental, occur in osteopenic bone and have

complex anatomy with limited options for internal fixation. Treatment outcomes are often associated with elbow stiffness, weakness and pain. A painless, stable and mobile elbow joint is desired as it allows the hand to conduct the activities of daily living, most notably

personal hygiene and feeding. Therefore, meticulous planning is required in determining the operative indications, managing the soft tissues, selecting a surgical approach, obtaining an anatomic intra articular reduction, and creating a fixation construct that is rigid enough to tolerate early mobilisation (Athwal, 2010).

In the last quarter of century improved outcomes have been reported with surgery for distal humerus fractures. The principles set out by the Arbeitsgemeinschaft für Osteosynthesefragen (Association for the Study of Internal Fixation, AO-ASIF) group, including anatomic articular reduction and rigid internal fixation, allow for rapid healing and early postoperative range of motion. The last decade has seen advances in the understanding of elbow anatomy, improvements in surgical approaches, new innovative fixation devices and an evolution of post-operative rehabilitation protocols. Precontoured locking plates for posterior column, medial column and for fixation of olecranon osteotomy by AO group is new and effective method of fixation in distal humeral fractures and more effective in osteoporotic bone (Athwal, 2010).

Plates applied on distal humerus at right angle to each other create 'Girdle like effect' which strengthen fixation construct. Plates should end at different levels on humeral shaft to minimize the 'stress riser' effect. Each plate should have at least 3 bicortical screws proximal to metaphyseal comminution (Athwal, 2010). Every screw should pass through a plate. Each screw should engage a fragment on the opposite side that is also fixed to plate. As many screws as possible should be placed in the distal fragments. Each screw should be as long as possible. Each screw should engage as many articular fragments as possible. Plates should be applied such that compression is achieved at the supracondylar level for both columns. Plates used must be strong enough and stiff enough to resist breaking or bending before union occurs at the supracondylar level (Crenshaw and Perez, 2008).

In younger patients, open reduction and internal fixation of distal humerus fractures using modern fixation principles is considered the gold standard. In elderly patients, restoration of the anatomy and obtaining rigid internal fixation may be difficult because of poor bone quality and comminution of the articular surface and metaphysis. In cases in which rigid internal fixation cannot be achieved to allow early range of motion, resultant prolonged immobilization often leads to poor outcomes (Athwal, 2010).

Incidence of distal humeral fractures is increasing. Distal humerus fractures comprise 2-6% of all fractures. There is a bimodal distribution with respect to age and gender with peak incidence in young male and in older female patients. Most fractures in elderly patients are intra-articular with biocolumnar involvement (Athwal, 2010).

## **MATERIALS AND METHODS**

This was a prospective interventional study which included 25 consecutively admitted cases of intra-articular fractures (AO B&C type) of distal humerus in adults (>15 years of age). Criteria for exclusion from the study was anterior coronal fracture of capitulum or trochlea and open fractures which are badly contaminated. Primary treatment in the form of splint age of limb, analgesics and anti-inflammatory drugs, immunization against tetanus in open fracture and intravenous fluids in multiple injuries was given. All patients were taken for elective surgery as soon as possible after necessary blood, urine and radiographic pre-operative work-up. General anaesthesia or regional anaesthesia was used after proper pre-medication as per the anaesthetist recommendation. Trans olecranon posterior approach was used as it gives visualization of the articular surface for reduction and fixation. Disadvantages are non-union and hardware prominence related to osteotomy and linked visualization of anterior articular surfaces (Brown and Morgan, 1971). In our study, we used 3.5 mm reconstruction plates of appropriate size mostly which will be contoured according to the need and appropriate size cortical screws along with Kirschner wires and stainless steel wires for tension band wiring of osteotomised olecranon.

Patient was placed in a lateral decubitus or supine position. A midline posterior incision was made over the distal humerus with or without curving around the tip of olecranon. The Ulnar Nerve was identified and protected. An olecranon chevron osteotomy was used for adequate exposure of the joint surface with the osteotomy being placed at the lowest point of the trochlear notch. The Anconeus Muscle was elevated as a flap to preserve its innervation and olecranon osteotomy was done in most of cases. The osteotomy was started with an oscillating saw but completed using a fine osteotome through the subchondral bone. Later on osteotomy was fixed with tension band wiring in all cases. The articular fragments were reduced and held with a partially threaded cancellous screw or cortical screws. They were then secured to the columns. In most cases two reconstructional plates (3.5 mm) were contoured to the distal humerus. One plate was placed on medial column and one on the posterior aspect of the lateral column (90° to each other).

Light posterior plaster splint was given for 3 days which was replaced by hinge brace and gentle active or active-assisted exercises were carried out as soon as possible as pain permits. Parenteral broad-spectrum antibiotics were given for 4 days then Oral antibiotics till suture removal. Post operatively ASD done on 3rd, 7th and 11th day. Stitches were removed from 11th-14th postoperative day as per the condition of the wound. Analgesics and anti-inflammatory drugs were given as

required. All patients were followed up at monthly intervals for 6 months. During this period patient was motivated for physiotherapy and gradual normal use of the affected limb. Fracture union was assessed clinically and radiologically. Elbow function on the operated side was evaluated and compared with the normal side as per Mayo elbow score (Dawson *et al.*, 1996).

## RESULTS

In the present study, 25 cases of supracondylar intra articular fracture of humerus in adults, treated with two column fixation via olecranon osteotomy. Intra-articular fractures of the distal humerus occurred in all age groups but were more common in younger age from 16-35 years. There was more number of males than females with a male female ratio of 3:2. Most of the fractures are the result of road side accidents. Left humerus was found to be more commonly involved. About 88% of patients had closed fractures and among those with open fractures, Grade III (12%) fractures were the more common. There were associated injuries in 28% of cases like fracture ulna, fracture BB leg or nerve injuries. About 5 out of 25 cases had associated medical illness. About 1 had diabetes mellitus type-2, 3 had hypertension and 1 had both DM-2 and HTN. Most of the patients were operated within 24 h of injury. Most of the fractures are of C1 type as per AO system of classification. At the average follow up of 20 months, the flexion at the elbow joint ranged from 70-140° with an average of 120.2°. About 21 patients had a flexion beyond 110° (84%). And average loss of extension ranged from 0-30° with an average of 14.2°. All the patients have extension loss <30°. About >100° of range of movement is obtained in 56% of cases. In most the cases functional arc of motion (30-110°) is preserved. Scoring of range of motion is done as per Mayo Elbow performance score<sup>4</sup>. Most of the fixations are stable. About 5 (20%) patients suffered transient Ulnar N Neuropraxia in the early post-operative period. No patient suffered from iatrogenic vascular injury. Hardware failure in 3, painful hardware in 4, superficial infection in 3, non-union of olecranon osteotomy in 1, elbow stiffness in 6 and 3 had cubitus varus deformity.

## DISCUSSION

In the present study most of the fractures (64%) occurred in the younger age group, i.e., 16-35 years. Males constituted the largest group (60%) in the study with a male-female ratio of 3:2. The low incidence of females in our study was probably because of less incidence of road traffic accidents in females due to less outdoor activities in females. Sixteen (64%) of the patients had injury of left side and rest nine (36%) had injury of right humerus. About 88% of patients had closed

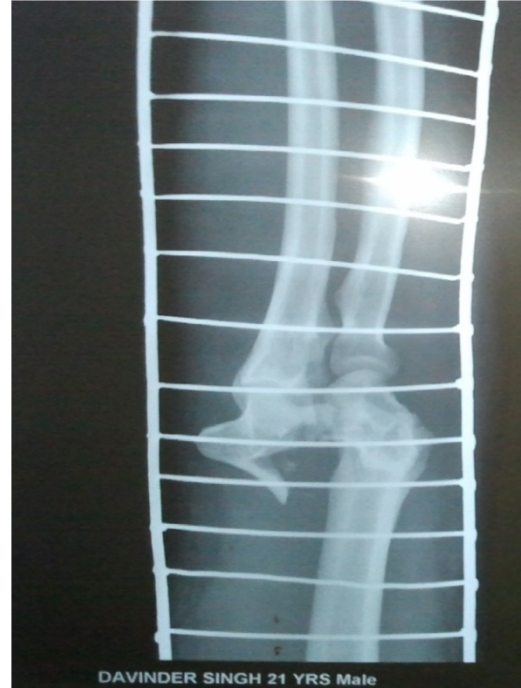

Fig. 1: Case 1 Preoperative X ray AP view

fractures and among those with open fractures, Grade III (12%) fractures were the more common. Road side accident was the most common mode of injury in 68% patients followed by those sustaining the fracture due to falls (20%). Since, most of the fractures were the result of high velocity trauma, there was high incidence of associated injuries (28%). In the present study, 13 patients had C1 (52%), 8 had C2 (32%), 3 had C3 (12%) and 1 had type B1 (4%) fracture configurations according to AO classification. There was more number of C type fracture (96%) and out of them C1 type is more common (52%). Time elapsed between injury and surgery ranged from 12-24 h with most patients (72%) being operated between 12-24 h of injury. 18 out of 25 patients (72%) were managed within 24 h of presentation. 4 patients (18%) were given definitive treatment within a few days but a few (8%) had to wait for more than a week for definitive management either because they were managed initially at other centres or because of associated problems which were either an associated injuries or systemic problems. All patients were treated by open reduction and internal fixation with two column fixation with orthogonal plates followed by early physiotherapy. In this study, results were evaluated according to Mayo Elbow performance score<sup>4</sup>. According to this criteria, excellent result was achieved in 8 patients (32%), good in 13 (52%), fair in 3 (12%) and poor in 1 (4%) patients. Thus, satisfactory result was obtained in 96% cases (Fig. 1-28).

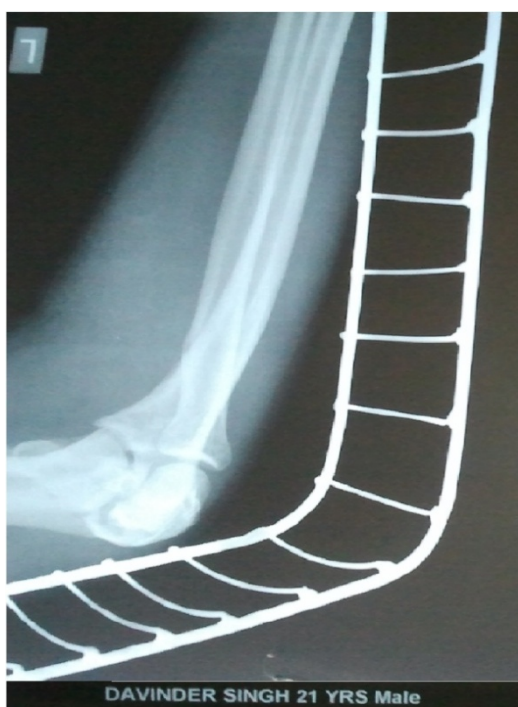

Fig. 2: Case 1 preoperative X ray lateral view

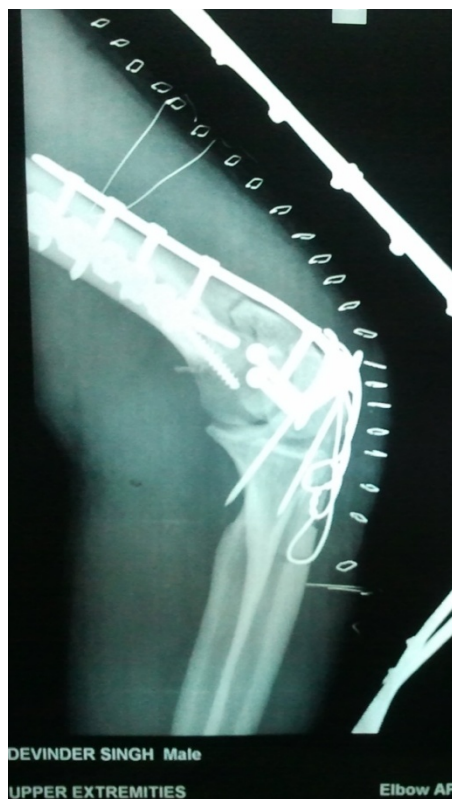

Fig. 4: Case 1 postoperative X ray lateral view

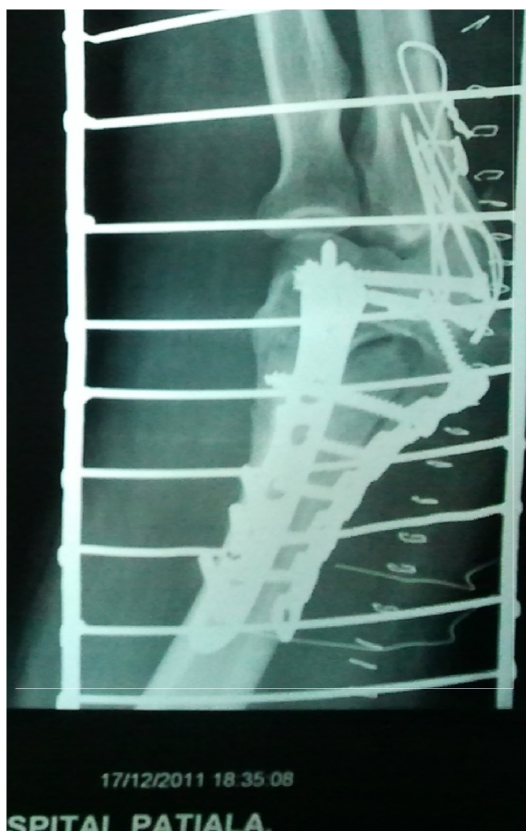

Fig. 3: Case 1 postoperative X ray AP view

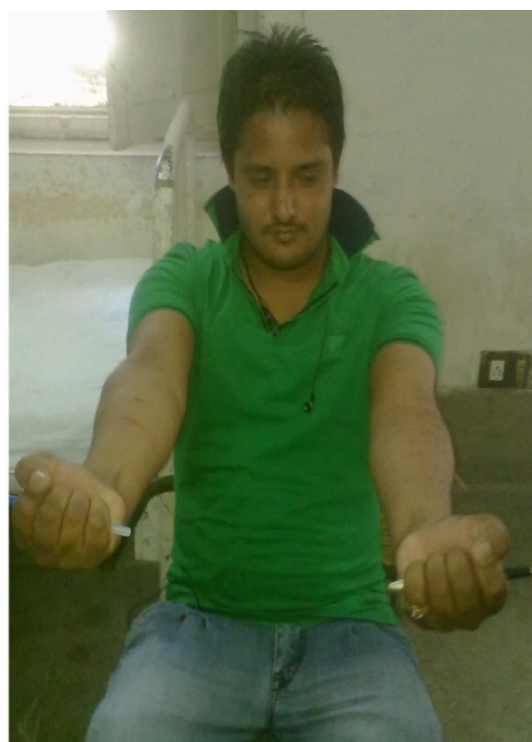

Fig. 5: Case 1 follow up 12 weeks clinical photograph 3





Fig. 6: Case 1 follow up 12 weeks clinical photograph 2



Fig. 8: Case 1 follow up 12 weeks clinical photograph 4



Fig. 7: Case 1 follow up 12 weeks clinical photograph 1



Fig. 9: Case 1 follow up 12 weeks clinical photograph 5

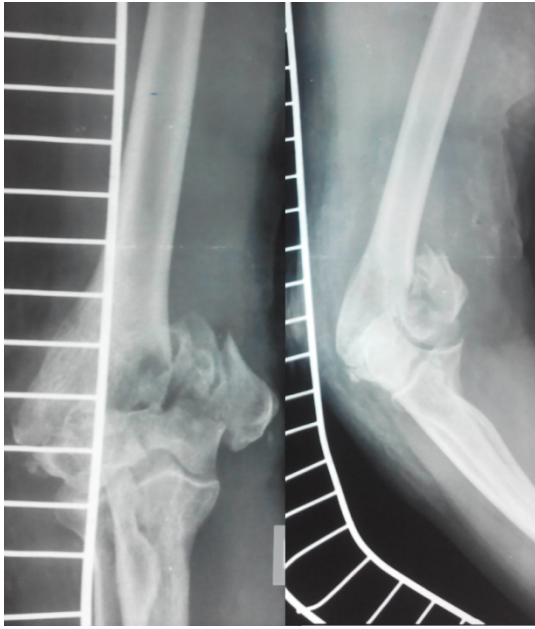


Fig. 10: Case 2 preoperative X ray AP and lateral view

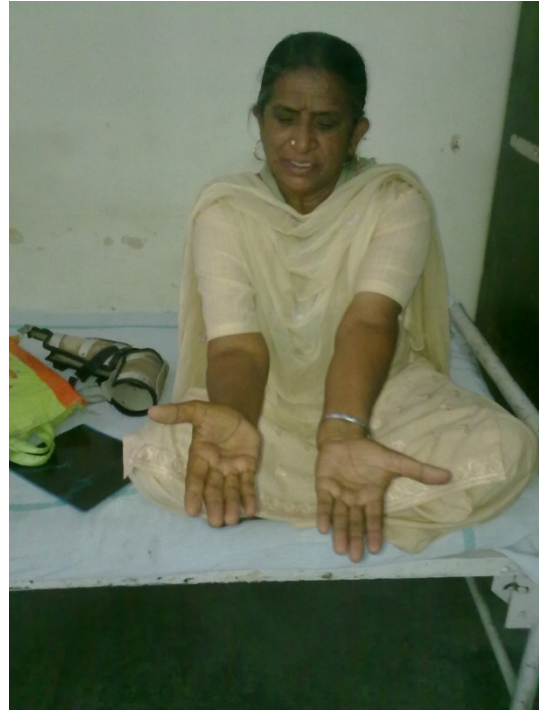

Fig. 12: Case 2 follow up 20 weeks clinical photograph 1

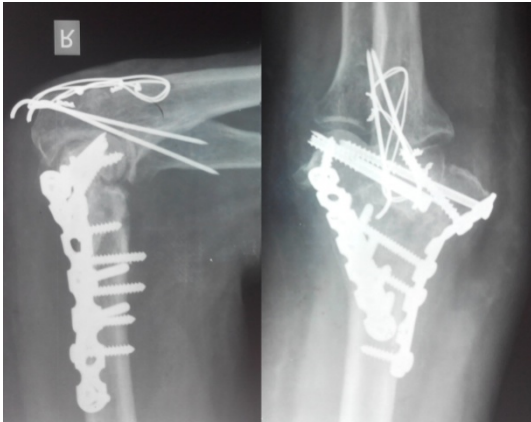


Fig. 11: Case 2 post-operative X ray AP and lateral view

Rigid fixation and early rehabilitation are the most important goals in treatment of type C elbow fracture. In our study, posterior approach with olecranon osteotomy was used in distal humerus fracture. The advantages of this approach are exposure of the intra-articular fragments which aids in good reduction and the implementation of early functional exercises is possible. Articular restoration is the most essential step followed by stabilization of the largest columnar fragment. The aim is to facilitate biomechanical reconstruction of the two-column structure which was carried out in all 25 cases in our study. In each case, fracture reduction was satisfactory, fixation was strong and durable, fracture site




Fig. 13: Case 2 follow up 20 weeks clinical photograph 2

stable and early post-surgical functional exercise was possible. In our series, at the time of injury 1 patient had ulnar nerve palsy and 1 patient had radial nerve which



completely recovered over a period 10 months. Post-operatively, 5 patients had transient ulnar nerve Neuropraxia (which was completely recovered after 3 months), 3 patients had superficial infection which got

better with antibiotics and dressings. Some degree of loss of extension is seen in most of the cases,  $>20^\circ$  of stiffness is seen in 6 patients. Other complications encountered in our series were varus deformity in 3 patients, hardware



Fig. 14: Case 2 follow up 20 weeks clinical photograph 3



Fig. 15: Case 2 follow up 20 weeks clinical photograph 4

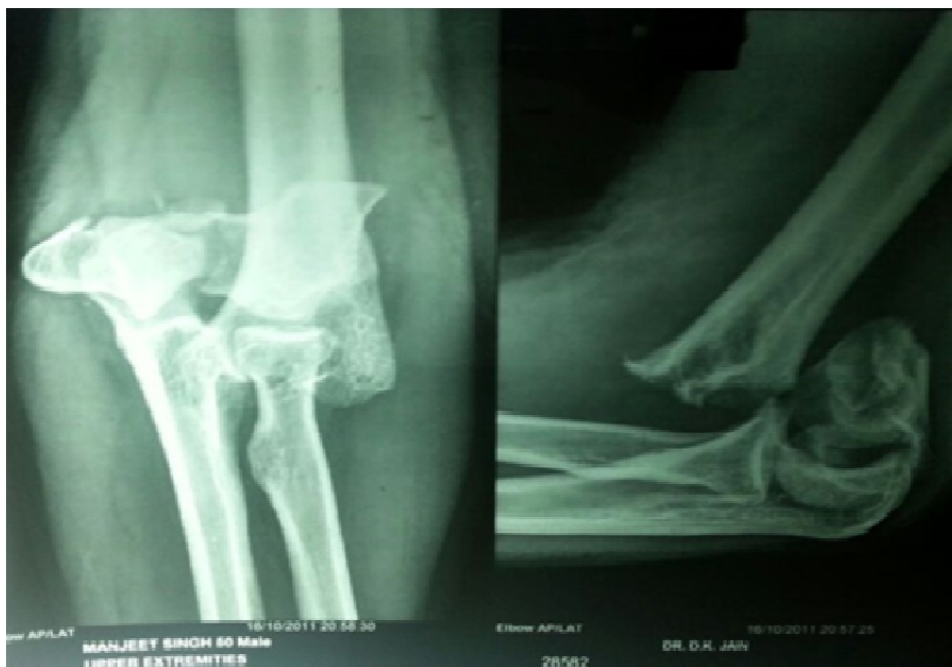

Fig. 16: Case 3 preoperative X ray AP and lateral view

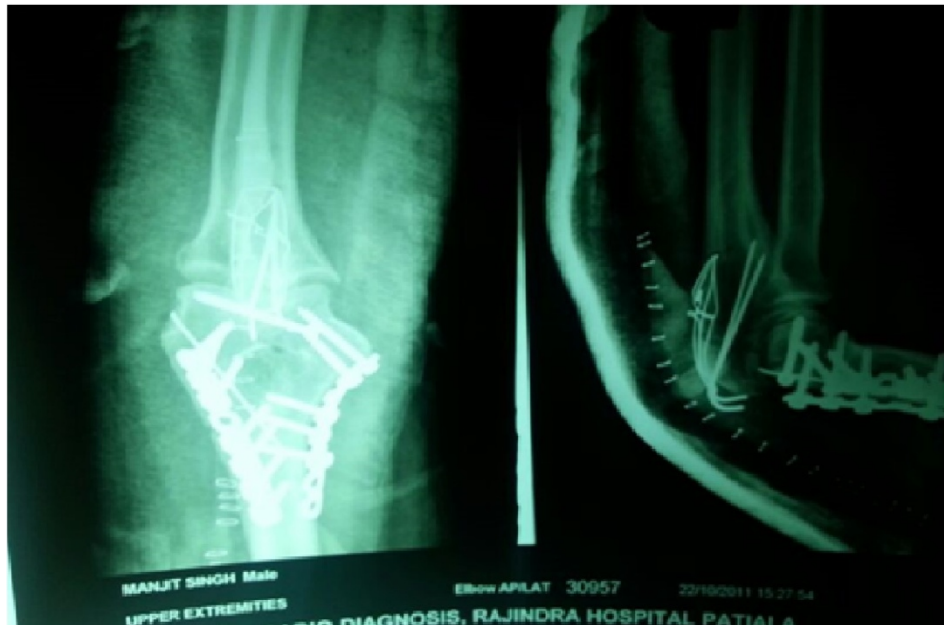

Fig. 17: Case 3 post-operative X ray AP and lateral view

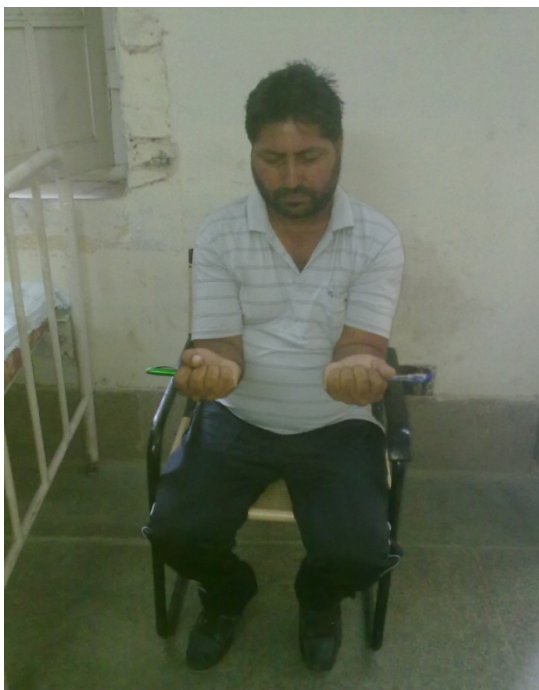

Fig. 18: Case 3 follow up 12 weeks clinical photograph 1

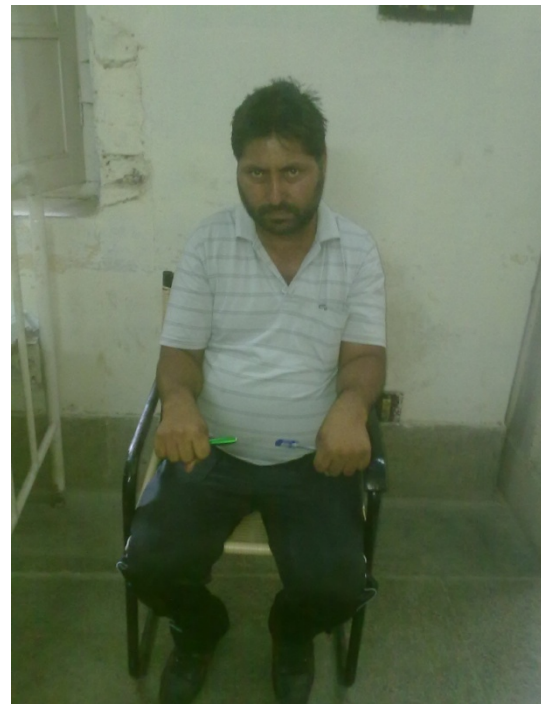

Fig. 19: Case 3 follow up 12 weeks clinical photograph 2

failure in 3 patients, non-union of olecranon osteotomy in 1 patient, 17 patients had mild pain and 7 patients had no pain at all. Pain at final follow up was not related to the type of fracture. Henley (1987) in their series of 33 patients observed fixation failure in 5 patients, infection

in 2 patients, one superficial and one deep and heterotopic ossification in 2 patients. Sodegard *et al.* (1992) in his series of 96 patients encountered 6 post-operative infections, 12 neural injuries and 16 fixation failures. Thus, the complications in our study was comparable to



other studies. It is important to realize that final outcome of painless, functional range of motion at elbow causing no disability is more important than a sound radiographic and anatomic union. At the average follow up of 20 months, the average flexion achieved was  $120.2^{\circ}$  ranged from  $70-140^{\circ}$ . The 21 patients had a flexion

beyond  $110^{\circ}$  (84%). The average loss of extension was  $14.2^{\circ}$  ranged from  $0-30^{\circ}$ . In most the cases functional arc of motion ( $30-110^{\circ}$ ) is preserved. The 17 patients had a mild pain not limiting their activities of daily living. 1 patients had a moderate disability, so that, he could not work in the same job which they used to do before

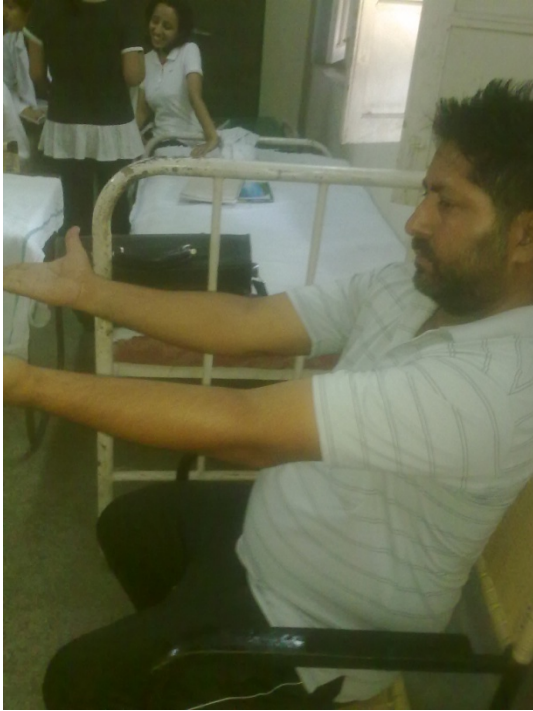

Fig. 20: Case 3 follow up 12 weeks clinical photograph 3



Fig. 21: Case 3 follow up 12 weeks clinical photograph 4

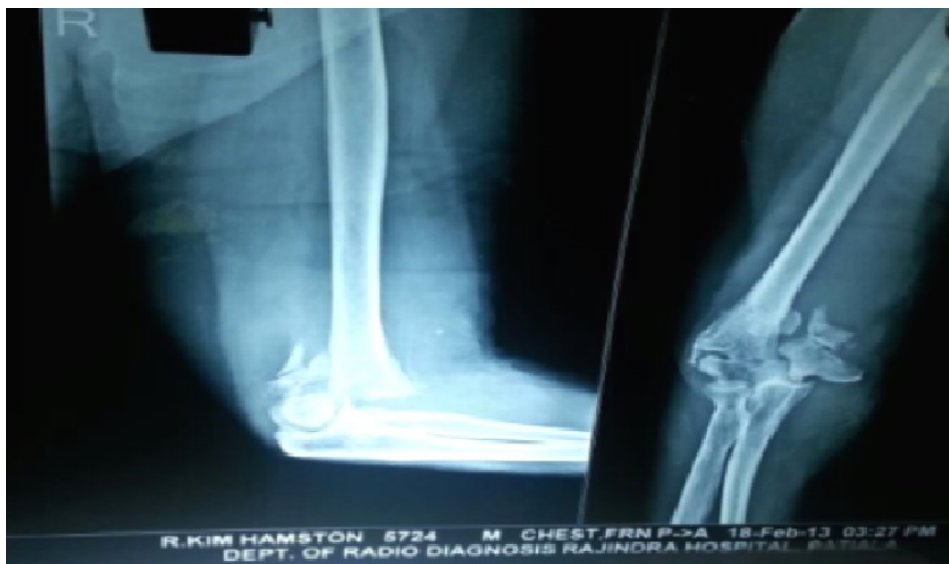

Fig. 22: Case 4 preoperative X ray AP and lateral view

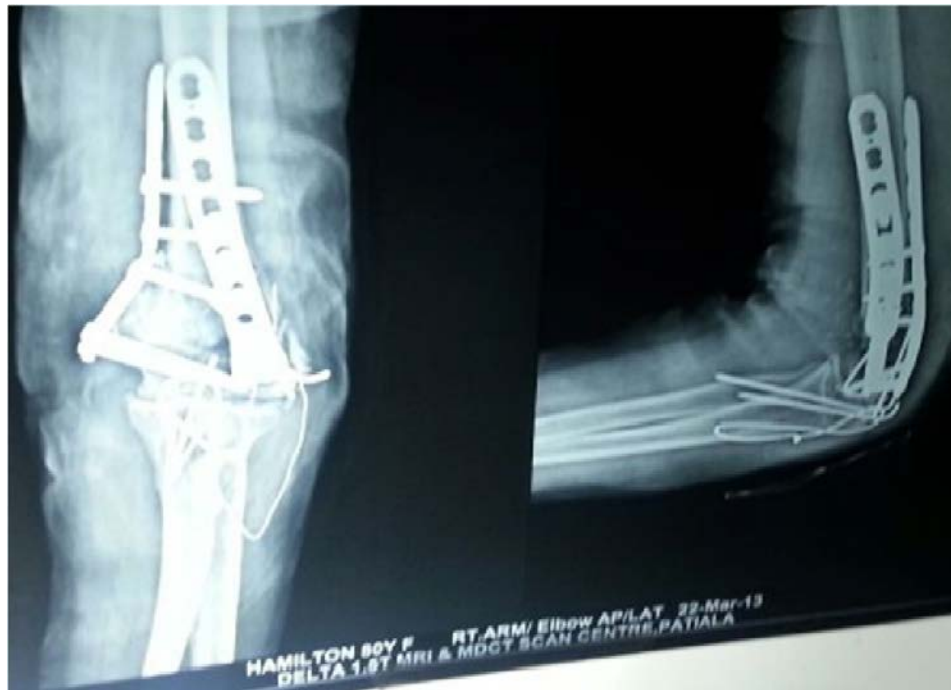

Fig. 23: Case 4 post-operative X ray AP and lateral view

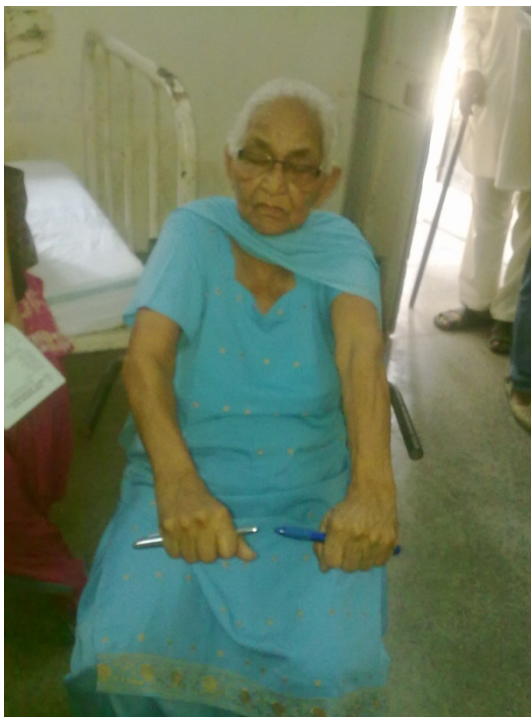

Fig. 24: Case 4 follow up 18 weeks clinical photograph 1

sustaining the fracture. The results were graded according to Mayo Elbow performance score (1993) Dawson *et al.* (1996) and good results was achieved in 13 (52%)



Fig. 25: Case 4 follow up 18 weeks clinical photograph 2

patients and 8 (32%) have excellent outcome. 3 (12%) had fair results and 1 (4%) had poor outcome. The Mean Mayo Elbow performance score (Dawson *et al.*, 1996)

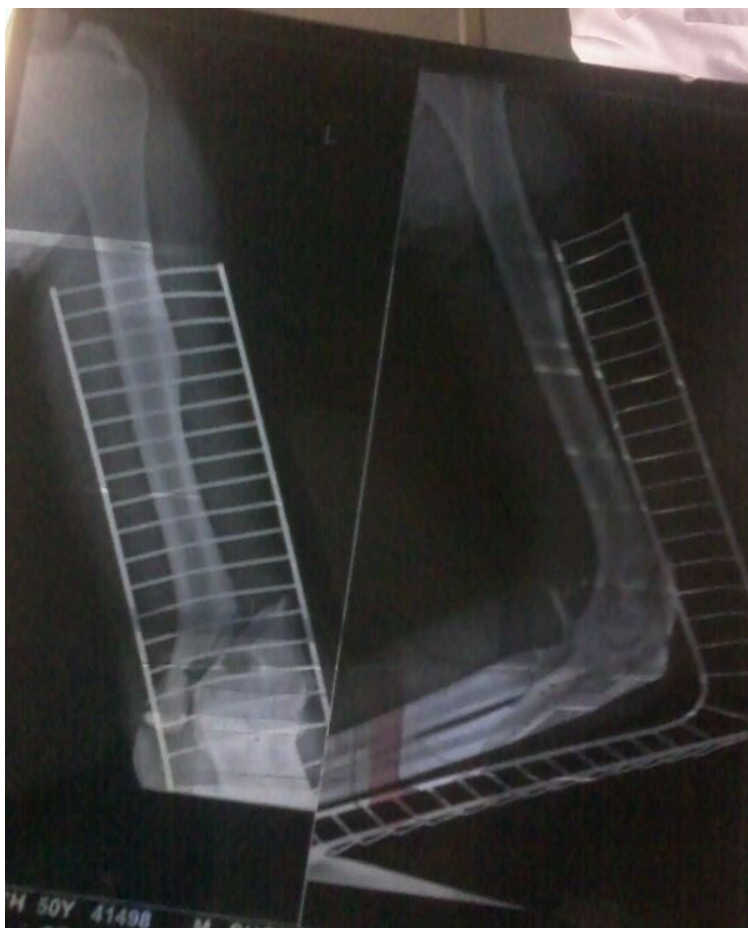

Fig. 26: Case 5 preoperative X ray AP and lateral view

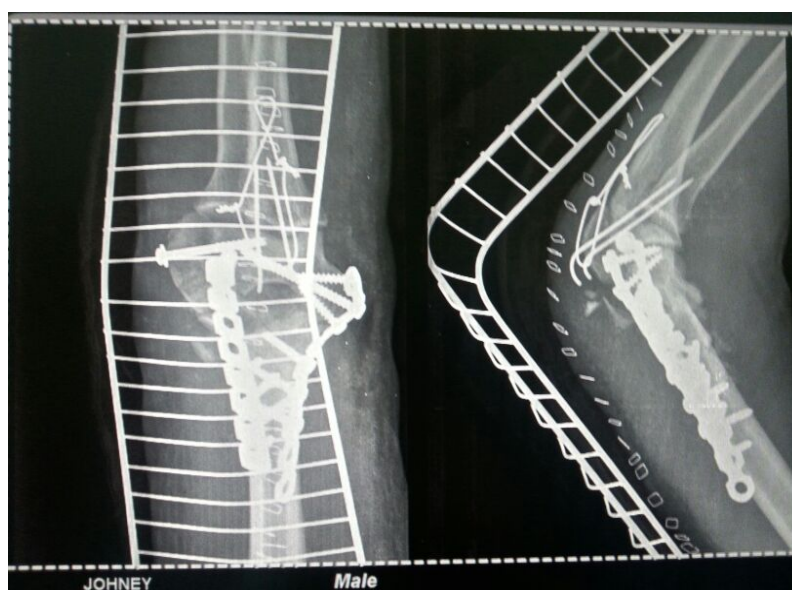

Fig. 27: Case 5 postoperative X ray AP and lateral view





Fig. 28: Case 5 follow up 12 weeks clinical photograph 1

is 83.4. Tian *et al* (2013) in compared the clinical outcomes of the perpendicular and Y-shaped double-plating with olecranon osteotomy methods when applied to type C distal humerus fractures in young adults and found Mayo Elbow performance scores, 84.6% of patients in group I and 83.3% in group II had excellent or good scores. Kilicarslan *et al.* (2011) conducted study on 27 patients and observed the Mayo Elbow performance scores to be excellent results in 20 patients (74%), good in 4 (14.8%), fair in 2 (7.4%) and poor in 1 patient (3.7%). Thus the results of our study were comparable to other studies. General limitations observed in our study were small sample size for comparative study, Limited facilities in govt. setup, inadequate follow-up in some cases and there is limited literature regarding objective extensor mechanism strength assessment in our study.

**Final functional outcome:** Among 25 patients, according to Mayo Elbow performance score (Dawson *et al.*, 1996), Good results was achieved in 52% patients and 8% have excellent outcome and the Mean Mayo Elbow performance score is 83.4 (Table 1, Fig. 29).

**Final functional outcome:** About 84% of the cases had attained good functional arc of motion (Table 2, Fig. 30).

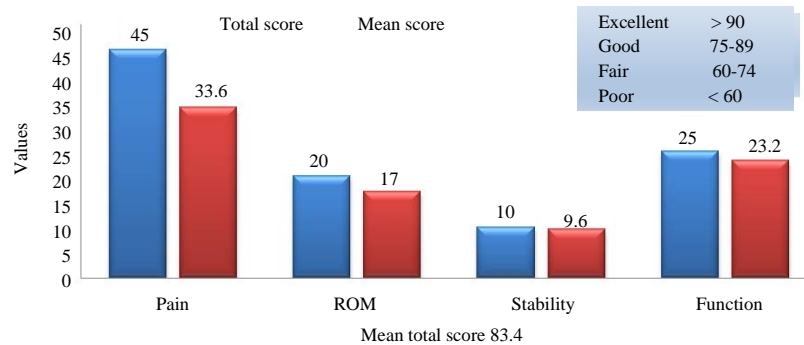


Fig. 29: Final functional outcome

Table 1: Outcomes and the mean Mayo Elbow performance score

Function	No. of patients	Percentage	Mean score (Points)
<b>Pain (Maximum 45 points)</b>			
None (45)	7	28	33.6
Mild (30)	17	68	
Moderate (15)	1	4	
Severe (0)			
<b>ROM (Maximum 20 points)</b>			
>100 (20)	14	56	17
50 TO 100 (15)	9	36	
<50 (5)	2	8	
<b>Stability (Maximum 10 points)</b>			
Stable (10)	23	92	9.6
Moderately (5)	2	8	
Unstable (0)			
<b>Function (Maximum 25 points)</b>			
Comb (5)	20	80	23.2
Feed (5)	25	100	
Personal (5)	25	100	
Shirt (5)	25	100	
Shoes (5)	21	84	
<b>Mean total (max. 100 points)</b>			83.4

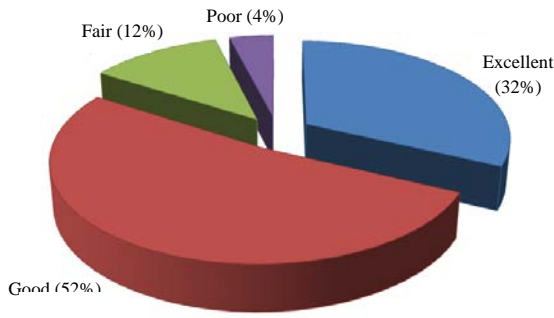


Fig. 30: Results

Table 2: Functional arc of motion

Grading	No. of patients	Percentage
Excellent	8	32
Good	13	52
Fair	3	12
Poor	1	4

### CONCLUSION

From the study, we concluded that, the AO classification is most comprehensive classification for clinico-radiological assessment of fractures of distal humerus as it is very thorough and allows better documentation and specific comparison of fracture types. Supracondylar intra-articular fractures of humerus are more common in males than females due to more outdoor activity in males. The mode of injury for supracondylar intra-articular fractures of humerus is road side accidents mostly which is results of increased vehicular traffic. The most important factor in determining outcome of these fractures is the displacement of the intra articular components. The quality of elbow function after fractures of distal humerus is related to degree to which anatomic relationships are maintained. The reliable method to restore the normal alignment and contours of distal humerus is operative exposure by trans-olecranon approach (with Chevron osteotomy) which gives best view to intra articular distal humeral fractures and direct manipulation of fracture fragments. It is imperative to maintain the width of distal humerus and the two columns with orthogonal plates, so that, the fixation is stable

enough for early post-operative rehabilitation. The method is safe, effective, and economical and the period of hospital stay is short. By this method, we have achieved early mobilisation of the elbow with good range of elbow movement with fewer complications.

### REFERENCES

- Athwal, G.S., 2010. Distal Humerus Fractures. In: Rockwood & Green's Fractures in Adults, Rockwood, C.A., R.W. Bucholz, C.M. Court-Brown, J.D. Heckman and P. Tornetta (Eds.). Lippincott Williams & Wilkins, Philadelphia, Pennsylvania, pp: 945-972.'
- Brown, R.F. and R.G. Morgan, 1971. Intercondylar T-shaped fractures of the humerus: Results in ten cases treated by early mobilisation. J. Bone Joint Surg., 53: 425-428.
- Crenshaw, A.H. and E.A. Perez, 2008. Fractures of the Shoulder, Arm & Forearm. In: Campbell's Operative Orthopaedics, Canale, S.T. and J.H. Beaty (Eds.). Mosby Publisher, Philadelphia, USA., pp: 3371-3459.
- Dawson, J., R. Fitzpatrick, A. Car and D. Murray, 1996. Cambridge shoulder group revised. Br. J. Bone Joint Surg., 78: 185-190.
- Henley, M.B., 1987. Intra-articular distal humeral fractures in adults. Orthopedic Clinics North Am., 18: 11-23.
- Kilicarslan, K., B. Bektaser, A. Ucguder, M. Dogan, M. Ugurlu and H. Yildirim, 2011. Results of early surgical treatment of intra-articular complex fractures of the humerus in adults. Bratisl Lek Listy, 112: 501-505.
- Sodergard, J., J. Sandelin and O. Bostman, 1992. Mechanical failures of internal fixation in T and Y fractures of the distal humerus. J. Trauma, 33: 687-690.
- Tian, D., J. Jing, J. Qian and J. Li, 2013. Comparison of two different double-plate fixation methods with olecranon osteotomy for intercondylar fractures of the distal humeri of young adults. Exp. Ther. Med., 6: 147-151.