

Traumatic Rupture of the Diaphragm

¹Mohamed Elamin Ahmed, ¹Tarig Abbass Elkhidir, ²Mohamed E. Abdulmajeed,

³Greges S.R. Kilda and ¹Khulood A.M. Bukhari

¹Faculty of Medicine, Al Neelain University, Khartoum, Sudan

²Faculty of Medicine, Ribat National University, Khartoum, Sudan

³Faculty of Medicine, University of Medical Sciences and Technology, Khartoum, Sudan

Abstract: Traumatic diaphragmatic rupture is difficult to diagnose in the early stage because symptoms and signs are usually masked by other serious injuries. The aim of this study is to highlight the clinical presentation, diagnostic methods, time to diagnosis, complications and operative approach associated with traumatic rupture of the diaphragm. Six patients were reviewed retrospectively in the period of 2005-2007 in El Shaab Teaching Hospital, Khartoum Sudan. Age, sex, initial clinical presentation, mechanism of injury, time to diagnosis, diagnostic method, side and site of the rupture, associated injuries, complications and morbidity were reviewed. Patients were found to be in the 2nd, 3rd and 6th decade of life. All were male gender and all were involved in Road Traffic Accidents (RTAs). About 5 of them sustained injury to the left side while one sustained the injury on the right side. About 4 patients presented with multiple fractures; 3 patients with shock; 6 patients with chest pain; 2 patients with SOB; 2 patients with abdominal pain and 3 patients with multiple bruises. The diagnosis ranged from the 1st day, 3 days, 2, 3 and 8 months. Variable associated injuries were found. Several complications were present: visceral herniation, gastrothorax and strangulated intestinal obstruction. Surgical option was Laparotomy in 2 patients and thoracotomy in 4 patients.

Key words: Trauma, diaphragm, rupture, road accident, SOB, Sudan

INTRODUCTION

When a trauma patient presents to the emergency room, diagnostic difficulties arise and unpredicted findings may be found later on. There is a general agreement that traumatic rupture of the diaphragm can be difficult to diagnose and is frequently overlooked in cases of blunt trauma.

This injury is often missed at the time of the initial event but may present sometime later. So when dealing with a patient with thoracic and/or abdominal trauma, special attention should be given to diaphragmatic rupture.

The aim of this study is to highlight the mechanism of trauma, initial clinical presentation, time to diagnosis, late presentation and complications that follow traumatic rupture of the diaphragm.

MATERIALS AND METHODS

A retrospective observational study of 6 patients admitted with Traumatic rupture of the diaphragm to Al Shaab Teaching Hospital, Khartoum from 2005-2007.

Charts were reviewed for: age, sex, initial clinical presentation, mechanism of injury, time to diagnosis, diagnostic method, side and site of the rupture, associated injuries, complications and morbidity. All of the 6 patients were clinically examined, radiologically investigated, resuscitated and received initial management at other hospitals.

RESULTS

A total of 6 patients were analyzed. Patients studied were found to be between the 2nd, 3rd and 6th decades of life. All patients were of male gender. All patients sustained injuries in road traffic accidents through blunt trauma to the chest and upper abdomen. The left side of the diaphragm was affected in 5 (83.3%) patients while the right side was ruptured in one patient (15.7%).

Being victims of road traffic accidents, the initial clinical presentation for the patients were: multiple fractures, shock, chest pain, shortness of breath, abdominal pain and multiple trunk and limb bruises (Table 1).

Radiologic evaluation: All patients were investigated radiologically. Initially, a chest radiograph was done. Accurate diagnosis was missed in all patients, they were all misdiagnosed as having hemothorax, pneumothorax or hemo-pneumothorax and were managed accordingly. One of the patients deteriorated rapidly when a chest tube was introduced mistakenly into his stomach because it resembled an air fluid level in the left lower chest (Fig. 1).

In 4 (66.7%) patients in view of the ineffectiveness of the initial management, a CT scan was accordingly opted for confirming the diagnosis. Two patients underwent further investigation using Barium meal which was very useful to diagnose gastric herniation through the left diaphragm to the chest (Fig. 2).

Time to diagnosis: Time to diagnosis ranged from the 1-3 days and 2, 3 and 8 months. The first patient was diagnosed accidentally during laparotomy exploration on the 1st day. The diagnosis was missed by using a chest radiograph. The second patient was misdiagnosed on the 1st day of his presentation.

A chest tube was inserted in the left side of the chest on a background of hemopneumothorax on chest X-ray. Regrettably, the chest tube was inserted into the herniated stomach with leakage of gastric contents in the left hemithorax. Three days after the initial presentation the patient was referred to the hospital after the accurate diagnosis was made.

Table 1: Initial clinical presentation at ER

Initial presentation	No. of patients	Percentage
Shock	3	50.0
Chest pain	6	100.0
SOB	2	33.3
Abdominal pain	2	33.3
Chest/abdominal bruises	3	50.0
Multiple fractures	4	66.7

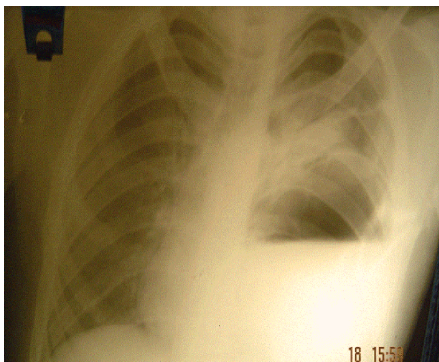


Fig. 1: Chest X-ray showing stomach inside the thorax due to traumatic rupture of the diaphragm

The 3rd patient was inserted a chest tube on the right side on a background of right hemithorax on chest X-ray but his condition deteriorated. A CT scan was requested and the diagnosis of right ruptured hemidiaphragm was established after 2 months of the initial presentation. The 4th and the 5th patients were diagnosed after 3 months of the initial presentation because of a left shadow suggestive of residual haemothorax. The 6th patient presented 8 months after a blunt abdominal trauma with intestinal obstruction. The definitive diagnosis was made intra-operatively as strangulated small bowel herniating through left diaphragm which has been resected.

Associated injuries: These included; large intestinal haematoma, Splenic rupture/Haemoperitonium, Haemothorax, Pneumothorax and Bone fractures.

Complications/morbidity: Complications included Visceral herniation, Gastrothorax and small bowel herniation, Gastrothorax with misplaced chest tube insertion and gastric puncture and adhesive strangulated small intestinal obstruction and bowel resection.

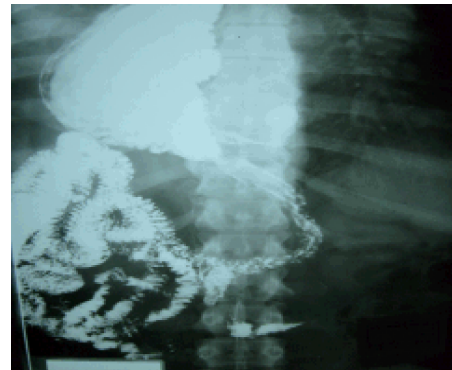


Fig. 2: Barium meal showing stomach in the chest

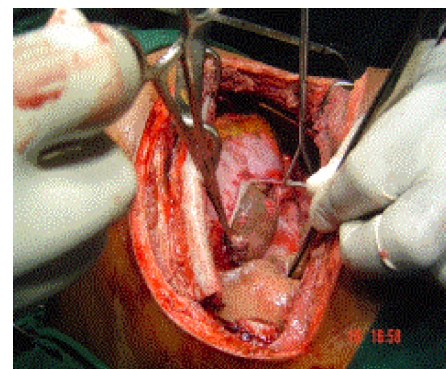


Fig. 3: Left thoracotomy showing a tear in the diaphragm and reduction of the stomach back to the abdomen

Surgery: The diaphragm was repaired through thoracotomy in 4 patients and through lapratomy in 2 patients (Fig. 3).

DISCUSSION

The clinical diagnosis of a ruptured diaphragm is seldom possible and early diagnosis remains a challenge and serious consequences may thus occur (Shah *et al.*, 1995). It could be associated with other life threatening injuries and establishing the exact diagnosis is a dilemma for the trauma surgeon and is often clinically occult (Petrone *et al.*, 2007). Patients reviewed were found to be in the 2nd, 3rd and 6th decade of life and this is similar to results of other studies (Athanassiadi *et al.*, 1999). All patients were of male gender.

The usual mechanism of trauma in a ruptured diaphragm is blunt trauma caused by road traffic accidents (Oonewardene *et al.*, 2007; Shah *et al.*, 1995). This is in contradistinction to the overall diaphragmatic injury where penetrating injuries are found to be more common than blunt injuries (Rubikas, 2001; Hanna *et al.*, 2008).

Falls and other traumatic events are rarely implicated (McCollum *et al.*, 2005). In the study, all 6 patients were engaged in road traffic accidents with blunt trauma involving the thoracic and abdominal regions. They were all brought to the hospital as multiple trauma patients. The initial clinical presentation of patients with a ruptured diaphragm varies depending on the mechanism of trauma and the presence of associated injuries. Symptoms of diaphragmatic injury which themselves, unfortunately are sometimes vague are frequently masked by associated injuries (Steinau *et al.*, 1997).

In the study, different clinical presentations were detected as shown in Table 1. The usual side of diaphragmatic rupture is the left side which constitutes 68.5% of the cases compared to 24.2% on the right side as indicated in the study made by Shah *et al.* (1995). This is owing to the hepatic protection and increased strength of the right hemidiaphragm. Additionally, the right sided rupture is safer because of liver protection (Shah *et al.*, 1995; Lee and Lee, 2007). In the study, 5 (85.3%) of the patients admitted had a left sided diaphragmatic rupture and one patient had a right sided rupture (15.7%). Uniform diagnosis depends on a high index of suspicion but the diagnosis is usually missed clinically at the original time of presentation. From the literature, patients usually present late with visceral herniation, obstruction, incarceration, strangulation, rupture of the stomach or colon and even tension pneumothorax (Obb and Butlin, 1974). In the study, the presence of complications reflects

Table 2: Associated injuries

Injuries	No. of patients	Percentage
Large intestinal haematoma	1	16.7
Splenic rupture/haemoperitonium	1	16.7
Haemothorax	2	15.7
Pneumothorax	3	50.0
Bone fractures	3	50.0

the delay of the diagnosis. One patient was diagnosed accidentally during exploratory laparotomy. Another patient was diagnosed when his condition deteriorated despite insertion of a chest tube in the context of right haemothorax. Two other patients presented with gastric and small intestinal herniation and with gastric injury and strangulated small bowel, respectively. Among diagnostic tools, the chest radiograph as an initial investigation in a trauma patient has a vital role in picking up diaphragmatic injury but the problem is that it is inconclusive (Morgan *et al.*, 1986). About 85% of patients with a ruptured diaphragm have abnormal findings of the chest radiograph but only one third of these show pathognomic tear such as bowel loops or nasogastric tube in the chest (Morgan *et al.*, 1986).

Other features suggestive but not diagnostic of diaphragmatic rupture, include indistinct or elevated hemidiaphragm, hemothorax, pneumothorax, rib fractures or pulmonary contusion (Morgan *et al.*, 1986). These nonspecific findings contribute to the frequent initial misdiagnosis. In the study, the chest radiograph was nonspecific in the majority of cases; the stomach of one of the patient was punctured after being mistaken for a hemopneumothorax. CT scan proves to be a helpful diagnostic tool for diaphragmatic rupture when a delay in diagnosis is experienced and it is specific and sensitive (Larici *et al.*, 2002). An aid with Barium meal is very useful if gastrothorax is to be ruled out (Mueller and Pendarvis, 1994). Two of the patients were investigated using Barium meal which showed the presence of a gastrothorax.

Associated injuries are usually present and they obscure the diagnosis. In the literature, chest and splenic trauma were the most common associated injuries 43.9-37.6%, respectively (Shah *et al.*, 1995). In this study, associated injuries included haemothorax, pneumothorax, ruptured spleen and bone and rib fractures (Table 2).

CONCLUSION

Traumatic rupture of the diaphragm is difficult to diagnose and is usually missed. A high index of suspicion is required to ensure that it is not overlooked to prevent serious future complications. Repair can be approached through the thorax or abdomen according to experience of

the surgeon and the type of associated injuries. A shadow in the left lower chest following a history of blunt trauma should warrant suspicion of diaphragmatic rupture. Barium meal can be very useful to rule out gastrothorax.

REFERENCES

- Athanassiadi, K., G. Kalavrouziotis, M. Athanassiou, P. Vernikos, G. Skrekas, A. Poultisidi and I. Bellenis, 1999. Blunt diaphragmatic rupture. *Eur. J. Cardiothorac. Surg.*, 15: 469-474.
- Hanna, W.C., L.E. Ferri, P. Fata, T. Razek and D.S. Mulder, 2008. The current status of traumatic diaphragmatic injury: Lessons learned from 105 patients over 13 years. *Ann. Thorac. Surg.*, 85: 1044-1048.
- Larici, A.R., M.B. Gotway, H.I. Litt, G.P. Reddy and W.R. Webb *et al.*, 2002. Helical CT with sagittal and coronal reconstructions: Accuracy for detection of diaphragmatic injury. *Am. J. Roentgenol.*, 179: 451-455.
- Lee, W.J. and Y.S. Lee, 2007. Traumatic diaphragmatic rupture: A diagnostic challenge in the emergency department. *Emergency Med. J.*, 24: 601-601.
- McCollum, C., P.C.H. Anyanwu, B.U.O. Umeh and A.S. Swarup, 2005. Management of traumatic rupture of the diaphragm. *Br. J. Surgery*, 72: 181-183.
- Morgan, A.S., L. Flancbaum, T. Esposito and E.F. Coc, 1986. Blunt injury to the diaphragm, analysis of 44 patients. *J. Trauma*, 26: 565-568.
- Mueller, C.F. and R.W. Pendarvis, 1994. Traumatic injury of the diaphragm: Report of seven cases and extensive literature review. *Emergency Radiol.*, 1: 118-132.
- Obb, T.R.L. and G.R. Butlin, 1974. Anaesthesia and traumatic diaphragmatic hernia. *Can. J. Anaesth.*, 21: 173-180.
- Oonewardene, K., A.M. Warwick, P.R. Burton and W.A. Brown, 2007. Outcome of the Traumatic Rupture of the Diaphragm (TRD). *ANZ J. Surgery*, 77: A94-A94.
- Petrone, P., A. Leppaniemi, K. Inaba, K. Soreide and J.A. Asensio, 2007. Diaphragmatic injuries: Challenges in diagnosis and management. *Trauma*, 9: 227-236.
- Rubikas, R., 2001. Diaphragmatic injuries. *Eur. J. Cardiothorac. Surg.*, 20: 53-57.
- Shah, R., S. Sabanathan, A.J. Mearns and A.K. Choudhury, 1995. Traumatic rupture of diaphragm. *Ann. Thorac. Surg.*, 60: 1444-1449.
- Steinau, G., D. Bosman, B. Dreuw and V. Schumpelick, 1997. Diaphragmatic Injuries-Classification, diagnosis and therapy. *Chirurg*, 68: 509-512.