

Tibial Head Fractures-Is There an Advantage in Angular Stable Implants?

¹B. Kienast, ²A. Paech, ³C. Queitsch, ¹U. Schümann, ¹R. Oheim,

^{1,2}Ch. Jürgens and ^{1,2}A.P. Schulz

¹Department for Traumatology, Orthopaedic and Reconstructive Surgery,
BG Trauma Centre Hamburg, Germany

²Department for Traumatology, University of Schleswig, Holstein Campus Luebeck,
Orthopaedic and Reconstructive Surgery

³Regio Kliniken, Krankenhaus Wedel

Abstract: Between January 2003 and January 2005 we treated 26 patients suffering from fractures of the tibial head with an angular stable (or locked) implant. In 15 cases we treated high energy fractures of the Schatzker type V and VI (AO C-type). 11 Patients showed lateral tibial head fractures (AO B-type) with a high degree of osteoporosis. All fractures were treated with a unilateral approach with a lateral locked-plate osteosynthesis. No postoperative wound infection occurred. The average follow-up period was 19.4 months (15-26 months). In 9 cases there was full range of movement (ROM) compared to the not injured side. In 13 cases there was a mild restriction of ROM and in 4 cases restriction of ROM was severe. The Rasmussen Score was good or excellent in 17 cases, the result was fair in 6 and poor in 3 cases. There was no significant loss of reduction caused by implant-failure on follow-up X-rays. For high energy fractures less invasive approach with a high degree of stability of the internal fixation showed a clear advantage concerning postoperative infection rate. In the treatment of osteoporotic bone the use of angular stable implants can prevent implant failure and secondary loss of reduction.

Key words: Tibial head fracture, locked plate osteosynthesis, wound necrosis

INTRODUCTION

Like the treatment of other joint fractures, operative treatment of the tibial head fracture is technically demanding. Tibial head fractures used to be mainly a result of a high-energy trauma, usually sports related in active, young patients or as a result of road traffic accidents. During the last decades tibial head fractures are increasingly observed in geriatric patients (Gerich *et al.*, 2001; Kilian, 2003). Reason is the increasing rate of mobility of the elderly and the change of the age structure of our population. Accident research figured out, that in contrast to younger patients, reason for tibial head fractures of older patients is usually a minor trauma. Goal of the surgical treatment should be the tissue preserving achievement of a stable, functioning and pain free knee as soon as possible. Frequent complications are wound necrosis, osteitis and knee empyema. The infection rate is highly elevated in the treatment of bicondylar tibial head fractures, where double-plate osteosynthesis is required. Beside the necessary vast exposition of the fracture,

reason is the missing stability of the osteosynthesis in particular at the treatment of osteoporotic bone (Burri *et al.*, 1979; Schatzker *et al.*, 1979; Tschernse *et al.*, 1984; Wagner and Jakob, 1986; Betz *et al.*, 1989; Lobenhoffer *et al.*, 1996; Gerich *et al.*, 2001). It should be the goal of every surgical treatment to avoid double-plate osteosynthesis with a medial and lateral skin incision (Jensen *et al.*, 1990; Carr, 1994; Hertel, 1997). Additionally high level of primary stability should avoid secondary dislocation (Rasmussen, 1973; Dustmann *et al.*, 1974). We report results about a unilateral surgical approach for the treatment of tibial head fractures with the use of locked screw-implants.

MATERIALS AND METHODS

Between January 2003 and January 2005 we treated 97 patients suffering from a tibial head fracture. In 26 cases osteosynthesis was performed with the use of an angular stable implant, this group forms the study population. Indication for locked screw plates were

Table 1: Restriction of ROM at Follow up

No. of Patients	ROM at Follow up
9	No Restriction
13	Mild Restriction
4	Severe Restriction

bicondylar fractures treated unilateral to avoid bilateral approach with double-plate osteosynthesis and gap-fractures with severe osteoporosis. Table 1 concerning the classification of the treated tibial head fractures. All 26 patients that we operated using an angular stable implant could be followed-up. Follow-up was performed after an average of 7.5 months after surgery. We treated 16 male and 10 female patients with an average of 52.5 years of age (17-73 years). There were no patients with open fractures or primary nerve injury included in this study. Operative treatment was performed after an average of 1.7 days after trauma. We used an angular stable plate fixator made from pure titanium (TiFix®, Litos, Hamburg/Germany, Fig. 1). The plate is consisting of the softer titanium Grade 1; the screws are made from harder titanium Grade 2. For the preparation we formed soft tissue flaps without separating different layers. If possible we left periosteum and muscle attached to the bone fragments. Marginal fragments, released from the condylar fragments, were partially released from the soft tissues for reposition. Meniscal anterior horns were released in transverse direction in the area of the lig. coronarium and refixed at the end of the procedure. We tried to maintain the meniscus and performed meniscal sutures when it was ruptured and necessary. In doubt meniscus was not resected. In case of joint depression over 10 mm of depth we performed an autologous bone graft harvested from the ipsilateral anterior pelvic spine. We reduced the impression over a bone window with the use of a muller controlled with the image intensifier, sometimes with an Iso C3D (Siemens, Germany) (Fig. 1).

The aim was an overcorrection of about 1 mm. We took care for an accurate reduction of the tibial joint surface. Autologous bone graft was necessary in 9 cases. Depending on the type of fracture we placed the angular stable plate fixator (Fig. 2) medial or lateral (Fig. 3). As a first step of osteosynthesis a conventional, not angular stable screw was placed in the tibial shank. Additional reduction was achieved with the compression of the plate to the tibial head. Finally, we placed an average of 3 locked screws at the tibial metaphysis and in the tibial head. Additional screws from the opposite side were not applied.

In the early phase of rehabilitation we focused on a reduction of swelling by use of cryotherapy, antiphlogistic medication and immobilisation in cast. First

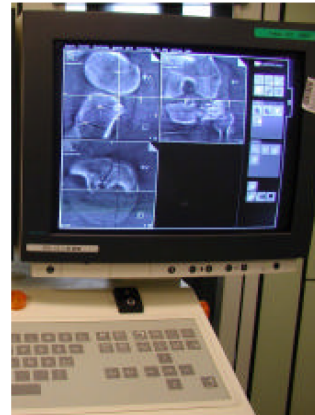
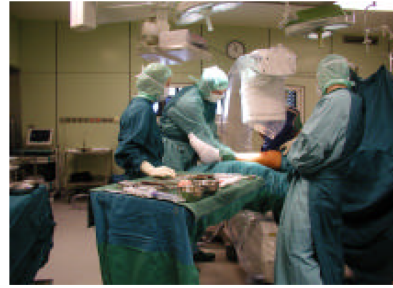
Fig. 1: Control of reposition with intraoperative 3D radiography, here the scan showed a remaining gap and the reduction had to be performed again





Fig. 2 a+b: On the left the multidirectional TiFix internal plate fixator, on the right the locking mechanism in detail

change of dressing was performed after 48 h with removal of the wound drainage. Afterwards we started with continuous passive motion and physiotherapy with limited knee flexion of 60° for one week. Extension of the knee was not restricted. Starting at the 3rd postoperative day the patient was mobilized with crutches. Partial weight bearing with 10 kg was maintained for 12 weeks after surgery, followed by successive increase with intensive outpatient physiotherapy. Removal of metalwork was recommended after 12 months. The average follow-up period was 19.4 months (15-26 months) and included clinical examination, the Rasmussen-Scoring System and Radiographs.

Complications: Deep vein thrombosis with participation of the popliteal vein occurred in 4 cases. Anticoagulation with Marcumar® was necessary for six months in these cases. There was one case of a postoperative peroneal nerve lesion with spontaneous regression after two weeks. No postoperative wound necrosis or infection occurred.

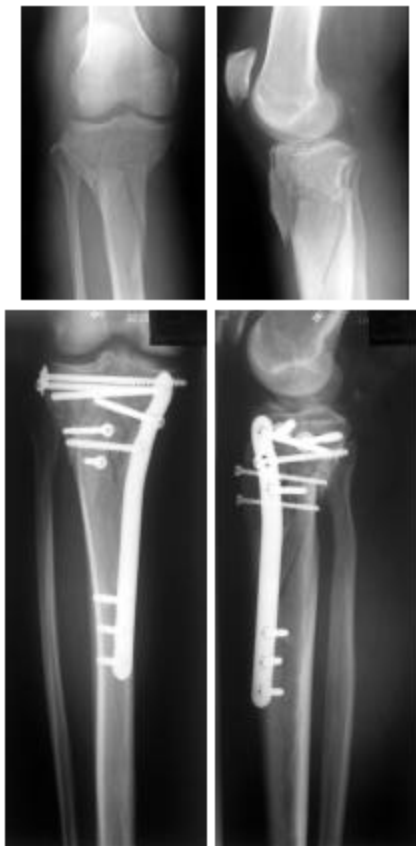

Fig. 3: Bicondylar Type Schatzker 6 Fracture, unilateral plate fixator from lateral

RESULTS

All patients showed bony consolidation after a mean of 8.4 weeks as judged by radiographs. Additional autologous bone transplantation was not necessary. We did not observe any secondary loss of reduction or loosening of the internal plate fixator when comparing direct postoperative radiographs to those at follow up (Fig. 4 and 5). ROM of the knee did not show any restriction compared to the opposite side in 9 patients. Thirteen cases showed mild and 4 cases a remarkable restriction of ROM compared to the not injured side (Table 1). As expected, postoperative restriction of

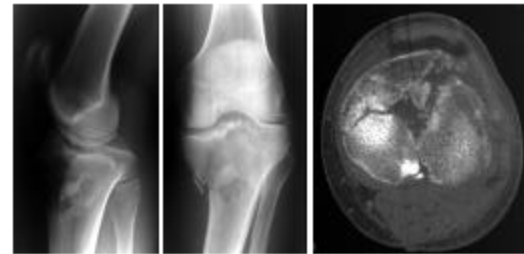


Fig. 4: Schatzker 5 Fracture with mainly medial dislocation

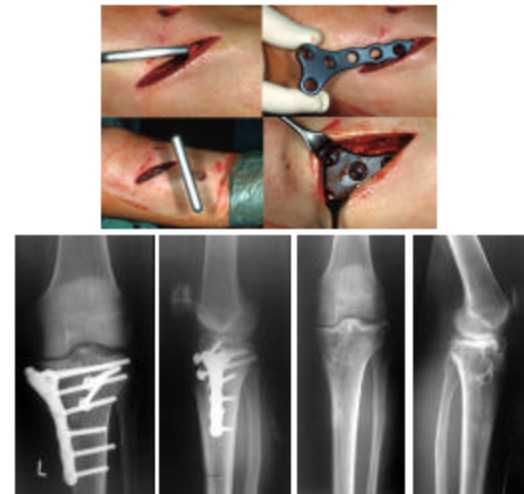


Fig. 5: In minimally invasive fashion the fracture of figure 5 is reduced. The radiographs show a good reduction, after removal of metalworks no loss of reduction

Table 2: Rasmussen Score at Follow up

No. of Patients	Rasmussen Score at Follow up
17	Good or excellent
6	Fair
3	Poor

ROM was higher in the patients with bicondylar fractures (AO C-Fractures) than in the patients suffering from gap-fractures (AO B-Fractures).

Due to the short follow-up period no valid statement concerning the development of posttraumatic arthritis of the knee can be made. Applying the Rasmussen score, 17 cases achieved a good and very good result. Six patients had to be judged as moderate and 3 as poor (Table 2).

DISCUSSION

There are two major problems for the operative treatment of tibial head fractures:

On the one hand there is a highly elevated infection rate for the treatment of bicondylar tibial head fractures, caused by the frequently necessary vast exposition of the fracture and its fragments for the placement of double-plate osteosynthesis. These double-plate osteosynthesis are affiliated with an overall infection rate of up to 50%. Therefore many authors point out that, if possible, only one plate should be used. Separate screws from the opposite side can help to provide sufficient stability. If double-plate osteosynthesis can not be avoided it is strictly recommended to use two separate skin incisions. The Y-shaped approach is not used and recommended anymore, due to the high rate of skin necrosis (Tscherne *et al.*, 1984; Wagner and Jakob, 1986; Carr, 1994; Trouillier *et al.*, 1995; Lobenhoffer *et al.*, 1996; Hutson and Zych, 1998; Wolter, 1999). On the other hand, during the last decades, older patients suffer from tibial head fractures due to a change of the age structure and activity level in our population. In contrast to younger patients the reason for tibial head fractures of older patients is usually a minor trauma, which leads to plateau-fractures of the tibial head. Reason is the usually pre-existing osteoporosis (Gaudinez *et al.*, 1996; Gerich *et al.*, 2001; Kilian, 2003). Although not or only minimal displaced tibial head fractures can be treated conservatively, usually operative treatment is necessary, even for geriatric patients, if no general or local contraindications exist (Watson, 1994; Trouillier *et al.*, 1995; Hertel, 1997). Main problem for the treatment of geriatric patients is the severe general demineralization of the bone-structure. This can make osteosynthesis with standard plate fixators difficult or impossible. Hence, Kilian (2003) recommends the primary implantation of a cemented total knee replacement for tibial head fractures with advanced osteoporosis in special cases. In case of an implant failure or secondary loss of reduction in older or geriatric patients, a highly increased morbidity has to

be expected due to the additional operations and the longer time of immobilisation (Gerich *et al.*, 2001; Kilian, 2003; Schulz *et al.*, 2007).

Our own collective consisted of 15 patients with a bicondylar tibial head fracture and 11 patients with a gap-fracture with advanced osteoporosis. For the 15 patients suffering from a bicondylar fracture we used a unilateral osteosynthesis with a locked screw plate. All these cases would have required a bilateral conventional double-plate osteosynthesis or separate screw fixation from the opposite side, if treated without locked screws. No superficial or deep wound infection and no secondary loss of reduction, especially of the contralateral tibial head, occurred. Wolter (1999) and Seide (1999) reported in detail about the advantages of angular stability. In not angular stable connections the stabilisation depends on the pressure of the plate against the bone by screws. In case of a locked plate-to-screw connection, the connection is built in the sense of a side clamped bar, which transfers the load from the bone to the plate. Applying pressure on the plate to the bone is not necessary and the blood circulation of the bone surface is less impaired. Our results show, that a unilateral plate fixation of the bicondylar tibial fracture is sufficient. With the use of locked-screw plates also the contralateral tibial head fragment can be held in position. We did not observe severe complications like deep wound necrosis or osteitis, which are well known after bilateral incisions. Rasmussen-score of our group showed a result comparable to the results of other authors treating bicondylar tibial head fractures.

Angular stability provides advantages especially for the treatment of patients with osteoporotic bone (Seide, 1999; Wolter, 1999). Presuming a population equal in size, a change of the age structure can be expected during the next decades. The group of patients over 60 years of age will grow over proportional-that will lead to an increase of geriatric trauma surgery.

Main problem for the treatment of tibial head impression-fractures or gap-fractures, where the reason is usually a minor trauma, is not infection but secondary loss of reduction due to the missing stability of conventional implants in osteoporotic bone (Dustmann *et al.*, 1974; Schatzker *et al.*, 1979; Jensen *et al.*, 1990; Mallik *et al.*, 1992; Gerich *et al.*, 2001; Kilian, 2003; Piper *et al.*, 2005). The 11 patients with osteoporotic bone suffering from tibial head gap-fractures, which we treated with angular stable implants, showed no loosening or failure of the osteosynthesis. Although the number of patients in our collective is small, the advantages of angular stability in the treatment of fractures in osteoporotic bone are well known from other

locations of the body. The observed complications-4 deep vein thrombosis and one temporary lesion of the peroneal nerve-did not depend on the used implant. These complications are caused by the injury or surgeon and can be compared to the results of other authors (Rasmussen, 1973; Rasmussen and Sorensen, 1973; Betz *et al.*, 1989; Lobenhoffer *et al.*, 1996; Hertel, 1997). Unilateral plate fixation for the treatment of bicondylar tibial head fractures, as well as the treatment of osteoporotic gap-fractures with angular stable implants, seems to offer advantages in particular concerning infection rate and implant failure in the treatment of tibial head fractures.

REFERENCES

- Betz, A. and E. Seibisch *et al.*, 1989. Tibial head fractures. *Chirurg*, 60 (11): 732-738.
- Burri, C. and G. Bartzke *et al.*, 1979. Fractures of the tibial plateau. *Clin. Orthop. Relat. Res.*, 138: 84-93.
- Carr, J.B., 1994. Surgical techniques useful in the treatment of complex periarticular fractures of the lower extremity. *Orthop. Clin. North Am.*, 25 (4): 613-624.
- Dustmann, H.O. and K.P. Schulitz *et al.*, 1974. Proceedings: Tibial head fractures as pre-arthritis. *Z. Orthop. Ihre. Grenzgeb.*, 112 (4): 637-640.
- Gaudinez, R.F. and A.R. Mallik *et al.*, 1996. Hybrid external fixation of comminuted tibial plateau fractures. *Clin. Orthop. Relat. Res.*, 328: 203-210.
- Gerich, T. and M. Blauth *et al.*, 2001. Osteosynthesis of fractures of the head of the tibia in advanced age. A matched-pair analysis. *Unfallchirurg*, 104 (1): 50-56.
- Hertel, P., 1997. Tibial plateau fractures. *Unfallchirurg*, 100 (7): 508-23.
- Hutson, J.J. and G.A. Zych, 1998. Infections in periarticular fractures of the lower extremity treated with tensioned wire hybrid fixators. *J. Orthop. Trauma*, 12 (3): 214-218.
- Jensen, D.B. and C. Rude *et al.*, 1990. Tibial plateau fractures. A comparison of conservative and surgical treatment. *J. Bone Joint Surg Br*, 72 (1): 49-52.
- Kilian, U., 2003. Total knee replacement for primary treatment of intra-articular tibial head fractures in elderly patients. *Unfallchirurg*, 106 (12): 1046-1050.
- Lobenhoffer, P. and M. Schulze *et al.*, 1996. Minimally invasive osteosynthesis of fractures of the tibial head. *Unfallchirurg*, 99 (8): 569-575.
- Mallik, A.R., D.J. Covall *et al.*, 1992. Internal versus external fixation of bicondylar tibial plateau fractures. *Orthop. Rev.*, 21 (12): 1433-1436.
- Piper, K.J. and H.Y. Won *et al.*, 2005. Hybrid external fixation in complex tibial plateau and plafond fractures: An Australian audit of outcomes. *Injury*, 36 (1): 178-184.
- Rasmussen, P.S., 1973. Tibial condylar fractures. Impairment of knee joint stability as an indication for surgical treatment. *J. Bone Joint Surg. Am.*, 55 (7): 1331-1350.
- Rasmussen, P.S., 1973. Gonarthrosis following fractures of the tibia head. *Z. Orthop. Ihre. Grenzgeb.*, 111 (4): 509-12.
- Rasmussen, P.S. and S.E. Sorensen, 1973. Tibial condylar fractures: non-operative treatment of lateral compression fractures without impairment of knee-joint stability. *Injury*, 4 (3): 265-271.
- Schatzker, J. and R. McBroom *et al.*, 1979. The tibial plateau fracture. The Toronto experience 1968-1975. *Clin. Orthop. Relat. Res.*, 138: 94-104.
- Schulz, A.P. and U. Gerlach *et al.*, 2007. Osteitis and septic Arthritis after Tibial Head Fracture-Results of a Radical Treatment Regime. *European Journal of Trauma Online first*.
- Seide, K., M.M. Morlock, U. Schuermann and D. Wolter, 1999. Mechanical effects of the locked screw plate interface in internal fixator osteosynthesis. *Trauma Berufskrankh*, 1: 320-325.
- Trouillier, H. and M. Krüger-Franke *et al.*, 1995. The operative treatment of the tibial plateau fracture. *Aktuel Traumatol.*, 25: 148-152.
- Tscherne, H. and P. Lobenhoffer *et al.*, 1984. Proximal intra-articular tibial fractures. *Unfallheilkunde*, 87 (7): 277-289.
- Wagner, H.E. and R.P. Jakob, 1986. Plate osteosynthesis in bicondylar fractures of the tibial head. *Unfallchirurg*, 89 (7): 304-311.
- Watson, J.T., 1994. High-energy fractures of the tibial plateau. *Orthop. Clin. North Am.*, 25 (4): 723-752.
- Wolter, D., U. Schuermann and K. Seide, 1999. The universal titanium internal fixator. Development, mechanics, implant design and surgical application. *Trauma Berufskrankh*, 1: 307-319.