

Endoprosthetic Treatment of a Fractured Femoral Neckt by the Means of an Less Invasive Surgical Anterior Approach (LISA)

¹A. Paech, ¹F. Renken, ¹M. Brahm, ^{1,3}A.P. Schulz, ²M. Willkomm, ¹S. Hillbricht and ¹Ch. Jürgens

¹Department of Traumatology, University Hospital Schleswig Holstein, Campus Lübeck, Ratzeburger Allee 160, D-23538 Lübeck, Germany

²Department of Geriatric Medicine, German Red Cross Hospital Marli, Lübeck, Germany

³Department of Trauma and Orthopaedics, BG Trauma Hospital Hamburg, Hamburg, Germany

Abstract: Minimally invasive Total Hip Arthroplasty (THA) aims at reduction of tissue damage to accelerate recovery. Less or minimally invasive approaches are more and more used in elective total hip arthroplasty. The anterior approach hereby promises optimal soft tissue preservation and a good cosmetic result. The anterior minimal-invasive approach used in his study consists of a modified Smith-Petersen-Approach. In order to reduce the morbidity rate, a standardized use of minimally invasive surgical approach has been evaluated in endoprosthetic surgery of geriatric patients. The rationale for a less invasive approach in the elderly hereby is to accelerate rehabilitation and minimize co-morbidity, a cosmetic issue is of much lesser relevance in this patient population. Aim of this study is to present first clinical results of minimal-invasive approach to the hip joint (modified Smith-Petersen-Approach) as a standard in geriatric hip fracture endoprosthesis under the aspect of morbidity and rehabilitation result. The patient collective emanated consecutively from the first 12 months after introduction of the new approach. From January 2006 until December 2006 we treated 23 patients with a fractured neck of femur. The median of age in our collective was 77 years (mean 79 years, 63-92 years). We implanted both hemi- as well as total hip endoprosthesis in geriatric patients with medial femoral neck fractures type Garden 1-4 using an anterior LISA approach, 23 endoprostheses were implanted (17 total endoprostheses and 6 bipolar prostheses). The anterior LISA approach was used in all patients; there were no cases in which we had to switch to the conventional approach. We saw three complications in our follow up (13%). The Barthel index showed an improvement from 56-75 points, there was no statistical difference in improvement in patients with bipolar compared to full endoprosthesis ($p > 0,05$). At the time of follow up 20 patients (83%) had returned into their previous social status, 3 patients had to move from sheltered housing into a nursing home. The minimally invasive endoprosthesis of fractures using an anterior approach seems to be a safe method which allows the correct implantation of acetabular and femoral shaft components as well as implantation of bipolar endoprostheses.

Key words: Endoprosthetic treatment, fractured femoral, LISA, THA, optimal soft tissue

INTRODUCTION

Dislocated medial femoral neck fractures type Garden 3 and 4 ought to be taken care of in a definite considerable way, especially in elderly patients with several concomitant disorders, which allows a prompt postoperative mobilization under full stress. Important factors in the treatment of these fractures with an endoprosthetic device are frequently distinctive osteoporosis and an already present degenerative arthritis of the hip joint. The described method allows a mobilization under full stress and avoids unnecessary

additional strain caused by revision surgery after internal fixation. Designated factors are especially the “cut out” difficulties after internal fixation of medial femoral neck fractures with e.g. sliding hip screw or redislocation after cannulated screw osteosynthesis. Both surgical malpositioning of the implants and particularly the osteoporotic bone structure in elderly patients with associated limited stress capacity of the implants are a causative. Furthermore, a postoperative partial weight bearing is usually not realizable due to general morbidity and low compliance. The risk of femoral head necrosis at about 20% in fractures type Garden 1 and 2 is reason

enough in the elderly patient population to strive for a definite surgical treatment. By this approach, morbidity and mortality as well as the need for a further procedure are less likely. In order to lower general morbidity the use of a minimally invasive surgical approach in fracture endoprosthesis in the elderly patient seems necessary.

Aim of this study is to present our first experiences using the LISA approach in standard treatment of geriatric endoprostheses for fractures of the femoral neck.

MATERIALS AND METHODS

The patient collective emanated consecutively from the first 12 months after introduction of the new approach. Study center was the Department of orthopaedic trauma surgery of a University Hospital for the index procedure and the department of geriatric rehabilitation of a Hospital for non-acute medicine. From January 2006 until December 2006 we treated 23 patients with a fractured neck of femur. The median of age in our collective was 77 years (mean 79 years, 63-92 years). Seventeen patients (74%) were female. Significant co-morbidities were documented in the medical notes in 19 patients.

In 12 patients significant degenerative changes of the hip joint were found on a.p. and lateral radiographs.

Using the Garden (1961) and the Pauwels (1935) classifications as references the majority of the fractures were dislocated with fracture line angle of more than 70°, respectively. The details of the Garden's (1961) classification shown in Fig. 1.

Included in the study were all patients with a fractured neck of femur with an indication for either Total Hip Arthroplasty (THA) or bipolar hemi-endoprosthesis.

Exclusion criteria for this study were patients with ASA grade IV, revision surgery, infectious conditions of the groin and patients not able to give informed consent to the study.

We implanted both hemi- as well as total hip endoprosthesis (cemented or hybrid) in geriatric patients with medial femoral neck fractures type Garden 1-4 using an anterior LISA approach (modified Smith-Petersen approach) (Berger, 2004; Rachbauer *et al.*, 2004) 23 endoprostheses were implanted of which 17 were total endoprostheses and 6 were bipolar prostheses.

Implants used were the anatomical ABGII stem (Howmedica/Stryker), cemented or cementless, a standard bipolar endoprosthetic system (Stryker) and the acetabular shell component 32 PE shell 0° (Stryker). With cemented femoral stems the PMMA Palacos© processing was accomplished in vacuum technique.

The anterior minimal-invasive approach; modified smith-petersen-approach: The incision starts two transverse

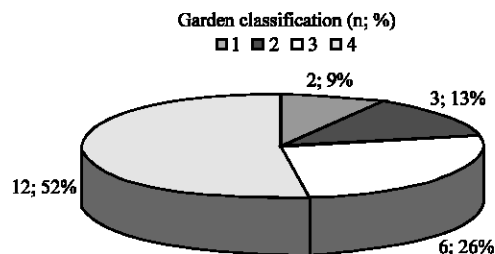


Fig. 1: Garden classification in the current study, numbers and percentage are given

fingers below and laterally of the spina iliaca anterior superior and follows the antero-medial portion of the muscle belly of the M. tensor fascia lata. The incision length of initially 8cm may be extended if required.

In the following after longitudinal incision of the muscle fascia one is able to prepare digitally forward through to the front part of the joint capsule (Gottschalk *et al.*, 1989)

The transition from the femoral neck to Trochanter major is exposed carefully, since from here the femoral neck osteotomy is accomplished in typical 45° position as a double osteotomy.

The reaming of the Acetabulum is performed with a purpose built offset handle which is used under protection of Homann retractors. For the implantation of the hip socket an offset handle is used (Rachbauer, 2004).

The approach allows both an unproblematic cementless, as well as a cemented acetabular component implantation. If a bipolar hip endoprosthesis is to be implanted, a sparing resection of the left capsule and bone may be carried out. Subsequently the femoral shaft is prepared. Therefore, the femur is externally rotated and adducted to a maximum extend and the operation table may be tilted by 20°.

After adduction of the leg the femoral medullary cavity is reamed for the insertion of a stem prosthesis by special offset raffle reamers. After implantation of the stem a test reposition with comparison of the leg length is performed. When using a bipolar hip endoprosthesis the head is placed into the acetabulum before reposition and is coupled with a corresponding metal head in situ. Wound closure is performed in layers after the definite reposition and adequate lavage, coagulation and drainage insertion.

Follow up took place approximately 12 weeks (10-14 weeks) after the index procedure, all patients were available for follow up. Included in follow up were a clinical examination, radiographs a.p. and axial,

determination of the social status and the Barthel index (Mahoney and Barthel, 1965) as well as the timed “up + go test” (Podsiadlo and Richardson, 1991).

Anterior-posterior radiographs were taken from each patient the second and the tenth day after surgery.

For evaluation of the data we calculated the median, standard deviation and the mean value.

RESULTS

The anterior LISA approach was used in all patients in the endoprosthetic treatment of femoral neck fractures; there were no cases in which we had to switch to the conventional approach. The majority of the total hip endoprostheses was implanted in hybrid technique with cementless acetabular shell and cemented femoral stem (Fig. 2). The median of surgery duration differed from 97-75 min for total hip versus bipolar endoprosthesis.

We saw three complications in our follow up (13%). One patient with a superficial soft tissue infection was successfully treated by wound revision. Secondary bleeding after drainage removal lead to a haematoma in two cases, which both had to be revised. After revision we saw an uncomplicated course. There were neither postoperative hip dislocations nor neurological disorders; especially did we not see any irritation of the lateral cutaneous femoral nerve. There was no case of deep vein thrombosis or pulmonary embolism in this study. As general complications we saw one case of acute on chronic congestive cardiac failure and one transient ischaemic cerebral attack.

There was a significant postoperative reduction of pain and an improved mobilisation status in our geriatric patients treated with the LISA approach (Fig. 3a and b).

Before dismissal from acute treatment and also at follow up after completion of a geriatric rehabilitation we scored “the time up and go” test and also evaluated the Barthel index (Fig. 3). The results of both of the tests showed an efficient gain of mobility and autonomy in

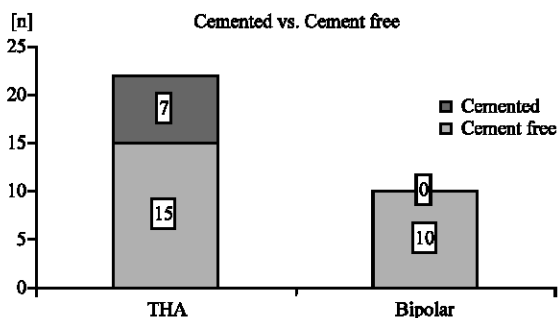


Fig. 2: Distribution of THA vs. bipolar arthroplasty, cemented and hybrid)

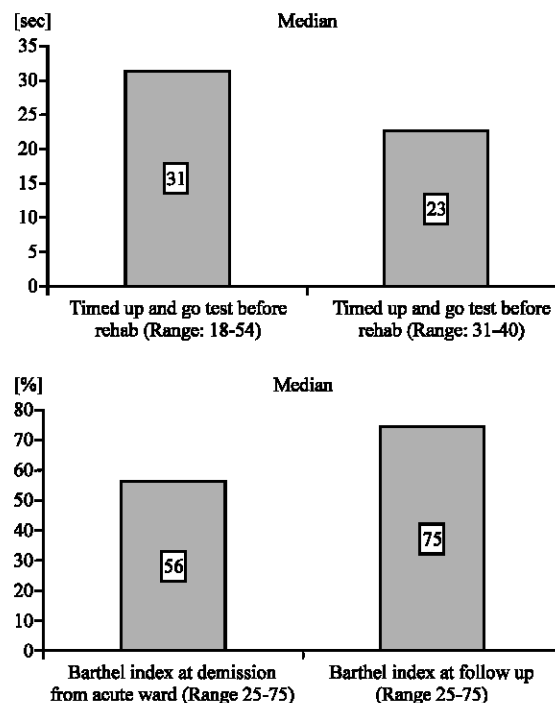


Fig. 3a b: Timed “up and go” test and Barthel index before and after geriatric rehabilitation.

every day tasks. The Barthel index showed an improvement from 56-75 points, there was no statistical difference in improvement in patients with bipolar compared to full endoprostheses ($p > 0.05$). At the time of follow up 20 patients (83%) had returned into their previous social status, 3 patients had to move from sheltered housing into a nursing home.

The median time before discharge to the rehab unit was 12.3 days, the mean rehabilitation period lasted 19.7 days.

DISCUSSION

The results of our first experiences with fracture endoprosthesis as total or hemiarthroplasty showed the possibility to expose the femur sufficiently even with a smaller ventral incision in order to securely implant an endoprosthesis. A carefully prepared joint capsule allows a sufficient retraction of the femur. An essential precondition is the use of specific instruments like Homan retractors, offset raffles and offset-handles. The exposure of acetabulum and medullary cavity is excellent (Light and Keggi, 1980; Rachbauer, 2005). Nevertheless this procedure has a significant learning curve that should not be underestimated. The procedure duration was still clearly above the reported cut to stitch times for conventional THA or even bipolar endoprostheses in the

initial period. Surgery time seems not to be different to conventional approach after a period of training. We are now regularly ligating the anterior vessels instead of coagulation as used in this study as a reaction on to hematoma that postoperatively developed. Infections of the groin are a contraindication to this procedure, in other respects the ventral approach zone is of hygienically advantage in the often urinary and faecal incontinent elderly patient.

Cemented as well as cementless fracture prosthetics can be implanted with ease after the described learning curve using the anterior LISA approach. The positioning of the acetabular shell relatively easy compared to the conventional way due to the good exposure of this area. Our geriatric patients reported comparatively little pain after surgery and could therefore be mobilized early.

We could show that with this technique an outcome can be achieved that is at least comparable to the conventional technique. The mortality is relatively low compared to the literature.

We have now started a prospective randomized controlled trial comparing the standard technique (Watson-Jones approach) with the less invasive approach. Parameters included are the items of this study and furthermore the amount of blood loss, the WOMAC score and incision length.

CONCLUSION

The minimally invasive endoprosthesis of fractures using an anterior approach seems to be a safe method which allows the correct implantation of acetabular and femoral shaft components as well as implantation of bipolar endoprotheses. There are shorter incisions with correspondingly minor trauma of soft tissue. Especially in elderly patients with concomitant disorders these aspects are of very high importance. The reduction of postoperative pain seems to be significant and enables the patient to be mobilized earlier.

REFERENCES

- Berger, R., 2004. Direct anterior approach In: Hozak, W.J., M. Krismer and M. Nogler *et al.* (Hrsg) Minimally invase total joint arthroplasty. Springer, Berlin Heidelberg New York, pp: 108-112.
- Garden, R.S., 1961. Low-angle fixation in fractures of the femoral neck. *J. Bone Joint Surg.*, 43: 647-63.
- Gottschalkm, F. S. Kourosh and B. Leveau, 1989. The functional anatomy of tensor fasciae latae and gluteus medius and minimus. *J. Anat.*, 166: 179-189.
- Lanz, J. and W. Wachsmuth, 1972. Bein und Statik, 2. Aufl. Springer, Berlin Heidelberg New York.
- Light, T.R. and K.J. Keggi, 1980. Anterior approach to hip arthroplasty. *Clin Orthop.*, 152: 255-260.
- Mahoney, F.I. and D. Barthel, 1965. Functional evaluation: The Barthel Index. *Maryland State Med. J.*, 14: 56-61.
- Pauwels, F., 1935. Der Schenkelhalsbruch ein mechanisches Problem: Grundlagen des Heilungsvorganges Prognose und kausale Therapie. Stuttgart: Ferdinand Enke Verlag.
- Podsiadlo, D. and S. Richardson, 1991. The Timed "Up and Go": A test of basic functional mobility for frail elderly persons. *J. Am. Geriatr. Soc.*, 39:142-148.
- Rachbauer, F., 2005. Minimal-invasive Hüftendoprothetik über einen direkten vorderen Zugang. *Der Orthopäde*, pp: 34.
- Rachbauer, F. and M. Nogler, 2004. Direct Anterior Approach. In: Hozak W.J., M. Krismer, M. Nogler *et al.* (Eds.) Minimally invase total joint arthroplasty. Springer, Berlin Heidelberg New York, pp: 29-32
- Rachbauer, F., M. Nogler, E. Mayr and M. Krismer, 2004. Minimally Invasive Single-Incision Anterior Approach for Total Hip Arthroplasty. In: Hozak, W.J., M. Krismer and M. Nogler *et al.* (Eds.) Minimally invase total joint arthroplasty. Springer, Berlin Heidelberg New York, pp: 54-59
- Wagner, H., 1978. Surface replacement arthroplasty of the hip. *Clin. Orthop.*, 134: 102-130.