

Diagnosis and Surgical Treatment of Diaphragmatic Rupture Following Blunt Abdominal Traumas

¹Ahmet Karamercan, ¹Osman Kurukahvecioglu, ²Yildirim Imren,

¹Tonguc Utku Yilmaz, ¹Mustafa Sare and ¹Bulent Aytac

¹Department of General Surgery, ²Department of Cardiovascular,
Faculty of Medical, Gazi University, Turkey

Abstract: Diaphragmatic rupture observed in trauma patients with multiple organ injuries is a rare but serious problem. The incidence rate for diaphragmatic rupture is 0.8-5% while mortality rate is between 16.6-33.3%. There are cases in the literature which diaphragmatic rupture was diagnosed years after the trauma. Symptoms related to heart or lung compression due to early or delayed displacement of the abdominal viscera into the thorax or strangulation of abdominal viscera lead the physician to diagnosis. A 75-year old female patient who presented to the emergency room with shortness of breath, abdominal pain, nausea and vomiting complaints had been in a traffic accident 20 days earlier and admitted to the hospital. Abdominal ultrasound, plain radiographs and laboratory tests after the accident had been normal and the patient was discharged after a 24 h follow-up. Patient had signs of intestinal obstruction and abnormal blood gas values and posterior-anterior chest radiograph revealed elevation of the left hemidiaphragm. Thoracic computerized tomography demonstrated elevation of the posterolateral region of the left hemidiaphragm and displacement of the subdiaphragmatic organs within the thorax, up to the level of the carina. The patient had laparotomy under emergency conditions when rupture of the diaphragm was identified and repaired transabdominally. Diaphragmatic ruptures secondary to blunt traumas can be diagnosed with its early or late symptoms. Non-specific symptoms like chest pain, dyspnea, tachypnea, shortness of breath observed in patients should raise suspicion. Early or late deterioration in blood gas analyses following blunt traumas should be assessed carefully. Diagnosis can be rapidly established with direct radiographs, thoracic computerized tomography and magnetic resonance imaging. Treatment of rupture is surgery. Generally the diaphragm is repaired by the transabdominal approach while complicated ruptures can be assessed with a lower thoracic incision. Being extra vigilant following serious blunt traumas is an important factor in establishing the diagnosis.

Key words: Traumatic diaphragmatic rupture, abdominal traumas

INTRODUCTION

Diaphragmatic rupture is a rare condition encountered in trauma patients with multiple organ injuries, often coupled with serious thoracic and abdominal traumas. It is not always diagnosed, which makes it particularly important problem. Its incidence is 1-7 and 10-15% after blunt and penetrating traumas, respectively, with an overall mortality rate of 27-40%^[1-4]. Diaphragmatic injuries occur in 0.8-5% of road motor accidents and it is missed in 12-66% of patients followed-up conservatively. Though early diagnosis is critical to enable easy repair before fibrosis develops, it is not always possible even with advanced imaging techniques. Mortality and morbidity increases in delayed cases due to strangulation, herniation and

pulmonary complications. There are cases with high mortality in the literature diagnosed several years later. Physician's suspicion, findings due to strangulation of abdominal viscera, heart and lung compression and the gradual shift of the abdominal viscera into the thorax in repeated radiological examinations lead to early diagnosis^[5]. This paper discusses diagnostic and therapeutic methods in the context of a delayed case of diaphragmatic rupture. Case presentation: A 75-year old female patient presented to the emergency room with dyspnea, abdominal pain, nausea and vomiting. History revealed that the patient had been admitted to the hospital 20 days earlier for being involved in a traffic accident. Emergency ultrasound and plain radiographs after this incident were unremarkable. Her laboratory results were normal and after a 24-h follow-up she had

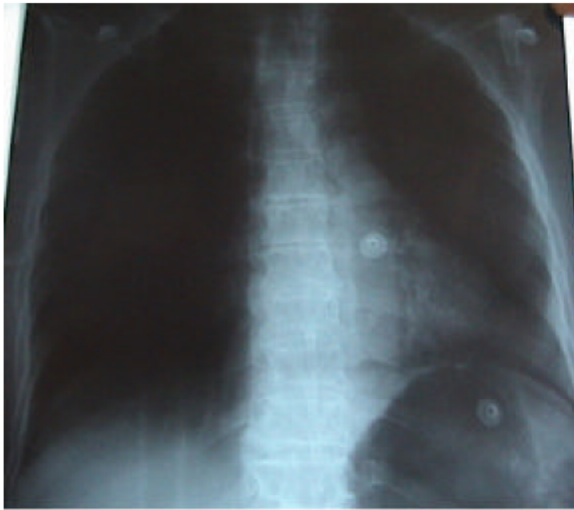

Fig. 1: Chest Radiograph

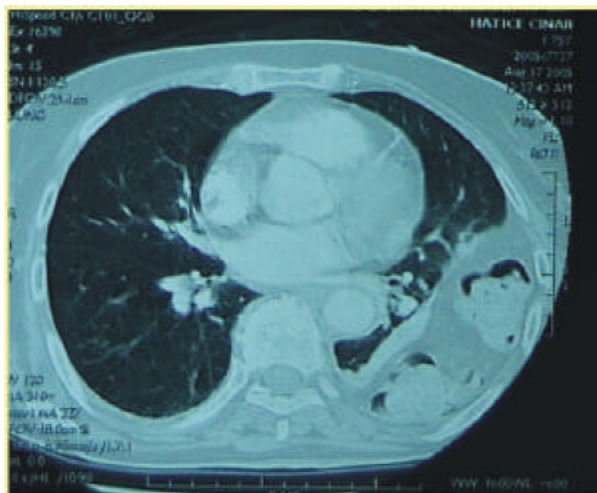


Fig. 2: Lef Posterolateral Zone

been discharged. Patient was well until about a week earlier when the complaints started. At the second admission, the patient had the signs and symptoms of an intestinal obstruction. The patient had not defecation and due to vomiting her oral intake was disrupted as well. Patient's pre-existing asthma was exacerbated and breath sounds were diminished on the left posterolateral zone. Abnormal blood gas analyses and elevated left hemidiaphragm on a Posterior-Anterior (PA) chest radiograph (Fig. 1) prompted thoracic computarized tomography (CT) to be performed, which revealed elevation of the left hemidiaphragm, more prominent on the left posterolateral zone, presence of subdiaphragmatic viscera within the thorax, as high as

the level of carina (Fig. 2). The patient was scheduled for an emergency operation. During the laparotomy, a 10-cm defect of the tendinous membrane of the left hemidiaphragm, through which the colon and the spleen passed into the thoracic cavity, was observed. Following the reduction of intra-abdominal viscera, a chest tube was placed and the defect was repaired with interrupted sutures using size 0 non-absorbable polypropylene suture thread. At exploration, no additional abdominal pathology was observed and the operation was terminated. On postoperative day 8, chest tube was removed but blood gas levels were still abnormal, therefore the patient had tracheostomy. Pulmonary functions improved following tracheostomy and the patient was weaned from the ventilator. The patient was discharged following improvement in general state and laboratory findings.

DISCUSSION

Authors of large series reported that traumatic diaphragmatic ruptures are secondary to blunt traumas in 75% and to penetrating traumas in 25%. However, exact percentages are not known due to missed cases^[2]. Non-specific symptoms such as chest pain (22%), abdominal pain (28%), dyspnea (24%), tachypnea, shortness of breath during acute and/or chronic period should be treated as highly suspicious and lead to diagnosis^[6]. Deterioration in blood gases anytime after the trauma, especially after blunt traumas, should be evaluated carefully. Diaphragmatic injuries following blunt traumas most commonly occur in the left posterolateral region. This region is weak due to the fact that this region is comprised of pleuroperitoneal membrane. Further, the right hemidiaphragm is congenitally stronger and supported inferiorly by the diaphragmatic surface of the liver, which makes the occurrence on the right side less common. Left diaphragmatic ruptures comprise 68.5-87% of all ruptures^[2, 7, 8, 9]. Positive intra-abdominal and negative intra-thoracic pressures cause abdominal viscera enter into the thorax, resulting in a compression on the lung, mediastinal shift and circulatory problems. Unilateral rupture of the diaphragm that contributes to two-thirds of the tidal volume decreases pulmonary functions by 25-50%, which in turn, gives rise to the symptoms^[2]. Two hypotheses have been proposed with respect to delayed injuries^[10]. With the arterial supply being compromised after injury, the diaphragm can be ruptured secondary to negative intra-thoracic pressure, especially after extubation^[11]. Muscle necrosis, wide inflammation and laceration observed in delayed cases support this

hypothesis^[10]. Another hypothesis is missing the diagnosis. Suspicion plays an important role in the diagnosis of ruptures. Sometimes even advanced imaging techniques may not be sufficient to establish the diagnosis and instead may result in the placement of a chest tube and the injury of the colon or the liver due to misdiagnosis of pneumothorax, hemothorax^[15]. The success rates of radiological imaging techniques vary in different series. The success rates of plain chest radiographs in establishing the diagnosis vary between 25-70 %^[4, 6, 12, 13]. CT, although accepted as the ideal technique has diagnostic success rate between 0-100%^[2, 14, 15]. Sensitivity and specificity of CT range between 33-83 and 76-100%, respectively^[1, 12, 17]. The constraints of CT arise from its inability to differentiate the hemidiaphragm from the liver and the neighboring soft tissues from the respiratory movements of the lungs^[6]. No significant difference has been found between plain radiographs and CT with respect to diagnostic success rate^[14]. Ultrasound has been tried in difficult-to-diagnose right diaphragmatic hernias but its success has been limited to 50% due to the difficulty in visualizing ruptured diaphragmatic layers^[14, 16]. Magnetic resonance imaging ^[MRI], on the other hand, can only be used in hemodynamically stable patients and therefore has limited use diaphragmatic injuries. To the present day, MRI has been used in a single case and its diagnostic success rate was low^[17]. Due to the limited number of noninvasive techniques, thorascopic and laparoscopic examinations have been resorted but they also proved not 100% successful in establishing the diagnosis due to the presence of the liver ^[14]. Peritoneal lavage has 66-75% sensitivity but it is not diagnostic; it aids diagnosis of accompanying^[7]. Radionuclide imaging of the liver or lung can be used to differentiate the boundaries of liver and lung in right diaphragmatic hernias^[15]. In many patients with diaphragmatic injury, diagnosis was established intra-operatively or identified during follow-up^[15]. Especially in left sided diaphragmatic ruptures, a progressive decrease in pulmonary functions and deterioration in blood gas analyses should raise physician's suspicion. Since 89% of diaphragmatic injuries are accompanied by intra-abdominal pathologies, the most suitable mode of treatment would be primary repair through abdominal approach or mesh reinforcement^[2, 6]. On the other hand, transthoracic approach is more suitable when there is intrathoracic compression, complex ruptures and liver herniation^[10]. Marked herniation of intra-abdominal viscera into the

thorax can be identified radiologically. However, it is not always possible to identify a clear-cut herniation in all, especially delayed cases. Therefore, diaphragmatic injuries should be suspected when the diaphragm is mildly elevated on plain radiographs, there is a shadow of the liver in the thorax on CT images, a discoid atelectasis on the base of the lung, mediastinal shift, abdominal shadowing in the thorax or mild pulmonary dysfunction^[14]. Morbidity following diaphragmatic injuries is as important as the mortality and pulmonary empyema, atelectasis, pneumonia, gastro-pleural fistula and delayed extubation are the most commonly encountered problems. When the diagnosis is delayed, so would be the restoration of the diaphragmatic functions. This, in turn, delays the pulmonary functions of the patient to be fully recovered. In such as cases, similar to our study, additional tracheostomy may be required. Factors that affect the prognosis include age, hemodynamic instability and early diagnosis within the first 24 h^[18]. In conclusion, diaphragmatic ruptures are rare but can be fatal and should not be dismissed in patients with blunt trauma.

REFERENCES

1. Rosati, C., 1998. Acute traumatic injury of the diaphragm. *Chest Surg. Clin. North. Am.*, 8: 371-9.
2. Shah, R., S. Sabanathan, A.J. Mears and A.K. Choudhury, 1995. Traumatic rupture of diaphragm. *Ann. Thorac. Surg.*, 60: 1444-9.
3. Wiencek Jr, R.G., R.F. Wilson and Z. Steiger, 1986. Acute injuries of the diaphragm. An analysis of 165 cases. *The j. Thoracic and Cardiovascular Surg.*, 92: 989-993.
4. Reber, P.U., B. Schmied, C.A Seiler, H.U Baer, A.G Patel, *et al.*, 1988. Missed diaphragmatic injuries and their long-term sequelae. *J Trauma.*, 44: 183-8.
5. Jhonson, C.D., 1988. Blunt injuries of the diaphragm. *Br. J. Surg.*, 75:226.
6. Athanassiadi, K., G. Kalavrouziotis, M. Athanassiou and P. Vernikos, 1999. Blunt Diaphragmatic Rupture. *Eur. J. cardiothorac Surg.*, 15:369-474.
7. Boulanger, B.R., D.P. Milzman, C. Rosati and A. Rodriguez, 1993. A comparison of right and left blunt traumatic diaphragmatic rupture. *J. Trauma.*, 35: 255-60.
8. McElwee, T.B., R.T. Myers and T.C. Penall, 1984. Diaphragmatic rupture from blunt trauma. *Am. Surg.*, 50: 143-9.

9. Sharma, O.P., 1989. Traumatic diaphragmatic rupture: not uncommon entity-personal experience with collective review of the 1980's. *J. Trauma*, 29: 678-82.
10. Sirbu, H., T. Busch and J. Spillner, 2005. Late bilateral diaphragmatic rupture: Challenging Diagnostic and Surgical Repair. *Hernia*, 9: 90-2.
11. Meyers, B.F. and C.J. McCabe, 1993. Traumatic diaphragmatic hernia: Occult marker of serious injury. *Ann. Surg.*, 218: 783-790.
12. Murray, J.G., E. Caoili, J.F. Gruden and S.J.J. Evans, 1996. Acute Rupture of the Diaphragm due to Blunt Trauma: Diagnostic Sensitivity and Specificity of CT. *AJR*, 166: 1035-9.
13. Spann, J.C., F.E. Wariaku and M. Wait, 1995. Evaluation of video-assisted thoracoscopic surge the diagnosis of diaphragmatic injuries. *Am. J. Surg.*, 170: 628-31.
14. Nau, T., H. Seitz, M. Mousavi and V. Vecsei, 2001. The Diagnostic Dilemma of Traumatic Rupture of the Diaphragm. *Surg. Endosc.*, 15: 992-996.
15. Sözüer, E., E. Ok, L. Avcıoğlu, C. Küçük and M. Kerek, 2001. Travmatik Diafragma Yaralanmaları. *Ulusal Travma Dergisi*, 7: 176-180.
16. Kim, H.H., Y.R. Shin, K.J. Kim, S.S. Hwang, H.K. Ha, J.Y. Byun and K.H. Choi, 1997. Blunt Traumatic Rupture of the Diaphragm: Sonographic Diagnosis. *J. Ultrasound Med.*, 16: 593-98.
17. Shanmuganathan, K., S.E. Mirvis, C.S. White and S.M. Pomertantz, 1996. MR imaging evaluation of Hemidiaphragms in Acute Blunt Trauma: Experience with 16 Patients. *Am. J. Roentgenol.*, 167: 397-402.
18. Mihos, P., K. Potaris, J. Gakidis and J. Paraskevopoulos, 2003. Traumatic Rupture of the Diaphragm: Experience with 65 Patients. *Injury*, 34: 169-172.