

## Antiproliferative Activity of *Aspergillus terreus* Taxol Against Ehrlich Solid Tumor *In vivo* and *In vitro*

<sup>1</sup>Nabila Zein and <sup>2</sup>Ashraf S.A. El-Sayed

<sup>1</sup>Biochemistry Division, Department of Chemistry,

<sup>2</sup>Department of Microbiology and Botany, Faculty of Science, Zagazig University, 44519 Zagazig, Egypt

**Key words:** Ehrlich ascites carcinoma, Taxol, ALT, AST, MCF-7, KI67

### Corresponding Author:

Nabila Zein

Biochemistry Division, Department of Chemistry, Faculty of Science, Zagazig University, 44519 Zagazig, Egypt

Page No.: 38-43

Volume: 14, Issue 3, 2020

ISSN: 1815-9362

Research Journal of Pharmacology

Copy Right: Medwell Publications

**Abstract:** Taxol has been approved as a powerful broad range anticancer drug, however, the accessibility and price of this drug are the main challenges. Thus, fungal source with feasibility of molecular and nutritional manipulations could be the alternative promising platform for bulk production of Taxol. Taxol has been produced by *Aspergillus terreus* and its chemical identity has been validated from our previous work, however, its biological functionality has not been investigated. Thus, the objective of the current study was to assess the antitumor efficiency of *A. terreus* extracted Taxol (AT-Taxol) towards EAC solid tumor in male Swiss albino mice. Ehrlich solid tumor cells were inoculated subcutaneously into mice, then the animals were injected with AT-Taxol i.p. and continued for 30 days. AT-Taxol displayed a significant cytotoxic effect against breast cancers (MCF-7) by inhibiting the expression of Antigen KI-67, a nuclear protein associated with the cellular proliferation, comparing to positive controls. As well as, positive control mice showed a dramatic increase of serum ALT, AST activities and liver tissue homogenate lipid peroxidation rate (MDA) accompanied with decline on the level of serum albumin that were ameliorated with AT-Taxol treatment. A plausible reduction on the mice overall body weight, in addition to tumor weight and volume with AT-Taxol treatment comparing to positive controls. From the histo-pathological analysis, AT-Taxol exhibited a significant improvement on different pathological features induced by EAC solid tumor oxidative stress, comparing to positive control mice.

### INTRODUCTION

Taxol is the most widely chemotherapeutic agent against different solid tumors<sup>[1]</sup> via stabilizing the

polymerization of microtubules that leads to cell cycle arrest at the mitotic phase and thus apoptosis<sup>[2]</sup>. Taxol has been produced by different sources; From the bark of *Taxus brevifolia*, however, the yield of Taxol ranged from

0.001-0.05%, thus, for producing of 1 g it does need 8-10 kg of plant bark which collected from 4-5 plants<sup>[3,4]</sup> in addition to vulnerability of this plant to fluctuation with different ecological and environmental conditions<sup>[5]</sup> that make searching for alternative sources of Taxol is an urgent need. Semisynthetic process using biosynthetic intermediates of Taxol from the needles of *T. baccata* is the current approach for Taxol production<sup>[6,7]</sup>, however, the lower yield of these intermediates, unwanted byproducts, heterogeneity, reproducibility and epigenetic mutations of *T. baccata* are the practical hurdles for this strategy. Alternatively, fungal sources producing Taxol raise the hope for commercial production of this drug, due to the feasibility of molecular engineering, fermentation cultural conditions, short life span and practicability of Taxol separation from the fungal cultures. Production of Taxol from various endophytic fungi as well as the different molecular and nutritional manipulation techniques to enhance the yield of this compound have been frequently reported<sup>[8]</sup>. Taxol has been produced and chemically characterized from *Aspergillus terreus*, endophyte of *Podocarpus gracilior*<sup>[9]</sup>, however, its cytotoxicity and antiproliferative activity against tumor cells had not been assessed. Thus, the objective of the current was to evaluate the cytotoxic effect and anticancer efficiency of Taxol derived from *A. terreus* against various solid tumors *in vivo* and *in vitro*.

## MATERIALS AND METHODS

**Fungal Taxol and cell lines preparation:** Taxol had been extracted from *Aspergillus terreus* and chemically identified using TLC, HPLC and various Spectroscopic analyses<sup>[9]</sup>.

Human breast cancer cell line (MCF-7) was purchased from the Egyptian National Cancer Institute. Standard concentrations of fungal Taxol were prepared in 0.1% DMSO. The MCF-7 cells were seeded in 96 well plate and incubated for 24 h, then treated with the fungal Taxol and the plate was further incubated for 72 h. The media were removed and cell cultures were incubated with MTT reagent for 4 h at 37°C to form formazon complex, the absorbance was read at 540 nm and cytotoxicity percentage was calculated.

### *In vivo* cytotoxicity study

**Experimental animals:** The 30 adult male Swiss albino mice (8 weeks old) were obtained from the National Cancer Institute, Cairo University, their weight ranging from 20-25 g of the same bred, acclimated for 7 days for adaptation before the beginning of experiment. Experimental design: Group 1; negative control mice injected with 2.5 mL saline. Group 2;

Positive control mice injected subcutaneously by  $2 \times 10^6 \times 2.5$  mL EAC solid tumor cells at the right hind limb cells. Group 3; Positive control mice treated with Taxol at dose  $2 \text{ mg kg}^{-1}$  BW i.p. once daily respectively for 30 days. By the end of experiment, mice from each group were weighed then solid form of the tumor were removed and weighed. All the explained procedures were carried out according to the Animal Ethics of Faculty of Medicine, Zagazig University that confirmed to follow NIH guidelines Committee guidelines (15-08-263 (IACUC)).

**Blood analysis:** Blood samples for biochemical analysis were collected into plain tubes, clotting, centrifuged for 15 min at 4000 rpm and the serum were collected and stored at -20°C till use.

### **Tissue collection and histopathological examination:**

Liver and kidney from each animal group were directly excised, after the end of the experiment and rinsed in saline. Kidneys were preserved in 10% buffered formalin, while liver have been cut into 2 parts one of them kept in phosphate buffer saline for biochemical analysis while the other part was preserved in 10% buffered formalin for histopathological examination. Sections of both liver and kidney tissues were stained by Hematoxylin and eosin and examined by microscope<sup>[10]</sup>. After weighing of the EAC solid tumor, its volume ( $\text{mm}^3$ ) was calculated by the equation  $A \times B^2 \times 0.5$  where, A is the longest diameter and B is the shortest diameter<sup>[11]</sup>. The EAC solid tumor cells have been fixed in 10% buffered formalin for immune histochemical investigation.

**Immunohistochemical analysis:** The expression of antigen KI-67 was analyzed Immunohistochemically according to the protocol of Jakob *et al.*<sup>[12]</sup>. The slides of solid tumor were incubated with the 1ry antibody (monoclonal Antibody KI-S11) overnight at 4°C in humidified chamber, then incubated with 2ry antibodies Bright Vision Horseradish Peroxidase (HRP) conjugated with anti-mouse IgG polymer (HRP-conjugated secondary antibodies) at 37°C for 30 min. The reaction development was visualized with DAB chromagen dye, then stained by Myers hematoxylin counter stain and examined by microscope.

**Biochemical analysis:** Malondialdehyde as the end product of lipid peroxidation in liver tissue homogenate was estimated according to Satoh<sup>[13]</sup> using Biodiagnostic kit (Biodiagnostic Company, Giza/Egypt). Serum levels of ALT, AST and albumin were determined<sup>[14]</sup> using Biodiagnostic kit (Biodiagnostic Company, Giza/Egypt).

**Statistical analysis:** All data are expressed as mean $\pm$  Standard Deviation (SD) using one way of variance (ANOVA) by SPSS 14.0 Version<sup>[5]</sup>.  $p < 0.05$  were considered as statistically significant.

## RESULTS AND DISCUSSION

Taxol has been extracted from *A. terreus*, chemically identified using TLC, HPLC, HNMR and CNMR as previously described from our studies<sup>[9]</sup>. The cytotoxic activity of extracted *A. terreus* Taxol was assessed against MCF-7 cells and retina cell lines *in vitro*. From the obtained results (Table 1), fungal Taxol has a noticeable cytotoxic effect on MCF-7 cell line with  $IC_{50}$  value about  $38.03 \mu\text{g mL}^{-1}$ , with no remarkable effect on normal retina cell line as a control, validating the absence of cytotoxicity of this compound to the normal cells and thus confirming their applicability in experimental animals. The efficiency of Paclitaxel of *Taxus brevifolia* bark was investigated against different EAC solid tumors bearing mice and displayed a strong activity against ovarian, breast and lung cancer via interfering with their tubulin proteins, causes selective apoptosis<sup>[16]</sup>. Interestingly, Taxol of *A. terreus* showed a dramatic anticancer activity to the experimental animal tumor model (Ehrlich solid tumors) and (MCF-7) human breast cancer cell line in both *in vivo* and *in vitro*. Taxol has been reported to have apoptotic effect on diverse number of cancer cell lines. Our results of remarked cytotoxic effect of fungal Taxol on breast cancer cell line (MCF-7) were coincident with those reported by Kim *et al.*<sup>[17]</sup> who stated that viability of MCF-7 cells was suppressed by paclitaxel treatment accomplished by AMPK signaling throughout the regulation of FOXO3a and EF1 $\alpha$ .

From the obtained results (Table 2), the tumor volume has been significantly reduced by about 47.9 % in response to fungal Taxol treatment ( $1.5 \pm 0.1 \text{ mm}^3$ ), comparing to the tumor volume of positive control mice ( $2.8 \pm 0.3 \text{ mm}^3$ ). While, the tumor weight in positive control mice ( $1756.4 \pm 0.1 \text{ mg}$ ) was decreased approximately by 31.7% upon treatment with fungal Taxol ( $1164.5 \pm 0.2 \text{ mg}$ ). Overall, the treatment with fungal Taxol reduced the elevated body weight caused by EAC solid tumor by 7.5% as the body weight was  $27.4 \pm 3.2$  and  $25.3 \pm 2.3$  in positive control mice and Taxol treated mice, respectively. Our results demonstrated that fungal Taxol has a significant reducing effect on tumor volume and weight while it has a slightly negative effect on the overall body weight. Consistent results were obtained by Singh *et al.*<sup>[18]</sup> in which the viable cells count, tumor volume and tumor weight along with the increase in the life span of animals were fundamental properties of anticancer compounds. Moreover, the cytotoxic potential of 2-quinolone derivatives was observed in solid tumor model as the result of immune system activation

Table 1: Cytotoxic activity test against human tumor cell line MCF-7 (breast cancer cell line) and normal retina cell line (RPE1)

Cell line	MCF-7	RPE1
$LC_{50} (\text{mg mL}^{-1})$	38.0	-

Table 2: Effect of fungal taxol on body weight, tumor volume and tumor weight

Groups	Body weight (g)	Tumor weight (mg)	Tumor volume ( $\text{mm}^3$ )
Positive control	$27.4 \pm 3.2$	$1756.4 \pm 0.1$	$2.8 \pm 0.3$
Fungal taxol	$25.3 \pm 2.3$	$1164.5 \pm 0.2^*$	$1.5 \pm 0.1^*$
Change (%)	7.5	31.7	47.9
Negative control	$25.9 \pm 3.8$	-	-

n = 10 mice per group and  $^*p < 0.01$  vs. positive control group

Table 3: Effect of fungal taxol on some biochemical parameters

Groups	ALT (U $\text{mL}^{-1}$ )	AST (U $\text{mL}^{-1}$ )	Albumin (mg $\text{dL}^{-1}$ )	MDA (nmol $\text{g}^{-1}$ )
Negative control	$37.3 \pm 4.5$	$99.5 \pm 9.7$	$3.9 \pm 0.1$	$105.0 \pm 1.3$
Positive control	$105 \pm 9.3$	$264.9 \pm 3.7$	$2.7 \pm 0.4$	$208.7 \pm 4.1$
Fungal taxol	$50.8 \pm 3^*$	$128.3 \pm 6.4^*$	$3.6 \pm 0.1^*$	$116.5 \pm 1.7^*$
Change (%)	51.6	51.1	33.3	44.2

n = 10 mice per group and  $^*p < 0.01$  vs. positive control group

which is verified by decrease in tumor volume and weight that may reflected the cell cycle arrest and the generation of apoptosis or necrosis in cancerous cells Kumar *et al.*<sup>[19]</sup>.

From the biochemical analysis, fungal Taxol treatment showing a plausible improvement on liver functions of positive control mice. From the results (Table 3), Taxol treatment lowered the ALT and AST activity by 51.6 and 51.1%, respectively, comparing to control group. The level of albumin was increased by 33.3% in response to Taxol treatment, comparing to positive control mice. In case of tumor bearing mice, activities of ALT, AST were found to be increase more drastically with decline of albumin level due to acute and permanent toxicities persuaded by EAC cells. After treatment with Taxol of EAC bearing mice, these values have been meliorated to normal values. From these results, treatment with Taxol prevented the damage generated by EAC. The MDA level in liver tissues homogenates was decreased by 44.2% homogenate for Taxol treated mice comparing to positive control ones. To evaluate the hepatoprotective effects of fungal Taxol, biochemical parameters was reviewed as well as histopathological analysis of experimental animals. Several agents could lead to induction of liver diseases that can be aggravate into hepatocellular damage as evidenced by elevation of serum ALT, AST activities and decreasing on albumin serum level<sup>[20]</sup>.

EAC bearing mice showed cellular degeneration caused by carcinogenesis, EAC cells causes hepatotoxicity that was reversed by the protective effect of fungal taxol to great extent. Similar results were reported in assessment of the antioxidant effect of grape seeds against Ehrlich solid tumor induced oxidative stress, hepatic dysfunction and pathological changes in the liver

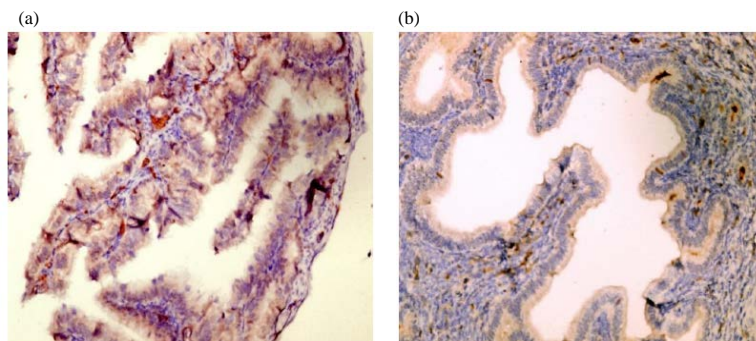


Fig. 1(a, b): Photomicrograph of mice EAC solid tumor showing, (a) Positive control and (b) Fungal taxol groups, respectively (Hematoxylin counterstain  $\times 400$ ). Showing that fungal taxol inhibited expression of KI-67 in tumor tissues as compared to positive control animals

of albino mice as cleared by the increase of ALT and AST, elevation in MDA level accompanied by a decline in GSH, SOD and CAT and albumin levels in blood and liver. Histopathologically and structurally, liver of EAC bearing group showed hepatic degeneration with sinusoidal and lymphocytic infiltration, increase of collagen fibers, irregular nuclei, altered mitochondria and increase of secondary lysosomes. Therefore, normalization of liver DNA and protein content along with reduced MDA level with increase in the antioxidant parameters accompanied with improvement in pathological features of examined hepatic lesions, revealed the potent antioxidant properties of grape seeds by protecting the liver from the oxidative stress caused by the introduction of EAC<sup>[21]</sup>. Distinct correlation was observed between free radical generation and development of cancer as excessive free radical generation in oxidative stress causes damages in macromolecules<sup>[22]</sup>. The lipid undergoes peroxidation at the primary site generating more free radicals which migrate along with circulation to the other sites<sup>[23]</sup>. MDA is one of the well-known markers for carcinogenesis at elevated levels in liver which is the organ for many metabolic reactions such as drug activation, detoxification and lipid peroxidation. In present study, a significant elevation in liver MDA level was observed in EAC bearing mice (positive control group) which supports the role of oxidative stress in cancer progression and treatment with fungal Taxol reduced this elevation. The elevated level of MDA was observed in EAC inoculated mice suggesting the effect of oxidative stress in cancer progression<sup>[19]</sup>.

From the histological analysis of EAC solid cells, a significant effect on the expression of KI67 protein was observed upon treatment with Taxol comparing to positive controls. Taxol treatment displayed a significant inhibition on the expression of KI67 of tumor cells as shown from the few scattered immunostained nuclei with moderate intensity comparing to positive control mice.

The expression of KI67 was increased by about 10/ HPF immunostained nuclei with marked intensity as shown in Fig. 1, approving the potentiality of Taxol to inhibit the process cellular proliferation and neovascularization of tumor cells. KI-67 is a nuclear protein appears inside the nucleus during cell division in all stages of cell cycle except G0 and considered as a good marker for cell proliferation<sup>[24]</sup>. The fraction of KI-67-positive tumor cells is often correlated with the clinical course of carcinomas of breast, prostate, brain, nephroblastoma tumors in which the prognostic value for survival and tumor recurrence have repeatedly been proven in uni-and multivariate analysis<sup>[25]</sup>. The data in our experiment clearly show the significant inhibition of KI-67 expression on tumor cells upon treatment with fungal Taxol, comparing to positive control animals.

From the histological features, a plausible restoring and protection to the tissues of liver and kidney upon Taxol treatment was observed, comparing to positive control ones. Our findings (Fig. 2), revealed that Taxol treatment exhibited a significant improving to liver and kidney features as it overwhelms the injurious fluctuations resulted from the tumor progression. EAC inoculation in mice showed strong abnormalities in the histology of nearly all studied organs which were reduced by Taxol supplementation that indicates its antiproliferative and hepatoprotective effect. As liver tissue sections showed normal central vein, sinusoids and hepatic parenchyma in negative control group while positive control group showed focal hepatocellular dysplasia with pleomorphic hyper-chromatic nuclei and frequent mitosis, Taxol treatment showed infiltration of hepatic lobule with non-specific inflammatory cells (Fig. 3). For kidney tissue sections showed normal renal cortex in negative control while positive control group showed a few scattered aggregates of inflammatory cells while Taxol treated mice showed a focal degeneration of tubular epithelium (Fig. 3).

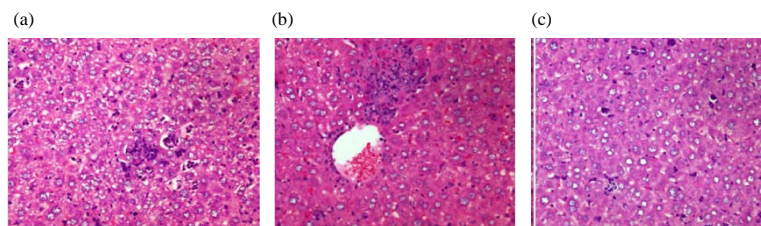


Fig. 2(a-c): Photomicrograph of mice liver (H&E×400) showed, (a) Negative control group: showed normal hepatocytes with normal nucleus, (b) Positive control group: showed cellular inflammatory infiltration, haemorrhage and congestion in blood vessel and (c) Fungal taxol group: Where fungal taxol overwhelms the injurious fluctuations resulted from the tumor progression

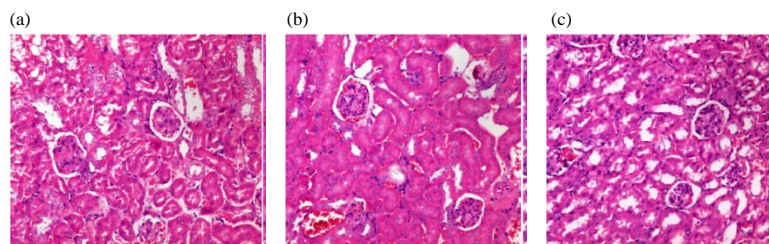


Fig. 3(a-c): Photomicrograph of mice kidney (H&E×400) showed, (a) Negative control group: with normal glomeruli, proximal and distal tubules, (b) Positive control group: with atrophy of renal corpuscle and there was wide spacing of tubules, atrophy of the lining epithelium and reticulated casts with inthelumen and (c) Fungal taxol group: where fungal taxol causes improvement in the kidney as a whole although, proximal tubules showed histological changes in the form of widening of tubular lumen and vacuolation of some of the lining cells

## CONCLUSION

In conclusion, *A. terreus* Taxol had a significant antiproliferative effect against EAC solid tumors as confirmed from the biochemical parameters, histological and immunological properties with undetectable toxicity to the overall physiology of the experimented mice.

## ACKNOWLEDGEMENTS

We deeply thank Dr. Samir Nassar, Professor of Histopathology, Faculty of Science, Zagazig University for his valuable guidance on the histological analyses.

## REFERENCES

01. Van Vlerken, L.E.V. and M.M. Amiji, 2006. Multi-functional polymeric nanoparticles for tumour-targeted drug delivery. *Expert Opin. Drug Delivery*, 3: 205-216.
02. Zhou, C., H. Cheng, W. Qin, Y. Zhang and H. Xiong *et al.*, 2017. Pygopus2 inhibits the efficacy of paclitaxel-induced apoptosis and induces multidrug resistance in human glioma cells. *Oncotarget*, 8: 27915-27928.
03. Wani, M.C., H.L. Taylor, M.E. Wall, P. Coggon and A.T. McPhail, 1971. Plant antitumor agents. VI. The isolation and structure of taxol, a novel antileukemic and antitumor agent from *Taxus brevifolia*. *J. Am. Chem. Soc.*, 93: 2325-2327.
04. Malik, S., R.M. Cusido, M.H. Mirjalili, E. Moyano, J. Palazon and M. Bonfill, 2011. Production of the anticancer drug taxol in *Taxus baccata* suspension cultures: A review. *Process Biochem.*, 46: 23-34.
05. Wang, C., Y. Wang, Y. Wang, M. Fan, F. Luo and Z. Qian, 2011. Characterization, pharmacokinetics and disposition of novel nanoscale preparations of paclitaxel. *Int. J. Pharm.*, 414: 251-259.
06. Holton, R.A., C. Somoza, H.B. Kim, F. Liang and R.J. Biediger *et al.*, 1994. First total synthesis of taxol: 1. Functionalization of the B ring. *J. Am. Chem. Soc.*, 116: 1597-1598.
07. Exposito, O., M. Bonfill, E. Moyano, M. Onrubia, M.H. Mirjalili, R.M. Cusido and J. Palazon, 2009. Biotechnological production of taxol and related taxoids: Current state and prospects. *Anti-Cancer Agents Medicinal Chem. (Formerly Current Med. Chem.-Anti-Cancer Agents)*, 9: 109-121.
08. El-Sayed, A.S., S.E. Abdel-Ghany and G.S. Ali, 2017. Genome editing approaches: Manipulating of lovastatin and taxol synthesis of filamentous fungi by CRISPR/Cas9 system. *Applied Microbiol. Biotechnol.*, 101: 3953-3976.



09. El-Sayed, A.S., S. Safan, N.Z. Mohamed, L. Shaban, G.S. Ali and M.Z. Sitohy, 2018. Induction of taxol biosynthesis by *Aspergillus terreus*, endophyte of *Podocarpus gracilior* Pilger, upon intimate interaction with the plant endogenous microbes. *Process Biochem.*, 71: 31-40.
10. Culling, C.F., 1983. *Handbook of Histopathological and Histochemical Staining Techniques*. 3rd Edn., Butterworth, London, UK.
11. Orsolic, N., Z. Tadic, V. Benkovic, A. Horvat, D. Lisicic and I. Basic, 2006. Stimulation of hematopoiesis by a water-soluble derivative of propolis in mice. *Pharmacologyonline*, 3: 698-705.
12. Jakob, C., T. Liersch, W. Meyer, H. Becker, G.B. Baretton and D.E. Aust, 2008. Predictive value of Ki67 and p53 in locally advanced rectal cancer: Correlation with Thymidylate synthase and histopathological tumor regression after neoadjuvant 5-FU-based chemoradiotherapy. *World J. Gastroenterol. WJG.*, 14: 1060-1066.
13. Satoh, K., 1978. Serum lipid peroxide in cerebrovascular disorders determined by a new colorimetric method. *Clin. Chim. Acta*, 90: 37-43.
14. Varely, H., 1994. *Practical Clinical Biochemistry*. 5th Edn./Vol. I, William Heinemann Medical Books Ltd, London, UK., Pages: 601.
15. Levesque, R., 2007. *SPSS Programming and Data Management: A Guide for SPSS and SAS Users*. 4th Edn., SPSS Inc., Chicago.
16. Flores, M.L., C. Castilla, R. Avila, M. Ruiz-Borrego, C. Saez and M.A. Japon, 2012. Paclitaxel sensitivity of breast cancer cells requires efficient mitotic arrest and disruption of Bcl-xL/Bak interaction. *Breast Cancer Res. Treat.*, 133: 917-928.
17. Kim, J.H., J.O. Lee, N. Kim, H.J. Lee and Y.W. Lee *et al.*, 2015. Paclitaxel suppresses the viability of breast tumor MCF7 cells through the regulation of EF1 $\alpha$  and FOXO3a by AMPK signaling. *Int. J. Oncol.*, 47: 1874-1880.
18. Singh, H., S. Banerjee, S. Karan and T.K. Chatterjee, 2013. Evaluation of anticancer activity of Andaman freeze dried powdered *Morinda citrifolia* L. fruit against Ehrlich Ascites Carcinoma (EAC) cell induced liquid and solid tumor in Swiss Albino mice. *Int. J. JPR. BioMedRx*, 1: 567-573.
19. Kumar, N., I. Dhamija, P.V. Raj, B.S. Jayashree and V. Parihar *et al.*, 2014. Preliminary investigation of cytotoxic potential of 2-quinolone derivatives using *in vitro* and *in vivo* (solid tumor and liquid tumor) models of cancer. *Arabian J. Chem.*, 7: 409-417.
20. Muhammad, R.H., A.A. Muhammad and R.K. Muhammad, 2011. Inhibition of Ehrlich's ascites carcinoma by ethyl acetate extract from the flower of *Calotropis gigantia* L. in mice. *J. Appl. Biomed.*, 8: 47-54.
21. Ali, D.A., N.K.B. El-Din and R.F. Abou-El-Magd, 2015. Antioxidant and hepatoprotective activities of grape seeds and skin against Ehrlich solid tumor induced oxidative stress in mice. *Egypt. J. Basic Applied Sci.*, 2: 98-109.
22. Rahman, K., 2007. Studies on free radicals, antioxidants and co-factors. *Clin. Interv. Aging*, 2: 219-236.
23. Ayala, A., M.F. Munoz and S. Arguelles, 2014. Lipid peroxidation: Production, metabolism and signaling mechanisms of malondialdehyde and 4-Hydroxy-2-nonenal. *Oxid. Med. Cell. Longevity*, Vol. 2014. 10.1155/2014/360438
24. Saunders, D.E., W.D. Lawrence, C. Christensen, N.L. Wappler, H. Ruan and G. Deppe, 1997. Paclitaxel induced apoptosis in MCF 7 breast cancer cells. *Int. J. Can.*, 70: 214-220.
25. Gerdes, J., U. Schwab, H. Lemke and H. Stein, 1983. Production of a mouse monoclonal antibody reactive with a human nuclear antigen associated with cell proliferation. *Int. J. Cancer*, 31: 13-20.