



## OPEN ACCESS

### Key Words

Prematurity, perinatal autopsy, congenital heart disease, pulmonary hypoplasia

### Corresponding Author

Buddeshwar Hiwale,  
Department of Pathology, Grant  
Government Medical College and Sir  
JJ Group of Hospitals, Mumbai, India

### Author Designation

<sup>1</sup>Associate Professor

<sup>2,3</sup>Assistant Professor

<sup>4</sup>Professor

<sup>5,6</sup>Junior Resident

**Received:** 14 February 2024

**Accepted:** 19 March 2024

**Published:** 6 April 2024

**Citation:** Vikas C. Maindad, Uma Vijayaraghavan, Vivek D. Kharolkar, Buddeshwar Hiwale, Shruti Dayanand Patil and Krishna Govind, 2024. A Case Series of Pediatric Autopsy-Unveiling Insights into Childhood Mortality and Review of Literature. Res. J. Med. Sci., 18: 89-96, doi: 10.59218/makrjms.2024.6.89.96

**Copy Right:** MAK HILL Publications

## A Case Series of Pediatric Autopsy-Unveiling Insights into Childhood Mortality and Review of Literature

<sup>1</sup>Vikas C. Maindad, <sup>2</sup>Uma Vijayaraghavan, <sup>3</sup>Vivek D. Kharolkar, <sup>4</sup>Buddeshwar Hiwale, <sup>5</sup>Shruti Dayanand Patil and <sup>6</sup>Krishna Govind

<sup>1-6</sup>*Department of Pathology, Grant Government Medical College and Sir JJ Group of Hospitals, Mumbai, India*

### ABSTRACT

Pediatric autopsy studies serve as invaluable tools in understanding the complex dynamics of childhood mortality, shedding light on the underlying causes and contributing factors. In this study, we assess five cases of pediatric autopsies performed at a tertiary care center, examining the clinical presentations, pathological findings causes of death among deceased infants. The cause of death in each case is revealed upon detailed histopathological examination and has been discussed in detail. This case series underscores the necessity for a systematic approach to autopsy examinations and emphasizes the techniques utilized during the autopsy process within the institution. The study contributes to a deeper understanding of pediatric mortality patterns and highlights the importance of autopsy examination in elucidating the complex etiology of childhood deaths. The findings gleaned from this case series have significant implications for clinical management, epidemiological surveillance public health interventions aimed at reducing childhood mortality rates globally.

## INTRODUCTION

Perinatal deaths pose a major challenge for a developing country like India with an infant mortality rate of 26.619 deaths per 1000 live births as of<sup>[1]</sup>. Pediatric autopsy paves way to careful post-mortem examination of deceased children, serves as a window into the intricate complexities of childhood diseases, congenital anomalies unforeseen medical conditions. Autopsy committee of the college of American Pathologists describe autopsy as “a medical surgical procedure by a physician for the welfare of the living through the study of those patients for whom all our current knowledge and technology were inadequate”. The practice of conducting autopsy in the modern world has declined and this is especially true in the field of pediatric autopsy. Important pre requisites for exercising a smooth conduct of pediatric autopsy preliminarily consists of a good autopsy team with good skill and knowledge in the smooth conduct of a systematic autopsy and coming into the establishment of cause of death by gross and microscopic examination. The goals of a pediatric autopsy include determination of cause of death of the baby as well as establishing the underlying medical conditions or factors that led to the child's death. It also provides insights into the pathophysiology of diseases affecting children, genetic and congenital conditions and potential risks for future children of such parents<sup>[2]</sup>.

In certain cases, autopsies are conducted for legal purposes, such as in cases of suspected child abuse or when there are concerns about medical malpractice. We will be discussing four perinatal autopsy cases conducted in our institute, focusing on the approach taken during the autopsy and the obtained findings. Our goal is to emphasize key aspects of the autopsy process and highlight the significant findings in each case.

**Case 1:** A male baby born at 31 week of gestation and weighed 1.7kg. The mother was a 19 year old primigravida who was detected with raised blood pressure and went into early pre term labor. The baby did not cry immediately after birth and hence was given bag and mask ventilation for 30 seconds. APGAR score at birth was 6/10 and 8/10 at 5 minutes. The anomaly scan of the patient revealed MCA/ UA pulsation index >1 with normal doppler study. Later, baby was shifted to NICU in view of birth asphyxia and was intubated. On examination of the baby the peripheries was cold and clammy with peripheral cyanosis of skin. There was clinical suspicion of cyanotic congenital heart disease in the baby. In spite of all resuscitative measures baby was declared dead after 10 hours of birth. Autopsy examination of the neonate was performed after obtaining informed written consent from parents, after explaining the procedure and the relevance of the outcome. External

examination of the baby did not show any evidence of congenital anomalies or injuries. The genitals were examined and was consistent with the sex of the baby. Oral, nasal and anal orifices were patent. Femur length (FL)-59.5mm, Head circumference (HC) was 304mm and Intercanthal distance (ICD)-18.5mm. The patency of trachea was established by probing. The body was opened by standard Y shaped incision. The normal situs of the organs was appreciated.

Post mortem findings revealed congestion in the meninges of brain, lungs, liver, spleen and kidneys. The cerebrum was edematous with petechial hemorrhage over the ventricles in the grey matter. Hydrostatic test of the lung was positive. The heart weighed 21grams and was normal in size. In view of suspicion of canonic congenital heart disease, the heart was opened by inflow outflow technique. All valves, chambers and vessels were identified and was normal. Thymus, gall bladder, adrenals, stomach and large intestine were also examined and appeared normal. The serosal surface of small intestine showed narrowing of lumen. Microscopic examination revealed oedema, congestion and parenchymal hemorrhage in cerebrum and cerebellum. The myocardium and the coronaries were unremarkable. Lungs revealed massive pulmonary oedema and marked congestion. Liver showed sinusoidal dilatation and congestion along with extramedullary hematopoiesis. The small intestine histology revealed submucosal and serosal fibrosis. Adrenal had hemorrhage and congestion. Spleen, pancreas and kidneys showed congestion of the vessels (Fig. 1). Impression and cause of death was given as massive pulmonary oedema, parenchymal hemorrhage in brain and adrenal hemorrhage in an early preterm baby with very low birth weight. Prematurity is a leading cause of neonatal mortality preterm babies are at a higher risk of various health complications, including those that can lead to death.

**Case 2:** A 20 year old female with 27 weeks gestation of dichorionic diamniotic twin pregnancy resulted in still birth of male child and delivered extremely low birth weight (750 grams), appropriate for gestation female child. She was a case of eclampsia with preterm premature rupture of membrane and one episode of convulsion. APGAR score at 1 minute was 3/10 and at 5 minutes was 6/10. Baby was kept on ventilator and given one dose of surfactant in view of severe hyaline membrane disease. Chest X-ray revealed white out lungs. In spite of all resuscitation measures, child could not be revived and was declared dead on same day of birth. Autopsy examination of the neonate was performed after obtaining informed written consent from parents and after explaining the procedure and the utility of the outcome. External examination of the baby did not show any evidence of congenital anomalies or injuries. The genitals were examined and

was consistent with the sex of the baby. Oral, nasal and anal orifices were patent. Femur length (FL)-54mm, Head circumference (HC) was 251mm and Intercanthal distance (ICD)-16 mm. The patency of trachea was established by probing. The body was opened by standard Y shaped incision. The normal situs of the organs was appreciated.

Post mortem findings revealed congestion of lungs, liver, spleen and kidneys. The brain was oedematous. The heart weighed 25 grams and was normal in size. The heart was opened by inflow outflow technique. All valves, chambers and vessels were identified and was normal. Trachea, thymus, pancreas, gall bladder, adrenals, stomach and intestines were also examined and appeared normal. Microscopic examination revealed oedema and congestion in cerebrum and cerebellum. The meninges showed congestion. The myocardium and the coronaries were unremarkable. Lungs revealed hyaline membrane formation, collapsed lung parenchyma, focal pulmonary oedema and squames in alveoli. Liver showed sinusoidal dilatation and congestion along with extramedullary hematopoiesis. Adrenal had hemorrhage and congestion. Spleen, pancreas, trachea and thymus showed congestion of the vessels. Immature renal parenchyma was noted (Fig. 2). Impression and cause of death was given as hyaline membrane disease in a preterm baby.

**Case 3:** A 25 year old female G2P2L1, 30 weeks of gestation was admitted in view of medical termination of pregnancy with written legal petition for termination of pregnancy. Fetal echo was suggestive of tricuspid valve with absent leaflets suggestive of tricuspid atresia associated with right ventricular hypoplasia with large muscular ventricular septal defect. Mother gave birth to live low birth weight (1.6 kg) male child and baby was not able to maintain saturation on NIV. APGAR score at 1 minute was 6/10 and at 5 minutes was 8/10. On general examination, the baby had no gross congenital abnormalities with peripheral cyanosis, cold extremities and multiple bruise marks on the body, Baby was later intubated and in spite of all resuscitation measures could not be revived and declared dead on same day of birth. The baby was then referred for post mortem for the cause of death. External examination of the baby did not show any evidence of congenital anomalies or injuries. The genitals were examined and was consistent with the sex of the baby. Oral, nasal and anal orifices were patent. Femur length (FL)-57 mm, Head circumference (HC) was 269mm and Intercanthal distance (ICD)- 17.4 mm. The patency of trachea was established by probing. The body was opened by standard Y shaped incision. The normal situs of the organs was appreciated. Post mortem findings revealed congestion in the meninges of brain, lungs, liver, gall bladder and

kidneys. The cerebrum was oedematous. The heart weighed 27 grams and was normal in size. In view of suspicion of cyanotic congenital heart disease, the heart was opened by inflow outflow technique. Tricuspid leaflets were not well developed with ventricular septal defect present. The right ventricle appeared hypoplastic. Thymus, pancreas, spleen, adrenals, stomach and intestines were also examined and appeared unremarkable. Microscopic examination revealed oedema and congestion in cerebrum and cerebellum. The myocardium and the coronaries were unremarkable. Lungs revealed immaturity, alveolar collapse and congestion. Liver showed sinusoidal dilatation and extramedullary hematopoiesis. Right adrenal had hemorrhage and left was unremarkable. Kidneys showed immaturity, hemorrhage and congestion. Pancreas revealed absence of islet cells, congestion and peripancreatic adipose tissue showed hemorrhage (Fig. 3). Impression and cause of death was given as tricuspid atresia with hypoplastic right ventricle and ventricular septal defect in an early preterm pregnancy.

**Case 4:** 24 year old primigravida with 36 weeks of gestation delivered female child by LSCS in view of severe oligohydramnios. 28 weeks ultrasonography was suggestive of a single intrauterine pregnancy with AFI- 6cm suggestive of oligohydramnios, left polycystic kidney and umbilical cord around the neck of the baby. The birth weight was 2.1 kg and baby cried after bag and mask ventilation. APGAR score at 1 minute was 7/10 and at 5 minutes was 8/10. Oral, nasal, vaginal and anal orifices were patent. Femur length (FL)-74 mm, Head circumference (HC) was 269mm and Intercanthal distance (ICD)-18 mm. The patency of trachea was established by probing. The body was opened by standard Y shaped incision. The normal situs of the organs was appreciated.

On general examination, the baby had hyper flexion of left hip joint and respiratory distress. Baby was later incubate and in spite of all resuscitation measures could not be revived and declared dead on same day of birth. As the death of the baby happened within 24 hours of birth, a post mortem examination of the baby was warranted. The genitals were examined and was consistent with the sex of the baby. Post mortem findings revealed diffuse subarachnoid hemorrhage. Lungs appeared hypoplasia and single left kidney was appreciated on post mortem examination. The kidney appeared polycystic. The genital system was intact. The heart, liver, spleen, thymus, stomach and gall bladder were unremarkable. Microscopic examination revealed oedema and congestion in cerebrum and cerebellum. The meninges showed focal hemorrhage. The pleura of the lungs showed lymphocytic infiltrate and hemorrhage. In the lungs, immaturity was noted with hemorrhage and occasional

squames in alveoli. The kidneys showed disorganized parenchyma with multiple cysts lined by flattened to cuboidal epithelium, compact tubules with fibromuscular collars, occasional immature glomeruli and immature connective tissue suggestive of cystic renal dysplasia. The myocardium and the coronaries were unremarkable. Liver showed sinusoidal congestion and extramedullary hematopoiesis (Fig. 4). Impression and cause of death given was cystic renal dysplasia and renal agenesis, pulmonary hypoplasia in a primigravida with oligohydramnios.

**Case 5:** A 20 year old primigravida with 26 weeks of gestation was admitted in view of early preterm labor. Mother gave birth to live very low birth weight (1.1 kg) male child by normal vaginal delivery with breech presentation. The mother was 20 year old primigravida who is a known case of seizure disorder with on and off medication and with history of single seizure episode in the third trimester of pregnancy. She had also taken antitubercular drugs for pulmonary tuberculosis one year back. APGAR score at 1 minute was 6/10 and at 5 minutes was 9/10. On general examination, the baby had no gross congenital abnormalities with peripheral cyanosis and cold extremities. Patient was kept on BiPaP in the NICU. Baby was later intubated and in spite of all resuscitation measures could not be revived and declared dead on same day of birth. The baby was then referred for post mortem for the cause of death. External examination of the baby did not show any evidence of congenital anomalies or injuries. The genitals were examined and was consistent with the sex of the baby. Oral, nasal and anal orifices were patent. Femur length (FL)-48 mm, Head circumference (HC) was 272 mm and Intercanthal distance (ICD)- 17.7 mm. The patency of trachea was established by probing. The body was opened by standard Y shaped incision. The normal situs of the organs was appreciated.

Post mortem findings revealed congestion in the meninges of brain, liver, spleen, esophagus, stomach, intestine and kidneys. The heart weighed 15 grams and was normal in size. The heart was opened by inflow outflow technique. A defect measuring 0.5x0.4cm was noted in the intertribal septum with a tissue flap at the margin through which light passed favoring foramen ovale. Lungs, adrenals, pancreas were also examined and appeared unremarkable. Microscopic examination revealed oedema, congestion and immaturity in cerebrum and cerebellum. Cerebellum showed focal parenchymal hemorrhage. The pericardium, myocardium and the coronaries were unremarkable. Lungs revealed immaturity, alveolar collapse with some overinflated alveoli and oedema. Liver showed sinusoidal dilatation and extramedullary

hematopoiesis. The adrenals showed immaturity. Kidneys and pancreas showed immaturity and congestion (Fig. 5). Impression and cause of death given was preterm premature neonate with cerebellar parenchymal hemorrhage and focal pulmonary oedema.

## RESULTS AND DISCUSSIONS

A perinatal autopsy is a postmortem examination performed on a fetus or newborn shortly before or after birth, typically within the perinatal period, which includes the late stages of pregnancy and the early days of life. The purpose of a perinatal autopsy is to determine the cause of death and to gather additional information that may help understand any underlying medical conditions or abnormalities. Autopsies can be important for medical research, education and improving clinical practices. They may also offer emotional closure for parents by providing answers about the cause of their child's death. In this case series, our aim was to systematically discuss the method of perinatal autopsy and its implication to the modern science<sup>[3]</sup>. The standard autopsy protocol begins with attainment of permission for autopsy and examining the case with serious note of each and every detail in the case file. While specific protocols may vary slightly among different jurisdictions and institutions,



Fig. 1: (Case-1) 1A: Bits of cerebrum with ark brown areas  
1B: Cerebral parenchyma with hemorrhage  
1C: Alveoli are distended with oedema fluid- Massive pulmonary oedema

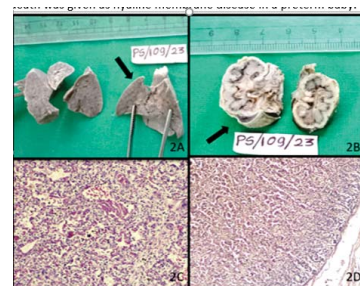

Fig. 2: (Case-2) 2A: Firm lungs  
2B: Kidneys with adrenals  
2C: Hyaline membrane formation, collapsed lung parenchyma, focal pulmonary oedema and squames in alveoli  
2D: Adrenals showing hemorrhage in parenchyma



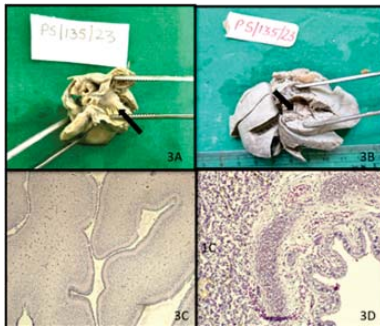


Fig. 3: (Case-3) 3A: Tricuspid atresia  
3B: Lungs showing congestion  
3C: Cerebellum with oedema and congestion  
3D: Lungs with immaturity, alveolar collapse and congestion

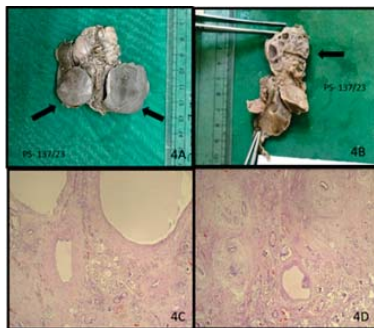


Fig. 4: (Case-4) 4A: Hypoplastic lungs  
4B: Single kidney with multiple cysts  
4C, 4D: Multiple cysts lined by cuboidal to flattened epithelium, compact tubules and immature connective tissue suggestive of cystic renal dysplasia

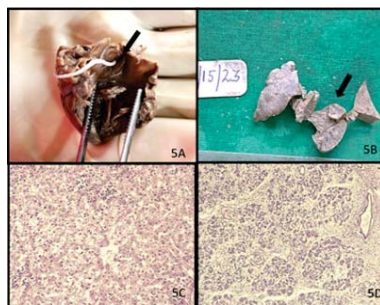


Fig. 5: (Case-5) 5A: Heart demonstrating Foramen ovale with a thread  
5B: Lungs  
5C: Liver with sinusoidal dilatation and extramedullary haematopoiesis  
5D: Pancreas showing congestion and immaturity

The general steps include. Conducting a detailed external examination of the body is of paramount importance<sup>[5]</sup>. Document any injuries, scars, tattoos, or other relevant external features and take photographs to document the external findings. All the natural orifices should be evaluated for patency. The crown heel length, head circumference, palpation of fontanel,

inter canthal distance should be recorded. A syringe is inserted to the pleural cavity and checked for air or fluid in the cavity<sup>[4]</sup>. Collection of specimens such as blood, urine vitreous fluid for toxicological analysis is of great importance<sup>[6]</sup>. The blood is collected from the right atrium after opening the pericardial sac and searing the surface of the right atrium with a heated spatula. In case any cardiovascular anomaly is suspected, blood maybe taken from the inferior venacava, just before its entry to the right atrium. Tissue for cytogenetics may be obtained from amniotic membranes of the placenta, spleen, fascia, pericardium, pleura, blood for lymphocytes, skin and retro peritoneal tissue for fibroblasts in a suitable media for transportation.

The body is opened through a standard Y-shaped incision, commonly known as a Y-incision<sup>[7]</sup>. The internal organs their size, color, consistency and any abnormalities is documented. Organ by organ removal or otherwise the Rokitsansky technique of removing organs as a unit may be employed for examination. It is prudent to apply the modified Rokitsansky method in which the pathological organ of importance is removed with priority and later organs as a unit may be retrieved. After organ removal, the body cavity is examined for presence of any skeletal or spinal abnormalities<sup>[8]</sup>. The organs are weighed and measured, as abnormalities in size can provide valuable information. Relevant samples based on the case, such as tissues for histological examination as per the suspected cause of death is of great importance.

The scalp is examined for abnormality of pattern of growth of hair as it is proportional to the abnormalities in the structure of the brain. The anterior and posterior fontanelle are measured and checked for fullness or depression. The caladium is examined for developmental defects, fractures or hemorrhage. The sagittal sinus is examined. The brain is removed from anterior to posterior by placing ones's hand behind the head. The brain is weighed and external features are examined. The cerebral cortex development is examined according to the age. The brain is fixed in formalin before further examination for 1-2 weeks<sup>[9]</sup>. Post fixation the brain is examined for hemorrhage, necrosis or developmental abnormalities. The vessels at the base of the brain, mainly the Circle of Willis should be identified and any variations are recorded. The cerebellum and brain stem are separated from the rest of the brain. The brainstem, cerebellum and cerebrum are further sectioned for close examination. If significant hemorrhage is noted in cerebral hemispheres, the meningeal arteries are followed to examine for aneurysm or rupture. Coronal sections are made from anterior to posterior at 1cm-1.5cm intervals with brain in base up position. Including sections through stalk of pituitary, the maxillary bodies, the apex of the interpeduncular fossa and top

**Table 1: Patent foramen ovale**

|               | Patent foramen ovale  | Atrial septal defect   |
|---------------|---|--|
| Definition    | It is a heart defect that arise due to failure of closing foramen ovale after birth | It is a heart defect that arise due to incorrect formation of septum tissue between the two atri |
| Hole size     | The hole is comparatively smaller   | The hole is comparatively larger   |
| Septum tissue | Septum tissue is correctly formed   | Septum tissues are not correctly formed  |
| Types         | No types  | Secundum ASD, primum ASD and senus venosus ASD etc.  |

of cerebral peduncle will help in close examination of numerous nuclei of deep gray matter. The pituitary is removed from the hypophyseal fossa and the middle ear is opened to look for any evidence of infection. The eye should be thoroughly examined if indicated<sup>[10]</sup>.

The heart should be separated from the lungs following identification and transaction of pulmonary arteries and veins and noting their origin and position and also as far from the heart as possible. The heart is weighed and open by inflow outflow method. The atrium is examined for completeness of the foramen ovale and entrance of the coronary sinus. The tricuspid valve is measured and the leaflets are examined. The right ventricle is measured for its thickness. The interventricular septum is examined for defects<sup>[11]</sup>. The bicuspid valve is also examined for completeness. The arch of aorta is inspected for any anomalies like coarctation or patent ductus arteriosus. If myocardial infarction is suspected, the heart is bread loafed and papillary muscles are most commonly affected in infants with myocardial damage.

The thymus is weighed and a representative section should be submitted. Tongue is not to be removed necessarily but it can aid in better evaluation of mouth and nasopharynx with added benefit of providing skeletal muscle tissue for evaluation. Care must be taken to not damage the lips or outside of the mouth<sup>[12]</sup>. Evaluation of respiratory system calls for the thorough study of lungs. The pulmonary arteries and veins are examined for emboli and if present the whole segment of the vessel is opened to see the extent of vascular obstruction. The larynx is separated from trachea and its patency, vocal cords and laryngeal mucosa is evaluated<sup>[13]</sup>. Thyroid is dissected out from the lower larynx and representative section from thyroid as well as adjacent soft tissue is submitted for evaluation of missed parathyroid tissue. The trachea is probed for its patency and size through the length as well as its cartilage rings for completeness.

The right and left lobes of the lung are weighed and the lobes are evaluated. The color and consistency of the lungs are noted. Ideally one lung is inflated with formalin with a syringe and fixed in it for an hour or overnight before sectioning it<sup>[14]</sup>. The other lung may be evaluated by probing the bronchi and vessels and sectioning the lung perpendicular to the hilum so that the parenchyma may be evaluated for lesions like cysts, abscesses, consolidation and hemorrhage. A representative section is taken from each of the five lobes as well as the pleural and hilar region for better

study of the pathological changes. The abdominal organs are evaluated in a female after separating the uterus and fallopian tubes from the abdominal block<sup>[15]</sup>. The spleen is dissected out from abdominal block after careful evaluation of the adjacent areas for any accessory spleens. The spleen is weighed and sectioned for histopathological evaluation.

The liver is dissected out from the diaphragm. The biliary tract is difficult to dissect in an infant and hence its patency can be demonstrated by making an incision in the duodenum in the region of ampulla of vater<sup>[16]</sup>. The gall bladder can then be compressed against the liver and bile expressed through the ampulla of the biliary tree if it is patent. The liver is weighed and sectioned at 1 cm intervals and representative sections are taken for microscopic evaluation. The kidneys, ureters and bladder can be dissected en bloc either with or without the renal arteries and section of aorta. The ureters are traced for its origin, course and entrance into the bladder and the kidneys are removed, weighed and examined by clearing off the soft tissue from the capsule and bisecting the kidney. The cortex and medullary thickness are measured and examined for lesions before sections are taken. The renal pelvis should be opened and the entrance to the ureters are examined as well as through its entire course. The bladder is opened and the mucosa is evaluated and a section is submitted. The urethra is probed for patency and in males a section from prostate is submitted after careful evaluation. In case of suspected urethral stricture or atresia, the urethra along with external genitalia is removed for its establishment. The bowel is separated from other organs from the sigmoid/rectum and towards the stomach using a pair of curved scissors to cut along the mesenteric attachment as close to the bowel as possible. The appendix is identified and the rest of the bowel may be wrapped around one's fingers while moving from distal to proximal bowel. The length of the small intestine, colon and appendix is taken and opened along the entire length. Representative sections from each bowel segment is given. The gastric contents are noted and can be saved for analysis. Sections are also taken from esophagus, esophageal-gastric junction and stomach<sup>[17]</sup>.

The above-mentioned approach was used in the autopsy of all the five cases described in this study. All the organs were meticulously grossed from organ blocks and the gross appearance, cut surface and microscopic appearance was recorded to establish the

cause of death. All the five cases in this case series have some interesting aspect to it. (Case 1) was of a 31-week baby who had cerebral parenchymal hemorrhage, massive pulmonary oedema and adrenal hemorrhage. Cerebral parenchymal hemorrhage has been claimed to be a consequence of prematurity with 50% incidence in babies of 24-30 weeks of gestation. Premature infants are at a higher risk of CPH due to the underdeveloped blood vessels in the brain, making them more prone to bleeding. Massive pulmonary edema refers to the accumulation of fluid in the lung tissue to an extent that it significantly impairs respiratory function. In premature infants, pulmonary edema can be associated with various conditions and hyaline membrane disease (also known as respiratory distress syndrome or RDS) is one such condition. The adrenal hemorrhage in neonates may be explained by the large size and increased vascularity of the organ. Another theory is that, when hypoxia occurs, the blood gets redistributed to the central nervous system, heart and adrenals and as a result of congestion of the organ, results in hemorrhage.

(Case 2) had hyaline membrane disease which is most commonly associated with prematurity and presents with respiratory distress syndrome. In very preterm infant, the terminal sacs are of small diameter and when collapsed in the absence of surfactant require considerable pressure to expand. The airways get damaged either because of the infant's own attempts at expanding or because of positive pressure from the ventilator. Hyaline membrane disease is the pathological manifestation of this acute lung injury in which damage to the vascular integrity allows fluid to leak from blood vessels into airspaces and the subsequent partial resorption of fluid leaves a proteinaceous fluid layer on the surface which is otherwise known as hyaline membrane<sup>[18]</sup>.

(Case 3) had tricuspid atresia and ventricular septal defect in an early preterm. This baby was posted for MTP in view of the fetal echo giving evidence of tricuspid valve with absent leaflets and ventricular hypoplasia and ventricular septal defect which was later established on autopsy. The meticulous grossing of heart by in flow- out flow method establishing all the chambers and valves helped in establishing the diagnosis. (Case 4) was of a 36week female baby with severe oligohydramnios, hyper flexion of the left hip, single polycystic kidney which was later found out to be cystic renal dysplasia and pulmonary hypoplasia which calls for its association with potter syndrome. Insufficient amniotic fluid during pregnancy (oligohydramnios) can contribute to lung hypoplasia. hypoplasia lungs are typically smaller in size and weight compared to normal lungs and the diaphragmatic surface of the heart lies above the heart apex. Lung hypoplasia is best defined as the ratio of lung weight to body weight which is 0.012 for infants with 28 weeks

gestation or more and 0.015 for those of lower gestation<sup>[19]</sup>. (Case 5) was of a 26 week preterm with very low birth weight with a defect in the inter atrial septum. The challenge was to differentiate between patent foramen ovale and atrial septal defect. The points that differentiate between the two are as follows:

The systematic approach to distinguish the two helped in their distinction. The post mortem team has to confirm the autopsy findings with the clinical cues and a provisional cause of death is arrived at. Later the histopathological and toxicological examination will provide the definite cause of death. It's crucial for forensic pathologists to approach each case with objectivity, attention to detail and adherence to established protocols to ensure accurate and reliable results. Additionally, the autopsy process is conducted with respect for the deceased and in compliance with legal and ethical standards.

## CONCLUSION

Perinatal autopsy plays a pivotal role in unraveling the intricacies of fetal and neonatal conditions, offering invaluable insights into the causes of perinatal mortality. The meticulous examination of these cases not only aids in understanding the complex interplay of factors contributing to perinatal mortality but also provides critical information for improving prenatal care, guiding future research advancing medical education. By emphasizing the importance of perinatal autopsy, we highlight its role as a powerful tool in enhancing our comprehension of fetal and neonatal pathology, ultimately contributing to advancements in perinatal healthcare<sup>[20]</sup>.

## REFERENCES

1. Macro trends. India Infant Mortality Rate 1950-2024.
2. J.T. Stocker, 2016. The Pediatric Autopsy. Pediatric Pathology. 4th ed. Philadelphia: Lippincott Williams and Wilkins., p-2.
3. College of American Pathologists Pamphlet. Autopsy: Aiding the Living by Understanding Death. Northfield,IL.
4. H.C. Wainwright, 2006 Jul. My Approach to Performing a Perinatal or Neonatal Autopsy. J. Clin. Pathol., 7: 673-680.
5. J. Abishake, S. Ninave and A. Keerti, 2023 Jan. A Compendium on Perinatal Autopsy in Neonates. Cureus. 1.
6. L.M. Ernst, 2015. A Pathologist's Perspective on the Perinatal Autopsy. Semin Perinatol., 1: 55-63.
7. T.Y. Khong, 2015. The Perinatal Necropsy. Keeling's Fetal and Neonatal Pathology: Springer; 15-46.
8. M.C. Pacheco and R.C. Reed, 2017. Pathologist Effort in the Performance of Fetal, Perinatal and

- Pediatric Autopsies: A Survey of Practice. Arch Pathol. Lab Med., 2: 209-214.
9. R. Widmann, R. Caduff and L. Giudici, 2017. *et al.*, Value of Postmortem Studies in Deceased Neonatal and Pediatric Intensive Care Unit Patients. Virchows Archive.
  10. S.J. Gordijn, J.J. Erwich and T.Y. Khong, 2002. Value of the Perinatal Autopsy: Critique. Pediatr Dev Pathol., 5: 480-488.
  11. Bhale, M.D. Chandrashekhar Prasad, Vare, M.D. Anil Gupta and M.D. Akshi, March 2021. Fetal Autopsy-Categories and Causes of Death at a Tertiary Care Center. The American Journal of Forensic Medicine and Pathology 42(1):p 12-15,
  12. M. Osborn, J. Lowe, P. Cox, B. Hargitai and T. Marton, 2017. Guidelines on autopsy practice: Fetal autopsy (2nd trimester fetal loss and termination of pregnancy for congenital anomaly). Royal College of Pathologists. :4-11.
  13. The Royal College of Obstetricians and Gynaecologists and Royal College of Pathologists. Fetal and Perinatal Pathology: Report of a Joint Working Party. London: RCOG Press., 2001.
  14. N. Johns, W. Al-Salti, P. Cox, M.D. Kilby, 2004. A Comparative Study of Prenatal Ultrasound Findings and Post-Mortem Examination in a Tertiary Referral Center. Prenat Diagn., 24: 339-346.
  15. U.S. Andola, A. AM, M. Ahuja and S.K. Andola, 2012. Congenital Malformations in Perinatal Autopsies: A Study of 100 Cases. J. Clin of Diagn Res., 10:1726-1731
  16. Gilbert- Barness. 2007. Potter's Pathology of the Fetus, Infant and Child. Causes of fetal and neonatal death. 2nd ed. Mosby Elsevier., p: 524-530.
  17. J. Ophoven, 2014. The Pediatric and Perinatal Autopsy Manual. The Forensic Postmortem. 1st ed. Cambridge University Press., p: 376-386.
  18. K. Pinneri and E.W. Matshes, 2017 Jun. Recommendations for the Autopsy of an Infant who has Died Suddenly and Unexpectedly. Acad Forensic Pathol., 2:171-181.
  19. J. Stephen, Gould, A.K. Webb and Anna Kelsey, 2013. Spencer's Pathology of the Lung. Congenital Abnormalities and Pediatric Lung Diseases, Including Neoplasms. 6th ed. Cambridge University Press., p: 91-95.
  20. D.M. Parham, V.H. Savell and C.P. Kokes, 2003 Mar-Apr. *et al.*, Incidence of Autopsy Findings in Unexpected Deaths of Children and Adolescents. Pediatr Dev Pathol., 2: 142-155.