

## ***In vivo* Evaluation of the Accuracy of Two Methods for the Bite Mark Analysis in Foodstuff**

<sup>1</sup>C. Stavrianos, <sup>1</sup>L. Vasiliadis, <sup>2</sup>J. Emmanouil and <sup>3</sup>C. Papadopoulos

<sup>1</sup>Department of Endodontology (Forensic Odontology),

<sup>2</sup>Department of Removable Prosthodontics,

School of Dentistry, Aristotle University, Thessaloniki, Greece

<sup>3</sup>Department of Forensic Sciences (Forensic Odontology),

University of Glamorgan, Wales, United Kingdom

---

**Abstract:** The aim of this study was to evaluate the accuracy of two methods for the bite mark analysis in foodstuff. For the purposes of this study ten suspects participated as possible perpetrators of a bite mark found in a fresh apple which was seized at a supposed crime scene. The sample was kept in a sealed bag and stored in a fridge. The following day researchers applied the technique of obtaining an impression of the bite mark in the apple using light body vinyl polysiloxane which was injected without pressure from a central point to the bite mark periphery. A ring was constructed as barrier using a heavy body vinyl polysiloxane. The next stage was to pour model from the bite mark impression with the use of dental stone. Next step was to take dental impressions of the possible suspects using alginate impression material (protesil) and pour dental casts of the dentitions with dental stone. About 2 independent forensic dentists compared the pattern of the bite mark with the dental casts of the suspects using two different methods each time: the docking procedure (direct method) and the computer-assisted overlay production technique with Adobe Photoshop CS4 software (indirect method). The results of this study showed that the computer-based method for bite mark analysis was as accurate as the docking procedure in cases with bite marks in an apple and may be useful in a variety of substrates.

**Key words:** Forensic odontology, computer-assisted bite mark analysis, overlay technique, docking technique, foodstuff, vinyl polysiloxane

---

### **INTRODUCTION**

The crimes in which bite marks may be found include murders, assaults of sexual or non-sexual nature, homosexual attacks or cases of physical and sexual abuse (Sweet, 2000; Dorion, 2005). A person's dentition is unique in its natural state. Factors that attribute to uniqueness include variations in dental alignment, rotation, wear, size of teeth, anomalies, fillings, chipping, fractures, notching, etc. Spatial orientation namely the position of each tooth within an arch is another important criteria. Bite marks on human skin and other substrates often reflect the individual dental characteristics with the spatial relationship (Dorion, 2005; Valenzuela, 2001). The subject of probability and uniqueness is extremely difficult because there is no legal precedent as to how many features contribute to a positive identification beyond reasonable doubt.

There are many cases in which bite mark evidence has been critical to the conviction or exoneration of criminal

defendants (Chiapparelli and Hughes, 1992). The forensic odontologists role is to collect, preserve, evaluate and interpret bite mark evidence. Evaluation and interpretation of evidence is the most difficult aspect and there are few dentists with adequate training and experience to carry out these complex procedures (Barsley, 2002). The analysis and comparison of bite marks is a continuously developing complex process that utilizes the newest technological discoveries (Aboshi *et al.*, 1994). One aspect of this comparison focuses on the 3D features of the biting surface of the suspect's teeth (Sweet *et al.*, 1998). Evidence analysis requires a comparison of the unknown mark found to known exemplars of the suspect's teeth.

There are numerous methods available to forensic odontologists to reproduce 2D or 3D examples of the suspect's dentition. The tooth exemplar independent of which method is used to produce it is called an overlay when biting surface data is transferred to clear acetate. This product is compared to the pattern of the bite mark

(Sweet and Bowers, 1998). Conclusions are reached by the odontologists regarding the relative concordance between the known exemplar and the unknown pattern. One of the methods commonly used to analyze bite marks is the overlay method of comparison, a technique that requires non-distorted and scaled to life-size photographs of the pattern of the bite mark. Computer-assisted technology can be utilized for bite mark evaluation (both on skin and inanimate objects) and lately as a tool for the production of comparison overlays (Barsley, 2002; Nambiar *et al.*, 1995a; Sweet and Bowers, 1998; Stavrianos *et al.*, 2003). Food and other compressible objects record a bite mark in the same manner as impression materials, its accuracy determined by the substrate and its tendency to deform, dehydrate or decompose following the bite. Foods like cheese, chewing gum, cake icing, chocolate and other candy can produce useable 3D impressions under favorable conditions. Fruits, vegetables, butter and preserved meats can also record identifiable bite marks but with more opportunity for distortion (Wolff *et al.*, 1998; McKenna *et al.*, 2000; Bernitz *et al.*, 2000). Bite marks particularly in fruits and vegetables are adversely affected. The greater the number of bite marks the more quickly they produce dehydrated and the bite marks are distorted. Dehydration of the perishable and distortion of the bite mark occur more slowly when the material is placed in a seal able plastic bag. Placing the bag into the refrigerator further slows the deterioration (Marshall, 1974; Webster and McDonald, 1981; David *et al.*, 2001). The analysis of bite marks on inanimate items varies to the analysis of a mark in skin. For example, in bite marks on cheese, chocolate or apples a docking procedure may be undertaken.

In these cases, the dental model of a suspect is applied to a cast of the bitten object to determine if they dock or match. Such analyses are relatively simple and are easily documented for presentation in court. Bites on flat surfaces for example on study can be analyzed using an overlay technique as would be done for a bite mark on skin. The conclusions that are reached are the same as those for traditional bite mark analyses (Sweet, 1995; Nambiar *et al.*, 1995b; American Board of Forensic Odontology (ABFO), 2000; Johansen *et al.*, 2000; Pretty and Sweet, 2001; Stavrianos *et al.*, 2003; Dorion, 2005).

## MATERIALS AND METHODS

In the present study during the investigation of the supposed crime scene an apple (Fig. 1) was found which appeared to have been bitten. The apple has been stored



Fig. 1: The bite mark in the apple which was seized at the supposed crime scene. Two sets of indentations appear. On the upper set four indentations appear the two central ones having a width estimated at 9 mm each one of them and the two lateral ones 7 mm. On the lower set six tooth marks can be distinguished and the width of each one is estimated at 5-6 mm. The marks do not appear aligned

in a fridge in a sealed bag. The purposes of this scenario were to investigate the bite mark found in the apple seized from the burglary crime scene and identify the perpetrator out of the ten suspects. The 10 suspects gave consent and dental impressions were taken with alginate impression material (Protesil, Class B, Type 1, PBC, Olmo di Creazzo, Italy) and dental casts of the impressions with dental stone (moldano) were constructed in dental laboratory.

The exhibits were handed over to two independent examiners for analysis. The pattern of the indentations found in the apple supports that there is no reasonable doubt that human teeth created the bite mark. Animal origin of the suspected bite mark should be ruled out. It has been caused by an adult's dentition. The bite mark in the apple has evidentiary value that allows comparing it with a dentition to determine a person as a biter.

An impression was taken of the bite in the apple using light body vinyl polysiloxane (R-dental GmbH, Harburg-Germany) (Fig. 2) which was injected without pressure from a central point to the bitemark periphery. A ring was constructed as barrier using a heavy body vinyl polysiloxane.

The next stage was to pour model from the bitemark impression with the use of dental stone (moldano) (Fig. 3). The handling of all materials was done according to the manufacturer's instructions. Additionally, the apple was




Fig. 2: Impression of the bite mark using light body vinyl polysiloxane



Fig. 3: The positive cast of the bite mark

electronically scanned with the use of A.B.F.O., scale No. 2 using the HP Scanjet 3770 digital flatbed scanner (Fig. 4). One set of upper and lower study casts of the dentition of the 10 suspects were electronically scanned with the use of A.B.F.O., scale No. 2 using the HP Scanjet 3770 digital flatbed scanner. Figure 5-8 show the dental casts of suspects 1 and 2. The materials collected were handed out to 2 independent forensic dentists. The following stage was to undertake a docking procedure in order to identify a possible biter. The dental cast of each of the 10 suspects dentition is applied to the positive cast of the bitten object to determine if they dock or match. For 9 out of 10 suspects there are discrepancies between the upper dentition and the pattern of the bite mark in the apple. Regarding suspect 2, the upper dental cast appears to correspond to the bite mark in the apple. The cast of the upper teeth appear to dock in to the cast of the bitemark. The same result appears for the lower teeth.




Fig. 4: Electronically scanned image of the apple with the use of the A.B.F.O scale

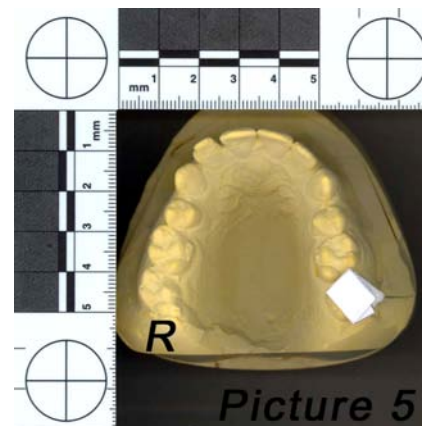


Fig. 5: The upper dental cast of suspect 1. The dentition of suspect 1 appears to have in the upper jaw two central incisors with their width estimated at 8.5 mm and the right lateral incisor has a width of 6 mm and the left lateral incisor has a width of 7 mm. There is a space between the lateral and the central incisor on the right side and there is a space between the left lateral incisor and the left canine. The upper right lateral incisor appears to have a buccal displacement as well

Figure 9 and 10 show the docking procedure for suspect 1 and the Fig. 11 and 12 show the docking procedure for suspect 2. Additionally, the computer-assisted overlay production technique was applied. Using the Adobe Photoshop CS4 software overlays of the dentition of the 10 suspects were produced and were compared with the pattern of the indentations in the apple

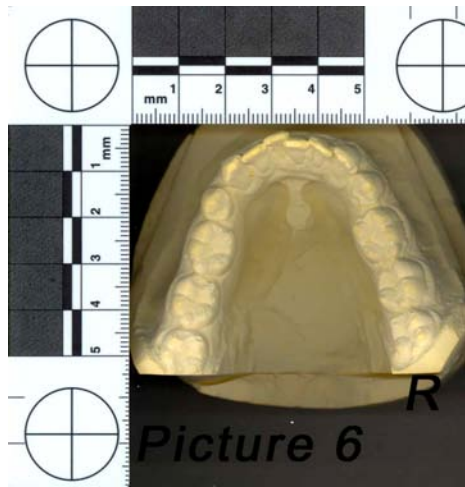


Fig. 6: The lower dental cast of suspect 1. The front lower teeth appear to be not aligned there is mild crowding and the right central incisor appears to be displaced lingually

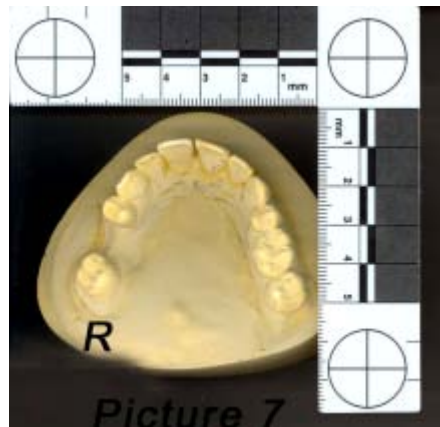

Fig. 7: The upper dental cast of suspect 2. The dentition of suspect 2 has in the upper jaw the two central incisors with a width of 9 mm and the two lateral incisors have width 7 mm each one of them. There is a diastema between the two central incisors

as they appear in Fig. 4. This was done as an additional medium of demonstration of the correspondence or not between the bite mark and the dentition. The overlays of the dentition were placed in my preferred position in relationship to the photograph of the bite mark. The overlays of the dentition for all suspects were produced with the Adobe Photoshop CS4 software and the comparison with the tooth marks in the apple showed that there is correspondence between the suspect's 2 dentition and the pattern of the bite mark. On the other hand the other suspects are excluded. Figure 13 and 14 show the comparison with the dentition of suspect 1 and

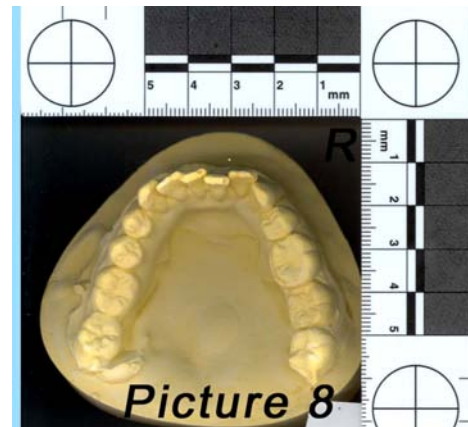


Fig. 8: The lower dental cast of suspect 2. In the lower jaw there is a mild crowding and right central incisor is lingually displaced

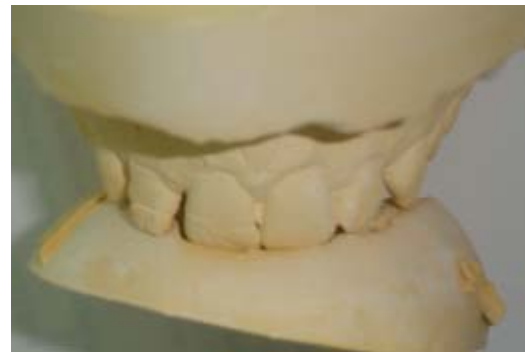

Fig. 9: Docking procedure for the upper dentition of suspect 1. The upper right lateral incisor is the tooth that would not correspond in particular with the indentation in the apple

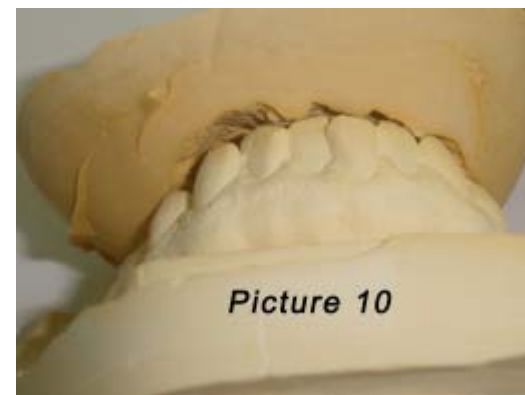


Fig. 10: Docking procedure for the lower dentition of suspect 1. The lower dentition is not correspondent to the bite mark



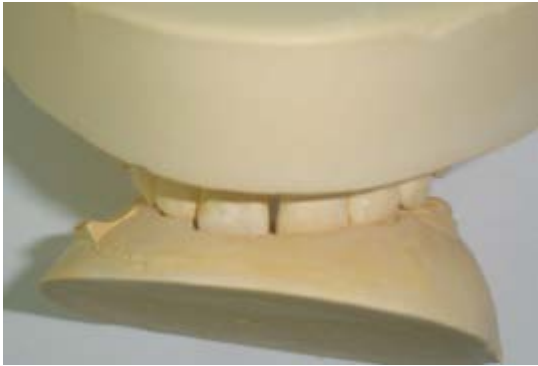

Fig. 11: Docking procedure for the upper dentition of suspect 2

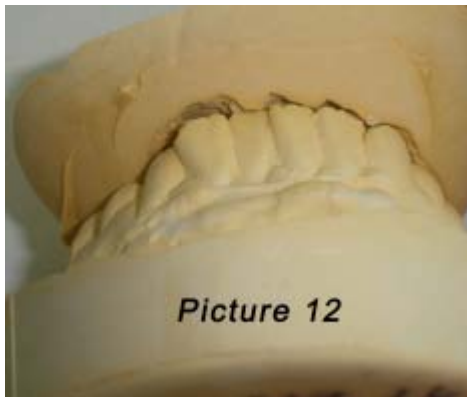


Fig. 12: Docking procedure for the lower dentition of suspect 2

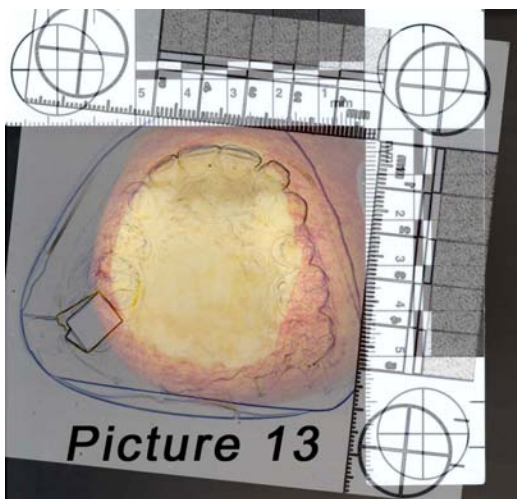


Fig. 13: Comparison of the upper dentition of suspect 1 with the bite mark pattern using the Adobe Photoshop CS4 software

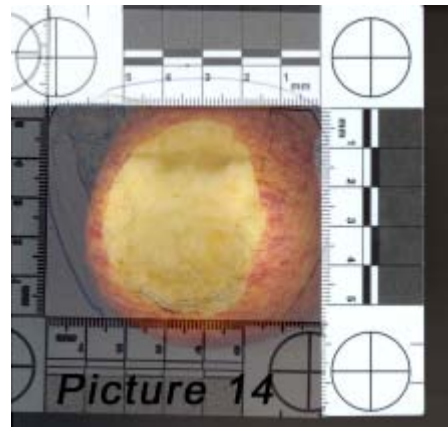


Fig. 14: Comparison of the lower dentition of suspect 1 with the bite mark pattern using the Adobe Photoshop CS4 software

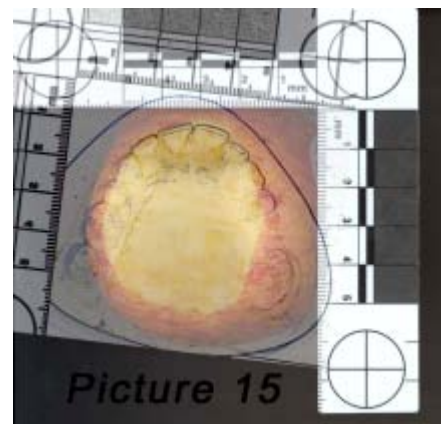


Fig. 15: Comparison of the upper dentition of suspect 2 with the bite mark pattern using the Adobe Photoshop CS4 software

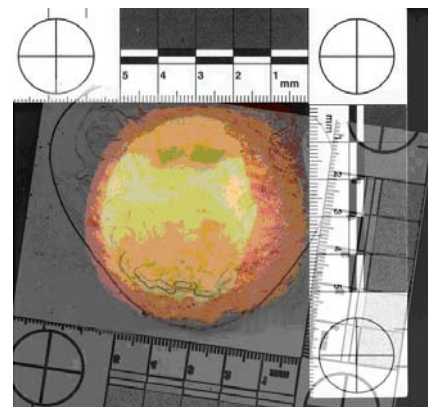


Fig. 16: Comparison of the lower dentition of suspect 2 with the bite mark pattern using the Adobe Photoshop CS4 software

the Fig. 15 and 16 show the comparison of the bite mark with the dentition of suspect 2 using the overlay technique.

## RESULTS AND DISCUSSION

The pattern of the indentations found on the apple supports that there is no reasonable doubt that teeth created the injury. The possibility of an animal bite mark is excluded. It is beyond reasonable doubt that has been caused by an adult's dentition. There is sufficient forensic evidence to draw conclusion on the link between a specific dentition and the injury. There are discrepancies between the bite mark and the dentitions of the 9 out of 10 suspects that will exclude them from having made the bite mark. Dentition similar to the teeth of suspect 2 could create the pattern of the bite mark found on the apple. If it is a close circle of suspects then the suspect 2 is the person responsible for creating the mark on the apple.

Dental science has much to offer law enforcement agencies in the detection and solution of crime (Sweet, 2000). Contemporary legal history is littered with cases where it has been possible to match a bite mark pattern to a suspect's dentition. Bite marks have been universally accepted in the courts but the fundamental validity and scientific basis for its use is frequently challenged (Pretty and Sweet, 2001). A review of the Forensic Odontology literature reveals multiple techniques for overlay production. There is an absence of reliability testing or comparison of these methods to a known or reference standard. Recent presentations, the publication of a manual and seminars in the use of a computer software program in bite mark analysis have generated a great deal of interest within the Forensic Odontology (Sweet and Bowers, 1998; Valenzuela, 2001).

In child abuse and other criminal cases the use of a computer based program may prove extremely helpful. There are a number of advantages in favour of a computer-assisted bite mark analysis such as reliability, reproducibility, easy to use, store, send and change dimensions of the images without affecting the clarity and accuracy of the picture (ABFO, 2000; Aboshi *et al.*, 1994; Williams and Porter, 1997; Herschaft *et al.*, 2006).

Sweet and Bowers (1998) compared the computer-based method to other production overlay techniques and it was proposed by them in 1998 as the gold standard, a test that is generally accepted as the most accurate of available tests. Bites may on occasions be left in foodstuff or other objects found at the scene of a crime and it may

be possible to match the teeth of a suspect to these marks or enquiry importantly to eliminate a suspect from an enquiry (Whittaker and MacDonald, 1989). It must be noted that in every day life circumstances, bite mark analysis is a more complex process; a skin or foodstuff bite may be distorted from a number of different factors. Nevertheless, the computer-based method is considered reliable and could be used for the construction of an analysis protocol.

The application of this computer technology to bite mark analysis is seen as an advantage for a more objective accurate overlay production method (Wood *et al.*, 1994; Sweet, 2000; David *et al.*, 2001; Dorion, 2005).

## CONCLUSION

According to the results of the present study the computer-based method (indirect method) for bite mark analysis was as accurate as the docking procedure (direct method) in respect to the identification of the perpetrator of bite marks found in foodstuff and may be useful in a variety of substrates.

## REFERENCES

- ABFO, 2000. Guidelines and standards: Bitemark Guidelines and Standards. American Board of Forensic Odontology, Colorado Springs.
- Aboshi, H., J.A. Taylor, T. Takei and K.A. Brown, 1994. Comparison of bite marks in foodstuffs by computer imaging: A case report. *J. Forensic Odontostomatol.*, 12: 41-44.
- Barsley, R.E., 2002. My view: Bite mark analysis, twenty-five years of observation and participation. *Forensic Odontol. News*, 21: 9-9.
- Bernitz, H., S.E. Piper, T. Solheim, P.J. van Niekerk and T.J. Swart, 2000. Comparison of bite marks left in foodstuffs with models of the suspects dentitions as a means of identifying a perpetrator. *J. Forensic Odontostomatol.*, 18: 27-31.
- Chiapparelli, L. and P. Hughes, 1992. Bite Marks in Tissue and in Inanimate Objects: Analysis and Comparison. In: *Practical Forensic Odontology*, Clark, D.H. (Ed.). Butterworth-Heinemann, Oxford.
- David, T.J., R.M. Haugseth and M.B. Hauptle, 2001. A comparative study of the methods of preservation of bitemarks in foodstuffs. *Proceedings of the Annual Meeting on American Academy Forensic Sciences, Odontology Section*, Seattle, Washington, February 22, 2001.

- Dorion, R.B.J., 2005. Bite Mark Evidence (Electronic Resource). Marcel Dekker, New York.
- Herschaft, M. Alder, D. Ord, R. Rawson and E. Smith, 2006. Manual of Forensic Odontology. ASFO, Impress Printing and Graphics Inc., New York, pp: 210-240.
- Johansen, R.J., R. Johansen and C.M. Bowers, 2000. Digital Analysis of Bite Mark Evidence. 1st Edn., Forensic Imaging Institute, Santa Barbara, California, pp: 118.
- Marshall, W., 1974. Bite marks in apples-forensic aspects. *Criminologist*, 9: 21-34.
- McKenna, C.J., M.I. Haron, K.A. Brown and A.J. Jones, 2000. Bite marks in chocolate: A case report. *J. Forensic Odontostomatol.*, 18: 10-14.
- Nambiar, P., T.E. Bridges and K.A. Brown, 1995a. Quantitative forensic evaluation of bite marks with the aid of a shape analysis computer program: Part 1; The development of SCIP and the similarity index. *J. Forensic Odontostomatol.*, 13: 18-25.
- Nambiar, P., T.E. Bridges and K.A. Brown, 1995b. Quantitative forensic evaluation of bite marks with the aid of a shape analysis computer program: Part 2; SCIP and bite marks in skin and foodstuffs. *J. Forensic Odontostomatol.*, 13: 26-32.
- Pretty, I.A. and D. Sweet, 2001. The effectiveness of bite mark overlays. *Proc. Am. Acad. Forensic Sci.*, 7: 165-165.
- Stavrianos, C., L. Vasiliadis, C. Gogos, E.M. Metska and N. Petalotis, 2003. In vitro evaluation of a computer-assisted overlay production technique. *Hellenic Dental J.*, 13: 9-13.
- Sweet, D. and C.M. Bowers, 1998. Accuracy of bite mark overlays: A comparison of five common methods to produce exemplars from suspects dentition. *J. Forensic Sci.*, 43: 362-367.
- Sweet, D., 2000. Human bite mark evidence. Proceedings of the European IOFOS Millennium Meeting, Aug. 23-26, Leuven, Belgium, pp: 75-79.
- Sweet, D., M. Parhar and R.E. Wood, 1998. Computer-based production of bite mark comparison overlays. *J. Forensic Sci.*, 43: 1050-1055.
- Sweet, D.J., 1995. Human Bitemarks: Examination, Recovery and Analysis. In: Manual of Forensic Odontology, Bowers C.M. and G.L. Bell (Eds.). American Society of Forensic Odontology, Colorado Springs, pp: 148-170.
- Valenzuela, A., 2001. Production of bite mark comparison overlays from 3D scanned images. *Proc. Am. Acad. Forensic Sci.*, 7: 166-166.
- Webster, G. and D.G. McDonald, 1981. Forensic aspects of bite marks in food. *Health Bull.*, 39: 107-111.
- Whittaker, D.K. and D.G. MacDonald, 1989. A Color Atlas of Forensic Dentistry. Wolfe Medical Publications, London.
- Williams, R.G. and B.E. Porter, 1997. Documentation of bite mark evidence using multiple computer assisted techniques. *J. Okla. Dent. Assoc.*, 88: 29-30.
- Wolff, D., R. Kennedy, E. Lounsbury, G. MacMaster and K. Olthuis et al., 1998. Dental casting materials for the recovery of toolmark impressions. Royal Canadian Mounted Police, Forensic Identification Research and Review Section Bulletin, pp: 43.
- Wood, R.E., P.A. Miller and B.R. Blenkinsop, 1994. Image editing and computer assisted bite mark analysis: A case report. *J. Forensic Odontostomatol.*, 12: 30-36.