

## Problems in Dental Reporting of Child Abuse: A Case Report

K. Louloudiadis, C. Stavrianos, A. Louloudiadis and A. Eliades  
Department of Endodontology (Forensic Dentistry), Aristotle University,  
School of Dentistry, Thessaloniki, Greece

**Abstract:** When a child presents for examination particularly if there is any evidence of severe or repeated trauma involved, the history may alert the dentist to the possibility of a child abuse. Perhaps because crying or speaking emanates from the mouth, this area is frequently the focus of attack in cases of violent child abuse. The main step in identification of suspected child abuse and neglect is the general physical assessment of the child for example the poor nutritional state and subnormal growth, the extraoral injuries, bruises or abrasions and bite marks and the oral lesions i.e., loosened or fractured teeth, tears of the labial or lingual frenula, fractures of jaws and trauma to the tongue. This case report aims to present a case of a physically abused child, two and a half years old from his mother. The examination revealed marks of four fingers of attacker's right hand on this victim's cheek from a hard slap to the face. In conclusion, the ability to properly identify suspicious injuries to the head, face, mouth and neck of a child is imperative for dentists.

**Key words:** Child abuse, neglect, forensic dentistry, dentist's responsibility, victim's cheek, physically abused child

---

### INTRODUCTION

Forensic odontology is a specialty of dentistry recognized in a few countries and is defined as the proper handling, examination and evaluation of dental evidence which will be then presented in the interest of justice by using dental records or ante-mortem photographs. Purely it is the overlap between the dental and the legal professions. It derives from the latin word forum which is the place where legal matters are discussed (Stavrianos, 2009). Forensic dentistry is occupied with a wide range of fields including identification and recognition of child or elder abuse or family violence cases (Stavrianos, 2009; Spencer, 2004). Child abuse can be defined as any non-accidental trauma, failure to meet basic needs or abuse inflicted upon a child by the caretaker that is beyond the acceptable norm of childcare in the culture (Kenney and Spencer, 1995; Kerani-Koumoutsea and Khabbaz, 1987). All dentists should have an understanding of child abuse and neglect be able to recognize the signs and symptoms and be familiar with the reporting laws of their respective country.

### CASE REPORT

In this study, a case of a physically abused child, two and half year years old from his mother is reported (Fig. 1).

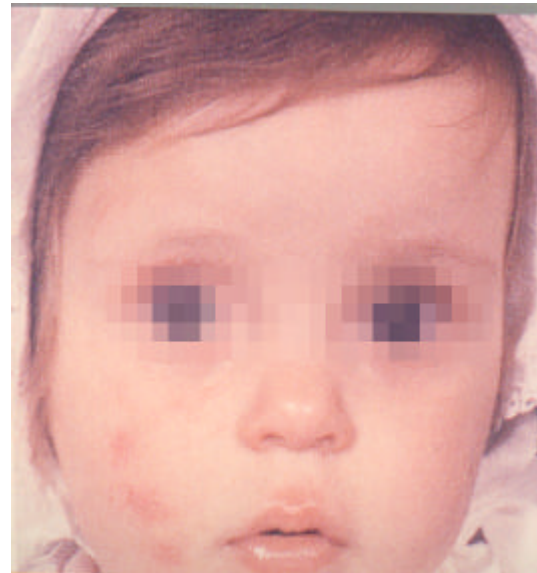

Fig. 1: A hard slap to the face left marks of four fingers of attacker's right hand on this victim's cheek

The examination revealed facial marks of four fingers of the attacker's right hand on the victim's cheek from a hard violent slap to the face. When questioned for her behavior, the mother gave as an explanation the crying of the child due to the eruption of primary teeth. In the

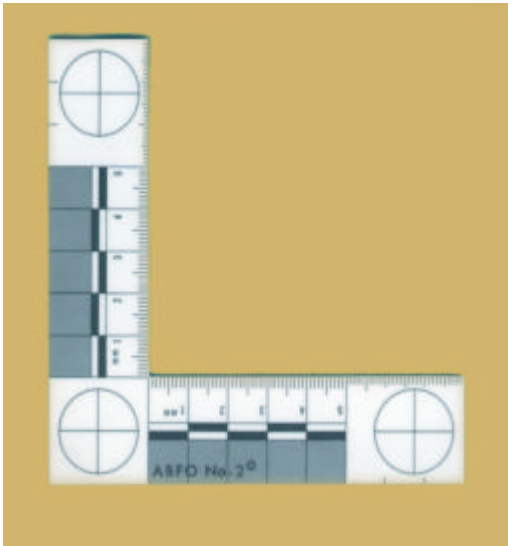


Fig. 2: The ABFO No. 2 scale is an L-shaped millimeter ruler and is widely included in bite marks photographs in order to be able for measurements of the injuries depicted by the photograph. Also accurate enlargements of the photograph can be made

incidence NO metric photographing was made with the use of millimetre scale ABFO No. 2. that is imposed by the Forensic dentistry, so that the evaluation of the natural size of the traumatic damages is possible (Fig. 2). The ability to properly identify suspicious injuries to the head, face, mouth and neck of a child is imperative for dentists.

## DISCUSSION

It is now widely agreed that an absolutely crucial factor in the fight against child abuse is early recognition of the problem so that effective intervention can be undertaken. It has been reported that 35% of children who have been abused will be seriously re-injured, if returned to the parent or guardian without intervention. Indeed, 5% will be killed (Vale, 1997).

According to the report of the Innocenti Research Center of UNICEF in Florence, 3.500 children under 15 years of age are dying each year in the industrialized world because of abuse. Two children are dying every week because of abuse in Germany and Great Britain, 3 in France, 4 in Japan and 24 children are dying every week because of abuse in United States (Report of Innocenti Research Center of UNICEF in Florence, September, 2003). It is important to realize that all dentists have a unique opportunity and ethical obligation-to assist in the

struggle against child abuse. This special opportunity exists because a high proportion of abused children suffer injuries to the face and head including the oral and perioral regions.

It has been found that 23% of head and neck injuries that were not caused by automobile accidents were a result of domestic violence and that 94% of domestic violence victims had head or neck injuries or both (Love *et al.*, 2001). These injuries may be observed during the course of dental treatment and in some cases even before the child is seated in the dental chair.

When a child presents for examination particularly if there is any evidence of severe or repeated trauma involved, the history may alert the dentist to the possibility of a child abuse. Perhaps because crying or speaking emanates from the mouth, this area is frequently the focus of attack in cases of violent child abuse.

## Forms of child abuse

**Physical abuse:** Any physical or mental injury or threatened injury on a child, inflicted by a person responsible for the child's care, other than by accidental means; any physical or mental injury that cannot reasonably be explained by the history of injuries. Physical abuse is the most usual form.

**Sexual abuse:** When a child under 15 years of age is the victim of criminal sexual conduct or threatened criminal sexual conduct by a parent, guardian, caregiver or sibling. When a child is engaged in prostitution or when is the subject of pornographic materials.

**Mental injury-emotional abuse:** Emotional abuse frequently occurs as verbal abuse (constantly yelling at belittling, insulting and criticizing a child) or as excessive demands on a child's performance which result in a negative self-image on the part of the child or disturbed behavior. Emotional abuse also includes the withholding of love and affection. Mental injury, usually the result of emotional abuse is an injury to the psychological capacity or emotional stability of a child as evidenced by an observable or substantial impairment in the child's ability to function within a normal range of performance and behavior with due regard to the child's culture.

**Munchausen syndrome by proxy:** This syndrome describes children which are victims of parentally fabricated or induced illness. These children are usually under 6 years of age and exhibit signs and symptoms fabricated by the parent or the caretaker (Kenney and Spencer, 1995; Rose, 2003; Stavrianos and Metska, 2002).

**Detecting child abuse in the dental office:** When a child presents for examination particularly if there is any evidence of severe or repeated trauma involved, the history may alert the dentist to the possibility of a child abuse. The ability to properly identify suspicious injuries to the head, face, mouth and neck of a child is imperative for dentists. Indeed, the history may be the single most important source of information. Because legal proceedings may follow, the history should be recorded in detail. One should consider abuse or neglect whenever the history reveals the following:

- History of multiple injuries
- The family offers an explanation that is not compatible with the nature of the injury
- Delay in seeking care for the injury
- The family avoids discussing about the injury

The main step in identification of suspected child abuse and neglect (diagnosis) is the general physical assessment of the child, the poor nutritional state and subnormal growth the extraoral injuries while some may be in various stages of healing i.e., bruises or abrasions that reflect the shape of the offending object, burns, bite marks (physical or sexual abuse), bald patches, behavior assessment (Stavrianos, 2009; Vale, 1997; Stavrianos and Metska, 2002; Bakland *et al.*, 1996; Stavrianos and Vasileiadis, 2002). However, a completely extraoral and intraoral examination including visual observation, radiographic studies, manipulation of the jaws, pulp vitality tests and percussion, oral lesions may be noticed i.e., loosened, fractured or avulsed teeth, luxation injuries, darkened and /or nonvital teeth, periapical lesions involving teeth free of caries, previously missing teeth, tears of the labial or lingual frenula, trauma or bruises to the lip, trauma to the tongue or even fractures of jaws and associated structures (Stavrianos, 2009; Vale, 1997; Stavrianos and Metska, 2002; Bakland *et al.*, 1996; Stavrianos and Vasileiadis, 2002). In many cases of child abuse, injuries to the face that may include trauma to the eyes, ears and nose can be noted. Finally, a kind of child abuse or neglect can be noticed after the dental examination (General neglect of the mouth) and the only responsible persons for that are the parents of the child. Dental neglect such as untreated but previously diagnosed dental caries or rampant caries with multiple abscesses are in many jurisdictions are grounds for neglect charges with the appropriate authority (Kenney and Spencer, 1995).

After assessing the child's injuries and determining that child abuse is suspected, detailed documentation should take place, together with radiographs and photographs of the suspicious injuries when necessary

(Kenney and Spencer, 1995). While the importance of reporting suspected cases of child abuse and neglect cannot be overemphasized, the thoughtful practitioner should also consider the other side of the coin (Vale, 1997). When a child's problem is thought to be child abuse and it is not considerable harm may be done to the child, the parents and the doctor-patient relationship (Vale, 1997).

The practitioner should remember that incorrect or irresponsible accusations of child abuse can have a devastating effect upon the life of an innocent individual. Dental professionals can be expected to perform their duty to help protect the children only after receiving appropriate education about their role in identifying and reporting suspected cases of maltreatment. Dentists must become more aware of their moral, legal and ethical responsibilities in recognizing and reporting child abuse and neglect. All dental professionals need to understand the seriousness of the problems of child abuse.

## CONCLUSION

Dentists should be aware that abuse may result in oral or dental injuries so they must be encheaged to be about such findings and their significance, to meticulously observe and document them and institute steps that might save the child's life. As dental health professionals, we are not often thought of as having knowledge in the area of domestic violence physical injury. The comfort level of a given child or parent in dental practice may be such that they will even disclose abuse to you directly. Recognition of child maltreatment is filled with frustration for most health care professionals. The problem with recognition is the initial, awful realization that parents and caregivers do harmful things to defenceless, vulnerable children. All dental professionals need to understand the seriousness of the problems of child maltreatment and realize that children do not just get hurt in abuse and neglect-they often die as a direct result of their maltreatment. Dentistry must do its part to help stop the pain, suffering and death that result from child maltreatment; it has been said that victims of child abuse and neglect fall into only 2 categories-those who lived through and those who did not.

## REFERENCES

- Bakland, L.K., F.M. Andreasen and J.O. Andreasen, 1996. Management of Traumatized Teeth. In: Principles and Practice of Endodontics, Walton, R. and M. Torabinejad (Eds.). 2nd Edn., W.B. Saunders Co., Philadelphia.

- Kenney, J.P. and D.E. Spencer, 1995. Manual of Forensic Odontology. In: DNA and Forensic Odontology, Bowers, C.M. and G.L. Bell (Eds.). American Society of Forensic Odontologists, UK., pp: 191-199.
- Kerani-Koumoutsea, M. and M. Khabbaz, 1987. Orofacial injuries in a fifteen days old abused infant. Proceedings of the 1st European Congress on Child Abuse and Neglect. April 9, Rhodes, Greece.
- Love, C., B. Gerbert, N. Caspers, A. Bronstone, D. Perry and W. Bird, 2001. Dentists attitudes and behaviors regarding domestic violence. JADA, 132: 85-93.
- Rose, D.E., 2003. Family violence: An intervention model for dental professionals. Proceedings of the 3rd European Academy of Forensic Science Meeting, (EAFSM'03), Istanbul, pp: 11-11.
- Spencer, D.E., 2004. Child abuse: Dentist's recognition and involvement. J. Calif. Dent. Assoc., 32: 299-303.
- Stavrianos, C. and L. Vasileiadis, 2002. Forensic Odontology. Computers Service I/O Inc., Greek, pp: 40-45.
- Stavrianos, C. and M.E. Metska, 2002. Dentistry's role in detection and prevention of child abuse and neglect. (In Greek), pp: 82-88.
- Stavrianos, C., 2009. Forensic Dentistry. 1st Edn., Vol. 1-2, University Studio Press, Thessaloniki, pp: 45-98.
- Vale, G.L., 1997. Dentistry's Role in Detecting and Preventing Child Abuse. In: Forensic Dentistry, Stimson, P.G. and C.A. Mertz (Eds.). 1st Edn., CRC Press, Boca Raton, New York, pp: 161-162.