

The Effects of Combined Vitamin C and Vitamin E in Streptozotocin-Induced Diabetic Rat Kidney

¹Aysel Kukner, ²Neriman Colakoglu, ³Candan Ozogul, ⁴Mustafa Naziroglu and ¹Tulin Firat

¹Department of Histology and Embryology, Faculty of Medicine, Abant Izzet Baysal University, Turkey

²Department of Histology and Embryology, Faculty of Medicine, Firat University, Turkey

³Department of Histology and Embryology, Faculty of Medicine, Gazi University, Turkey

⁴Department of Biophysics, Faculty of Medicine, Suleyman Demirel University, Turkey

Abstract: Diabetic nephropathy is a serious complication of diabetes mellitus. Oxidative stress has been suggested to play a key role in the pathogenesis of diabetic nephropathy. Vitamins C and E play important roles in the antioxidant defense system. It is likely that both vitamins act in a synergistic manner, with vitamin E primarily being oxidized to the tocopheroxyl radical and then reduced back to tocopherol by vitamin C. The purpose of the study was to determine the effects of supplementation of Vitamins C and E (VCE) on diabetic rat kidney. Adult female Wistar rats were used in the study. The animals were divided into three groups. Group I: the control group; Group II: diabetic group, streptozotocin (40 mg kg⁻¹) was administered group; Group III: diabetes + VCE group, received a diet containing a combination of ascorbic acid and dl- α -tocopheryl acetate per kg of feed. Rats were killed on 21st day and renal tissues were taken and fixed in 2.5% glutaraldehyde solution for electron microscopic examination. When compared with the control group, congestion of the glomerular capillaries, increased mesangial cells and distinct mesangium, shortened podocyte processes and disappearance of filtration slit pore of diabetic rat kidney were observed. In the group treated with VCE, glomerular changes were less distinct than the diabetic group. Lengths of the pedicles were similar to the control group. VCE reduced the changes in the glomerular structures due to diabetes.

Key words: Diabetes, kidney, vitamin C and E, ultrastructure, renal, tissue, oxidized

INTRODUCTION

Diabetic nephropathy is one of the leading causes of chronic renal failure in the western European countries, USA and Japan. Renal injury is observed in some 35% of patients with type I and II diabetes. Renal disorders observed in type I and II diabetes are similar. Long term hypoglycemia, genetic factors, race, sex and hypertension have been implicated in the development of diabetic nephropathy (Monhart, 2008; Rychlik, 2008). Diabetic nephropathy presents itself with ischemic nephropathy, nodular glomerulosclerosis and renal failure. Clinically, 30-300 mg day⁻¹ or 20-200 μ g min⁻¹ microalbuminuria indicates diabetic nephropathy (Ritz, 2006). Diabetes is an important etiopathological factor in oxidative stress (Punithavathi *et al.*, 2008). As a result of lipid and protein oxidation, the levels of Superoxide Dismutase (SOD), Glutathione Peroxidase (GSH-Px) and Catalase (CAT) increase in kidneys (Prakasam *et al.*, 2005; Je *et al.*, 2001; Yildirim and Buyukbingol, 2003). Various studies have reported protective effects of antioxidants such as

melatonin (Oktem *et al.*, 2006), ginkgobiloba (Welt *et al.*, 2007), Circumin (Murugan and Pari, 2006), Groundnut oil (Ramesh *et al.*, 2006), taurin (Wang *et al.*, 2008), herbal medications (Yokozawa *et al.*, 2008), soybean oil (Sena *et al.*, 2008), naringin, a flavonoid glycoside which gives the bitter taste of grapefruit juice (Punithavathi *et al.*, 2008), vitamin E (Minamiyama *et al.*, 2008; Hamdy *et al.*, 2008; Ruperez *et al.*, 2008) and vitamin C (Ruperez *et al.*, 2008; Wu *et al.*, 2007a; Fadupin *et al.*, 2007) against oxidative damage of diabetes.

The levels of vitamin C and E in plasma and renal tissues are significantly reduced in diabetic patients (Wu *et al.*, 2007b; Kashiba *et al.*, 2002; Peerapatdit *et al.*, 2006). A decrease in Vitamin C causes hyperlipidemia and hypertension (Wu *et al.*, 2007a; Chen *et al.*, 2005). Epidemiologic studies showed that certain fruits and vegetables are important to prevent or alleviate the complications of diabetes and that Vitamins C and E had complication-reducing effects (Harding *et al.*, 2008; Villegas *et al.*, 2008). Vitamins C and E not only reduce the risk of thromboembolism in patients with diabetes-related

hypertension (Haidara *et al.*, 2004) but also exert favorable effects on wound healing (Musalmah *et al.*, 2005). Vitamins C and E have been shown to prevent the teratogenic effects in diabetic rats and autoimmunity of β -cells in babies (Uusitalo *et al.*, 2008; Cederberg and Eriksson, 2005). Vitamins C and E can be used as antioxidants separately or in combination. Both vitamins act synergistically (Naziroglu *et al.*, 2004; Kutlu *et al.*, 2005). Majority of the studies demonstrated the antioxidant effects of Vitamins C and E while electron microscopic studies are scarce. In the present study, the effects of Vitamin C, a hydrophilic antioxidant and Vitamin E, a lipophilic antioxidant, on structural changes in renal tissue were investigated by feeding the experimental diabetes-induced rats with a combination of these vitamins.

MATERIALS AND METHODS

Fifteen adult female Wistar rats weighing 200-220 g were obtained from Experimental Research Center of Firat University Faculty of Medicine (FUTDAM). The rats were housed at 22-24°C and were exposed to alternate cycles of 12 h light and darkness. All animal care and handling procedures conformed to the Guidelines set by the Association for Assessment and Accreditation of Laboratory Animal Care and approval was obtained from the Local Ethics Committee for Animal Studies. The animals were divided into three groups:

Group I: Control group (n = 5). Control rats were given intraperitoneal citrate buffer only (0.1 M, pH = 4.5).

Group II: Diabetic group (n = 5). Streptozotocin (STZ, Serva GmbH, Heidelberg Germany) was administered intraperitoneally at a dose of 40 mg kg⁻¹ body weight dissolved in citrate buffer (29).

Group III: VCE group (n = 5). Rats were fed with VCE (Vitamin C and E) supplemented diet for 15 days prior to induction of diabetes.

VCE supplemented and unsupplemented food compositions were homogenized using a mixer and pellets were prepared in laboratory by heating below 45°C for 2 days. The VCE supplemented diet contained a combination of 1 g vitamin C (ascorbic acid, F. Hoffman La Roche, Istanbul, Turkey) and 600 mg vitamin E (di- α -tocopheryl acetate, F. Hoffman La Roche, Istanbul, Turkey) per kg of feed (Naziroglu *et al.*, 2004).

At the end of the experiment, renal tissues were taken under Rompun (5 mg kg⁻¹) and Ketamin (60 mg kg⁻¹) anesthesia. Renal tissues were fixed in 2.5%

glutaraldehyde in 0.1 M sodium phosphate buffer and postfixed with 2% osmium tetroxide in sodium phosphate buffer. Dehydration was accomplished by gradual ethanol series and tissues were embedded in epoxy resin. Ultrathin sections were stained with Uranyl acetate and lead citrate. Sections were then viewed and photographed with a Zeiss 9 EM.

RESULTS

Thin parts of the renal proximal tubules and glomeruli of the control group looked normal. Podocytes and cytoplasmic extensions, infiltration slits were evenly distributed (Fig. 1).

Capillary congestion, activation of and increase in the number of mesangial cells and shortened podocyte processes were observed in the renal glomeruli secondary to STZ. Basement membrane was thickened in certain regions (Fig. 2a and b). The invaginations on the basal regions of the proximal tubules were irregular and collagen fibers were clustered in the areas between the tubules (Fig. 3). Compared to the control group, mesangial accumulation, shortened podocyte processes and obscured filtration slits could clearly be identified in the diabetic group. Obscureness of the infiltration slits were not diffuse (Fig. 4a and b).

Degeneration of the glomerular endothelia, diffuse or nodular glomerulosclerosis, apoptosis in the podocytes and hyalinization beneath the basal lamina were not observed in this group. Structural changes in the glomeruli of the diabetic rats fed with VCE were milder

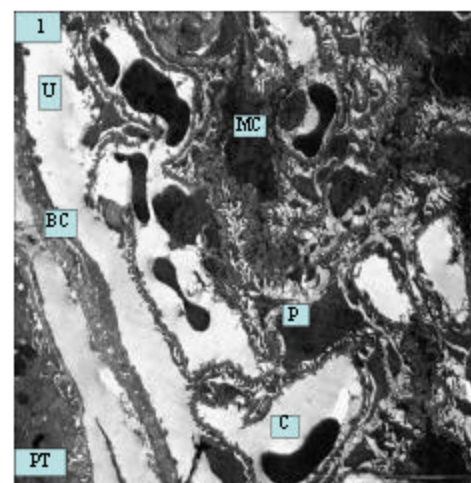


Fig. 1: A glomerulus from the control group. Proximal Tubule (PT), Bowman's Capsule (BC), Capillaries (C), Podocyte (P), Urinary space (U) and Mesangial Cells (MC)

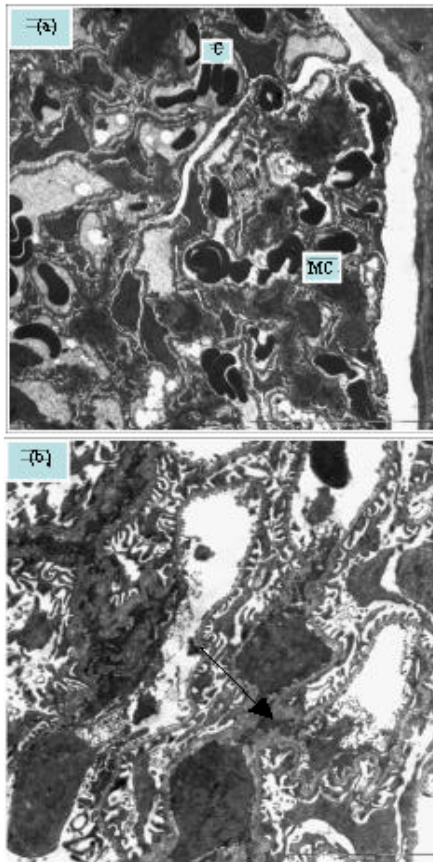


Fig. 2: STZ-induced diabetic rat kidney. a) Capillary congestion and increase in mesangial cells can be observed, b) Occasional basement membrane thickenings can be observed under higher magnification (arrow)

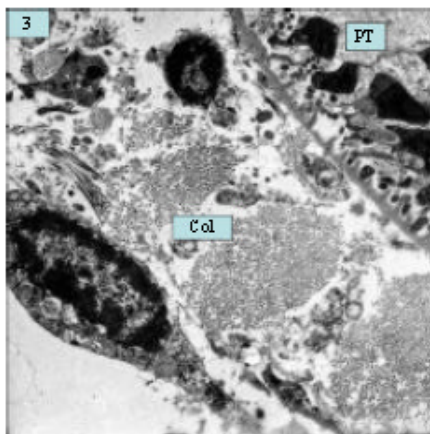


Fig. 3: STZ-induced diabetic rat kidney. Irregular basal invaginations in some of the Proximal Tubules (PT) and peritubular heavy clusters of collagen fibers (Col) can be observed

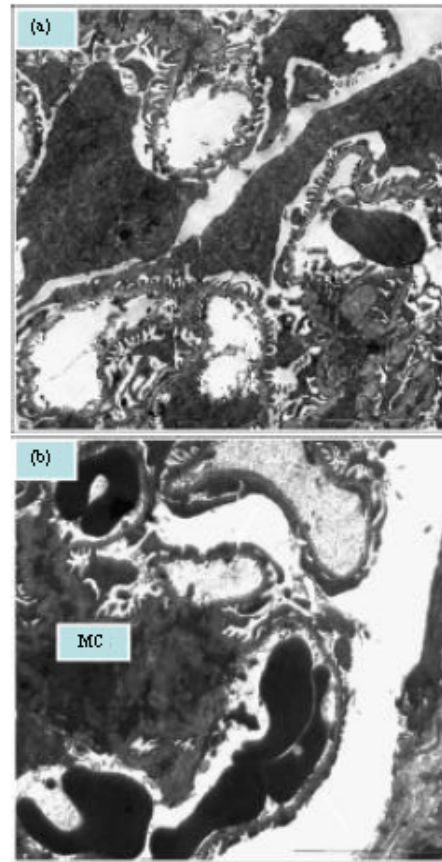


Fig. 4: Comparison of podocyte extensions and infiltration slits. a) Control group, b) Diabetic rat kidney. Shortened podocyte extensions and obscure infiltration slits (arrow) are marked

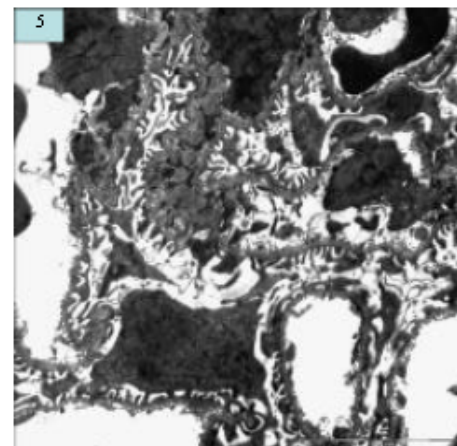


Fig. 5: Rats treated with a combination of vitamins C and E had more intact glomeruli in comparison to the diabetic group and increase in mesangial cell was not noted

than the diabetes group. Increase in mesangial cells was not observed. Podocyte processes and filtration slits generally appeared normal (Fig. 5).

DISCUSSION

Diabetic nephropathy is the most common cause of chronic renal disease and the foremost indication for dialysis and renal transplantation (Estacio and Schrier, 2001). Diffuse or nodular glomerulosclerosis, arteriosclerosis, tubulo-interstitial fibrosis and atrophy occur, proteinuria gradually increases and so does the blood pressure (Alsaad and Herzyenberg, 2007). Glomerulosclerosis develops as a result of injury to the podocytes, which play the key role in glomerular filtration (Lee *et al.*, 2007). Podocyte injury can present itself with two forms: metabolic (biochemical) and hemodynamic (associated with hyperfiltration and hyperperfusion) (Hostetter, 2003; Wolf *et al.*, 2003). Glomerular hyperfiltration and hyperperfusion are essential in mesangialisation and changes in the glomerular basal membrane (Wolf *et al.*, 2003; Menini *et al.*, 2007). In diabetic nephropathy, Prostaglandin E₂ (PGE₂) synthesis in the glomeruli is significantly increased. This is a result of an increase in mesangial cells (Lino *et al.*, 2005). γ -tocopherol inhibits PGE₂ (Peerapatdit *et al.*, 2006; Wu *et al.*, 2007b). Oxidative stress and free oxygen radicals, which develop during nephropathy, trigger apoptosis of the tubular epithelial cells and podocytes of the glomeruli (Blauwkamp *et al.*, 2008; Jung *et al.*, 2008; Ruster *et al.*, 2008; Susztak *et al.*, 2006). Various agents used to inhibit apoptosis have been tried in the treatment of nephropathy (Isermann *et al.*, 2007). In present study, we observed an increase in mesangial cell in the glomeruli of diabetic kidneys and mesangial accumulation but not apoptosis of podocytes and tubular epithelial cells.

Antioxidants are frequently used for diabetes and its complications. Plasma Vitamin C and vitamin E concentrations are reduced in diabetes (Murugan and Pari, 2006; Ramesh *et al.*, 2006; Peerapatdit *et al.*, 2006; Wu *et al.*, 2007a, b; Lee *et al.*, 2007). A positive relation has been demonstrated between high plasma vitamin C level and reduction in complications of diabetes (Harding *et al.*, 2008). Vitamin C plays a central role in the antioxidant protective system, protecting all lipids undergoing oxidation and diminishing the number of apoptotic cells (Sadi *et al.*, 2008; Afkhami-Ardekani and Shojaoadding-Ardekani, 2007; Al-Shamsi *et al.*, 2006). Furthermore, vitamin C regenerates the oxidized vitamin E (Chen *et al.*, 2005). Vitamin E, on the other hand, acts as

a non-enzymatic antioxidant and reduces lipid peroxidation and glutathione (Punithavathi *et al.*, 2008; Minamiyama *et al.*, 2008; Lee *et al.*, 2007). Vitamin E is very effective in glycemic control, lowering the HbA_{1c} levels (Ihara *et al.*, 2000) and preventing the hypertrophic effects of hyperglycemia (Nascimento *et al.*, 2005). However, this is in contrast to the results of some studies, which showed that vitamin E was not beneficial in glycemic control and lipid metabolism in Type II diabetes (Ble-Castillo *et al.*, 2005). In another study, the researchers demonstrated that a combination of vitamins C and E improved the glomerular functions but did not have any effect on the tubular functions (Farvid *et al.*, 2006). When exercise is given to rats with STZ-induced diabetes in addition to Vitamins C and E, it was observed that lipid peroxidation was significantly reduced, Glutathione Peroxidase (GSH-Px) was increased and reduced Glutathione (GSH) level was decreased (Kutlu *et al.*, 2005).

The earliest structural changes in diabetic nephropathy are the increase in mesangial cells and mesangial dilatation. Diffuse thickening of the glomerular basement membrane depends on the severity of the disease. Vitamins C and E reduce the thickness of the basement membrane (Kedziara-Kornatowski *et al.*, 2003; Davila-Esqueda *et al.*, 2005). It has been argued that glomerular changes can occur in diabetic nephropathy without arterial or tubulo-interstitial changes (Fioretto and Mauer, 2007). Vacuolization within the podocytes, myelin figures and blebs were noted (Farvid *et al.*, 2006). In the results, thickening of the glomerular basement membrane was not diffuse but they were in certain regions. Occasional irregularities of the podocyte processes, shortened podocyte processes and obscuration of the infiltration slits were observed.

CONCLUSION

Alterations were not observed in the renal tubules of rats with STZ induced-diabetes while increased mesangial cells, increased capillary permeability and obscuration of the filtration slits were noted in the glomeruli. Neither apoptosis of the podocytes nor thickening of the basement membrane was observed. These alterations were less pronounced in the diabetic rats treated with VCE. VCE helped alleviation of the renal degeneration by protecting the glomerular structures from oxidative injury. Concomitant administration of Vitamins C and E would be more effective in preventing the complications of diabetes.

REFERENCES

- Afkhami-Ardekani, M. and A. Shojaoddin-Ardekani, 2007. Effect of vitamin C on blood glucose, serum lipids and serum insulin type 2 diabetes patients. *Indian J. Med. Res.*, 126: 471-474. PMID: 18160753.
- Alsaad, K.O. and A.M. Herzenberg, 2007. Distinguishing diabetic nephropathy from other causes of glomerulosclerosis: An update. *J. Clin. Pathol.*, 60: 18-26. PMID: 17213346.
- Al-Shamsi, M., A. Amin and E. Adeghate, 2006. Effect of vitamin C on liver and kidney functions in normal and diabetic rats. *Ann. N.Y. Acad. Sci.*, 1084: 371-390. PMID: 17151316.
- Blauwkamp, M.N., J. Yu, M.A. Schin, K.A. Burke, M.J. Berry, B.A. Carlson, F.C. Brosius and R.J. Koenig, 2008. Podocyte specific knock out of selenoproteins does not enhance nephropathy in streptozotocin diabetic C57BL/6 mice. *BMC. Nephrol.*, 9: 7. PMID: 18647412.
- Ble-Castillo, J.L., E. Carmona-Diaz, J.D. Mendez, F.J. Larios-Medina, R. Medina-Santillan, G. Cleva-Villanueva and J.C. Diaz-Zagoya, 2005. Effect of alpha-tocopherol on the metabolic control and oxidative stress in female type 2 diabetics. *Biomed. Pharmacother.*, 59: 290-295. PMID: 15932790.
- Cederberg, J. and U.J. Eriksson, 2005. Antioxidative treatment of pregnant diabetic rats diminishes embryonic dysmorphogenesis. *Birth Defects Res. A Clin. Mol. Teratol.*, 73: 498-505. PMID: 15959875.
- Chen, L., R.H. Jia, C.J. Qiu and G. Ding, 2005. Hyperglycemia inhibits the uptake of dehydroascorbate in tubular epithelial cell. *Am. J. Nephrol.*, 25: 459-465. PMID: 16118484.
- Davila-Esqueda, M.E., A.A. Vertiz-Hernandez and F. Martinez-Morales, 2005. Comparative analysis of the renoprotective effects of pentoxifylline and vitamin E on streptozotocin-induced diabetes mellitus. *Ren Fail.*, 27: 195-207. PMID: 15717644.
- Estacio, R.O. and R.W. Schrier, 2001. Diabetic nephropathy; pathogenesis, diagnosis and prevention of progression. *Adv. Int. Med.*, 46: 359-408. PMID: 11147259.
- Fadupin, G.T., A.U. Akpoqhar and K.A. Okunade, 2007. Comparative study of serum ascorbic acid level in people with and without type 2 diabetes in Ibadan Nigeria. *Afr. J. Med. Med. Sci.*, 36: 335-339. PMID: 18564649.
- Farvid, M.S., M. Jalali, F. Siassi and M. Hosseini, 2006. Comparison of the effects of vitamins and/or mineral supplementation on glomerular and tubular dysfunction in type 2 diabetes. *Diabetes Care*, 29: 747-748. PMID: 16186280.
- Fioretto, P. and M. Mauer, 2007. Histopathology of diabetic nephropathy. *Semin Nephrol.*, 27: 195-207. PMID: 17418688.
- Haidara, M.A., H. Khloussy, H. Ammar and L.A. Aal Kasem, 2004. Impact of alpha-tocopherol and vitamin C on endothelial markers in rats with streptozotocin-induced diabetes. *Med. Sci. Monit.*, 10: BR41-46. PMID: 14737039.
- Hamdy, N.M., S.M. Suwailem and H.O. El-Mesallamy, 2008. Influence of vitamin E supplementation on endothelial complications in type 2 diabetes mellitus patients who underwent coronary artery bypass graft. *J. Diabetes Complications*, 23: 167-173. PMID: 18413198.
- Harding, A.H., N.J. Wareham, S.A. Bingham, K. Khaw, R. Luben, A. Welch, N.G. Forouhi, 2008. Plasma vitamin C level, fruit and vegetable consumption and the risk of new-onset type 2 diabetes mellitus: The European prospective investigation of Cancer-Norfolk prospective study. *Arch. Int. Med.*, 168: 1485-1486. PMID: 18663161.
- Hostetter, T.H., 2003. Hyperfiltration and glomerulosclerosis. *Semin Nephrol.*, 23: 194-199.
- Iino, K., M. Iwase, K. Sonoki, M. Yoshinari and M. Iida, 2005. Combination treatment of vitamin C and desferrioxamine suppresses glomerular superoxide and prostaglandin E production in diabetic rats. *Diabetes Obes Metab.*, 7: 106-109. PMID: 12704579.
- Ihara, Y., Y. Yamada, S. Toyokuni, K. Miyowaki, N. Ban, T. Adachi, A. Kurae, T. Iwakuru, A. Kubota, H. Hiai and Y. Seino, 2000. Antioxidant alpha-tocopherol ameliorates glycemic control of GK rats, a model of type 2 diabetes. *FEBS Lett.*, 473: 24-26. PMID: 10802052.
- Isermann, B., I.A. Vinnikov, T. Madhusudhan, S. Herzog, M. Kashif and J. Blautzik, 2007. Activated protein C protects against diabetic nephropathy by inhibiting endothelial and podocyte apoptosis. *Nat. Med.*, 13: 1349-1358. PMID: 17982464.
- Je, H.D., C.Y. Shin, H.S. Park, I.H. Huh and U.D. Sohn, 2001. The comparison of vitamin C and vitamin E on the protein oxidation of diabetic rats. *J. Auton. Pharmacol.*, 21: 231-236. PMID: 12123467.
- Jung, D.S., J.J. Li, S.J. Kwak, S.H. Lee, J. Park, Y.S. Song, T.H. Yoo, S.H. Han, J.E. Lee, D.K. Kim, S.J. Moon, Y.S. Kim, D.S. Han and S.W. Kang, 2008. FR167653 inhibits fibronectin expression and apoptosis in diabetic glomeruli and in high-glucose-stimulated mesangial cells. *Am. J. Physiol. Renal Physiol.*, 295: F595-604. PMID: 18524857.
- Kashiba, M., J. Oka, R. Ichikawa, E. Kasahara and T. Inayama, 2002. Impaired ascorbic acid metabolism in streptozotocin-induced diabetic rats. *Free Radic. Biol. Med.*, 33: 1221-1230. PMID: 12398930.

- Kedziara-Kornatowski, K., S. Szram, T. Karnatowski, L. Szadujkis-Szadurski, J. Kedziora and G. Bartosz, 2003. Effect of vitamin E and vitamin C supplementation on antioxidative state and renal glomerular basement membrane thickness in diabetic kidney. *Nephron Exp. Nephrol.*, 95: e134-43. PMID: 14 694267
- Kutlu, M., M. Nazioglu, H. Simsek, T. Yilmaz and A.H. Kukner, 2005. Moderate exercise combined with dietary vitamins C and E counteracts oxidative stress in the kidney and lens of streptozotocin-induced diabetic rat. *Int. J. Vitam Nutr. Res.*, 75: 71-80. PMID: 15830924.
- Lee, E.Y., M.Y. Lee, S.W. Honq, C.H. Chunq and S.Y. Honq, 2007. Blockade of oxidative stress by vitamin C ameliorates albuminuria and renal sclerosis in experimental diabetic rats. *Yonsei Med. J.*, 48: 847-55. PMID: 17963344.
- Menini, S., C. Iacobini, G. Oddi, C. Ricci, P. Simonelli, S. Fallucca, M. Grattarola, F. Peqliese, C. Pesce and G. Peqliese, 2007. Increased glomerular cell (podocyte) apoptosis in rats with streptozotocin-induced diabetes mellitus: Role in the development of diabetic glomerular disease. *Diabetologia*, 50: 2591-2599. PMID: 17901943.
- Minamiyama, Y., S. Takemura, Y. Bito, H. Shinkawa, T. Tsukioka, A. Nakahira, S. Suehiro and S. Okada, 2008. Supplementation of alpha-tocopherol improves cardiovascular risk factors via the insulin signaling pathway and reduction of mitochondrial reactive oxygen species in type II diabetic rats. *Free Radic. Res.*, 42: 261-271. PMID: 18344121.
- Monhart, V., 2008. Diabetes mellitus, hypertension and kidney. *Vnitr Lek*, 54: 499-504. PMID: 18630636.
- Murugan, P. and L. Pari, 2006. Antioxidant effect of tetrahydrocurcimin in streptozotocin-nicotinamide induced diabetic rats. *Life Sci.*, 79: 1720-1728. PMID: 16806281.
- Musalmah, M., M.Y. Nizrana, A.H. Fairuz, A.H. Noor Aini, A.L. Azian, M.T. Gapor and W.Z. Wan Ngah, 2005. Comparative effects of paim vitamin E and α -tocopherol on healing and wound tissue antioxidant enzyme levels in diabetic rats. *Lipids*, 40: 575-580. PMID: 16149736.
- Nascimento, G.G., F.T. Barbosa, R.F. Radaeli, M.F. Cavaral, M. Mello Aires and F. Zaladek Gil, 2005. Effect of D-alpha-tocopherol on tubular nephron acidification by rats with induced diabetes mellitus. *Braz. J. Med. Biol. Res.*, 38: 1043-1051. PMID: 16007 275.
- Naziroglu, M., M. Simsek, H. Simsek, N. Aydilek, Z. Ozcan and R. Atilgan, 2004. The effects of hormone replacement therapy combined with vitamins C and E on antioxidants levels and lipid profiles in postmenopausal women with type 2 diabetes. *Clin. Chem. Acta*, 344: 63-71. PMID: 15202787.
- Oktem, F., F. Ozguner, H.R. Yilmaz, E. Uz and B. Dundar, 2006. Melatonin reduces urinary excretion of N-acetyl-beta-D-glucosaminidase, albumin and renal oxidative markers in diabetic rats. *Clin. Exp. Pharmacol. Physiol.*, 33: 95-101. PMID: 16445706.
- Peerapatdit, T., N. Patchanans, A. Likidilid, S. Poldee and C. Sriratanasathavorn, 2006. Plasma lipid peroxidation and antioxidant nutrients in type 2 diabetic patients. *J. Med. Assos. Thai*, 89 (Suppl. 5): 5147-5155. PMID: 17718255.
- Prakasam, A., S. Sethupathy and K.V. Puqalendi, 2005. Antiperoxidative and antioxidant effects of casearia esculenta root extract in streptozotocin-induced diabetic rats. *Yale J. Biol. Med.*, 78: 15-23. PMID: 161 97726.
- Punithavathi, V.R., R. Anuthama and P.S. Prince, 2008. Combined treatment with naringin and vitamin C ameliorates streptozotocin-induced diabetes in male Wistar rats. *J. Appl. Toxicol.*, 28: 806-813. PMID: 183 44197.
- Ramesh, B., R. Saravanan and K.V. Pugalendi, 2006. Effect of dietary substitution of Groundnut oil on blood glucose, lipid profile and redox status in streptozotocin-diabetic rats. *Yale J. Biol. Med.*, 79: 9-17. PMID: 17876371.
- Ritz, E., 2006. Diabetic nephropathy. *Saudi J. Kidney Dis. Trans.*, 17: 481-490. PMID: 17186681.
- Ruperez, F.J., D. Garcia-Martinez, B. Baera, N. Maeso, A. Cifuentes, C. Barbas and E. Herrera, 2008. Evolution of oxidative stress parameters and response to oral vitamins E and C in streptozotocin-induced diabetic rats. *J. Pharm. Pharmacol.*, 60: 871-878. PMID: 1854 9673.
- Ruster, C., T. Bondeva, S. Franke, M. Forster and G. Wolf, 2008. Advanced glycation end-products induce cell cycle arrest and hypertrophy in podocytes. *Nephrol. Dial Trans.*, 23: 2179-2191. PMID: 18344241.
- Rychlik, I., 2008. Epidemiology of diabetic nephropathy. *Vnitr Lek*, 54: 488-493. PMID: 18630634.
- Sadi, G., O. Yilmaz and T. Guray, 2008. Effect of vitamin C and lipoic acid on streptozotocin-induced diabetes gene expression: mRNA and protein expressions of Cu-Zn SOD and catalase. *Mol. Cell. Biochem.*, 309: 109-116. PMID: 18008141.

- Sena, C.M., T. Proenca, E. Nunes, M.S. Santos and R.M. Seica, 2008. The effect of soybean oil on glycaemic control in Goto-Kakizaki rats, an animal model of type 2 diabetes. *Med. Chem.*, 4: 293-297. PMID: 18473922.
- Susztak, K., A.C. Raff, M. Schilffer, E.P. Bottinger, 2006. Glucose-induced reactive oxygen species cause apoptosis of podocytes and podocyte depletion at the onset of diabetic nephropathy. *Diabetes*, 55: 225-233. PMID: 16380497.
- Uusitalo, L., J. Nevalainen, S. Niinistu, G. Alfthan and J. Sandvall, 2008. Serum alpha and gamma-tocopherol concentrations and risk of advanced beta cell autoimmunity in children with HLA-conferred susceptibility to type 1 diabetes mellitus. *Diabetologia*, 51: 773-780. PMID: 18317723.
- Villegas, R., X.O. Shu, Y.T. Gao, G. Yang, T. Elasy, H. Li and W. Zhenq, 2008. Vegetable but not fruit consumption reduces the risk of type 2 diabetes in Chinese women. *J. Nutr.*, 138: 574-580. PMID: 18287369.
- Wang, L., L. Zhang, Y. Yu, Y. Wang and N. Niu, 2008. The protective effects of taurine against early renal injury in STZ-induced diabetic rats, correlated with inhibition of renal Lox-1 mediated ICAM-1 expression. *Ren Fail*, 30: 763-771. PMID: 18791949.
- Welt, K., J. Weiss, R. Martin, T. Hermsdorf, S. Drews and G. Fitzi, 2007. Ginkgobiloba extract protects rat kidney from diabetic and hypoxic damage. *Phytomedicine*, 14: 196-203. PMID: 16781853.
- Wolf, G., U. Butzmann and U.O. Wenzel, 2003. The renin-angiotensin system and progression of renal disease: From hemodynamics to cell biology. *Nephron Physiol.*, 93: 3-13. PMID: 12411725.
- Wu, J.H., N.C. Ward, A.P. Indrawan, C.A. Almeida, J.M. Hodgson, J.M. Porudfoot, I.B. Puddey and K.D. Croft, 2007a. Effect of α -tocopherol and mixed tocopherol supplementation on markers of oxidative stress and inflammation in type 2 diabetes. *Clin. Chem.*, 53: 511-519. PMID: 17272491.
- Wu, X., T. Iguchi, J. Hiranoj, I. Fujita, H. Ueda, N. Itoh, K. Tanaka and T. Nakahishi, 2007b. Upregulation of sodium-dependent vitamin C transporter 2 expression in adrenals increases norepinephrine production and aggravates hyperlipidemia in mice with streptozotocin-induced diabetes. *Biochem. Pharmacol.*, 74: 1020-1028. PMID: 17689499.
- Yildirim, O. and Z. Buyukbingol, 2003. *In vivo* effect of vitamin C with cobalt on oxidative stress in experimental diabetic rat kidney. *Diabetes Nutr. Metab.*, 16: 208-213. PMID: 14768769.
- Yokozawa, T., N. Yamabe, H.Y. Kim, K.S. Kang, J.M. Hur, C.H. Park and T. Tanaka, 2008. Protective effects of Morroniside isolated from Corni Fructus against renal damage in streptozotocin-induced diabetic rats. *Biol. Pharm. Bull.*, 31: 1422-1428. PMID: 18591786.