

Gutta Percha Root Filling in 2nd Primary Molar Teeth with Missing Successor: A Challenging Approach

G. Ansari and Mirkarimi

Department of Paedodontics, Dental School, Shahid Beheshti Medical University, Tehran, Iran

Abstract: After the third molar, congenitally missing of second premolars has the highest incidence. Endodontic treatment of second primary molars is therefore, of prim importance for a longer lasting tooth. The aim of this article was to look at the potential improvement and longevity of 2nd primary molar root canal therapy using Gutta percha when missing successors. A 9 year old male patient was attended to the Department of Pedodontics, Shahid Beheshti University, for routine check up. There was no report of any medical problem in his history. Radiographic investigation of the case using an OPG revealed the missing of both lower 5's. This was while both mandibular 2nd primary molars were carious involving pulp. All carious tissues were removed followed by an opening into the pulp chamber under local anesthesia and rubber dam isolation. The inflamed and hyperemic pulp was removed as routine, irrigated, dried ready for root filling. All three root canals were then dressed temporarily using a cotton pellet placed in to the pulp chamber covered with reinforced ZOE. Each root of the treating teeth was then obturated in the second visit using Gutta-percha and ZOE sealer through the lateral condensation technique. Radiographs were obtained before, immediately after and in 6 month follow up to assess the periapical as well as forcation of the teeth. Second primary molars with missing successors tend to stay intact in a longer period when treated with Gutta Perchae root filling compare to Pure ZOE paste as they would not resorbe quickly.

Key words: Primary molar, missing, second premolar, root filling

INTRODUCTION

The second premolar has the highest incidence (5%) of congenital absence after the third molar (22%) (Biggerstaff, 1992; Thompson *et al.*, 1974). This problem is more highlighted by the need to save primary teeth with treatment that yield a more reliable result over the long term. At present, such cases are managed through two options of extracting primary second molar and allowing the permanent first molar to drift mesially with a final orthodontic correction or maintaining the deciduous tooth until the patient is old enough for the implant or any prosthetic solution (Valencia *et al.*, 2004). It is well acknowledged that most of the cases with uncontrolled tooth extraction will lead to arch length discrepancy and space loss. This would in turn require a longer period of orthodontic treatment in order to push the first molar back and provide sufficient space for implant placement (Kokich and Kokid, 2006). Therefore, it's advised to maintain the second primary molar in case of a missing successor (Pinkham and Casamassimo, 2005). Pulpectomy is indicated in primary teeth with carious pulp exposure in

which following coronal pulp amputation, the radicular pulp exhibits clinical signs of hyperemia, or evidence of necrosis of the radicular pulp (Macdonald *et al.*, 2004). The procedure is considered successful if the tooth is not mobile, remains in function without pain, discomfort or infection with no signs of fistula, bone resorption and widening of periodontal ligament space. It should also be noted that root canal filling is contra indicated in teeth with un restorable crowns, reduced bone support with sever tooth mobility, perforations, internal or external root resorption, radiographic signs of follicles involvement and certain medically compromised patients (Pinkham and Casamassimo, 2005; Macdonald *et al.*, 2004; Moskovitz *et al.*, 2005). To date, several root canal filling materials have been introduced for primary teeth including: zinc oxide eugenol (ZOE), Kri paste, Maisto paste, vitapex, Endoflas and more recently MTA and CEM (Pinkham *et al.*, 2005; Macdonald *et al.*, 2004; Torabinejad *et al.*, 1993; Matt *et al.*, 2004; Asgary *et al.*, 2006). It has also been suggested by several studies that second primary molars with congenital missing successors could well be treated

endodontically using Gutta percha obturation (Cohen and Hargreaves, 2006). This study will look at the potential success of Gutta Perchae as root filling material for a pair of 2nd primary mandibular molar teeth with missing successors using standard clinical and radiographic criteria.

CASE REPORT

A 9 year old male patient was referred to the Department of Pedodontics, Shahid Beheshti University, Dental school for advice on missing 5's of his mandible. There was no trace of any medical problems in his history. Oral examination showed the presence of following teeth:

6 E D C B 1	1 B C D E 6
E C 2 1	1 2 C D E 6

There were several carious teeth including the lower E's. Radiographic evaluation of the case revealed that the lower second premolars as being congenitally missing. As stated before the second primary molar teeth were showing signs of extensive occlusal caries with no reference to pain (Fig. 1). Radiographic examination revealed proximity of the cavities to the pulp, indicating some degree of pulp involvement. There were no signs of internal or external root resorption with only a furcation radiolucency being picked up at right side second primary molar (Fig. 2).

Both teeth were observed as partial necrosis when opened for initial steps of pulp treatment. Patient had represented no space deficiency with a thorough assessment. Root canal treatment was conducted in 2 visits. All carious tissues were removed followed by an opening in to the pulp chamber under a local anesthetic and rubber dam isolation. The inflamed and necrotic tissue of the pulp was then removed while the root canal was being under routine chemo-mechanical preparation using a series of 21 mm long K type endodontic files. Working length was estimated by periapical radiographs as routine. Attempts were made to prevent any over reading of the length, though preventing over filling. Root canals were then irrigated with sodium hypochlorite and saline and dried using fine paper point according to the canal's master file size. A cotton pellet was then placed in to the pulp chamber covered with reinforced ZOE as temporary filling. Each tooth was then obturated in the second visit using Gutta percha and ZOE sealer through the lateral condensation technique with minimal tight back. Stain less Steel Crown (SSC) was placed on each tooth as crown restoration. Patient was then called for the 1st check up in one month (Fig. 3). A 6 month recall was

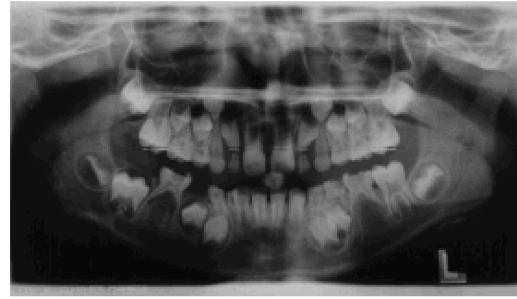

Fig. 1: Ortho Panthomo Graph showing carious molar teeth with the absence of successor premolars (5's) in Mandibular arch

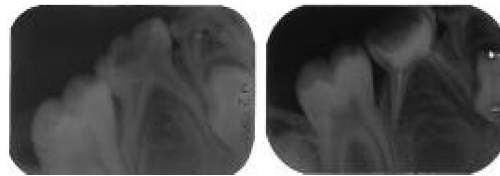


Fig. 2: (a,b) Apical Radiographs of the teeth (both sides) following gutta percha root filling

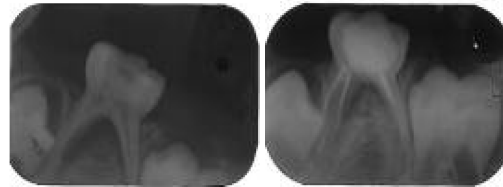


Fig. 3: Treated teeth in 6 month review showing no pathologic sign in Peri radicular area

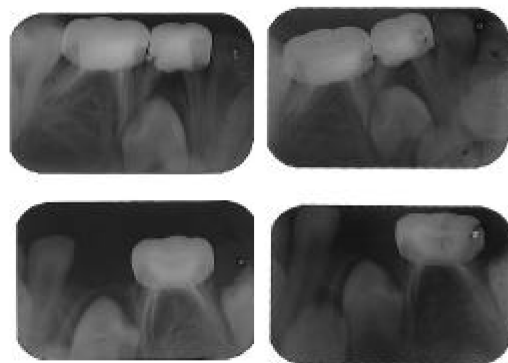


Fig. 4: Treated teeth in 12 month review showing no pathologic sign in periradicular area

performed in which the root treated teeth underwent a careful clinical and radiographic evaluation by two pediatric dentists. Patients had reported no complaint and treated teeth represented no clinical sign of a problem at

6 month review. This was while radiographic evaluation showed signs of improvement areas with lucency and normal condition elsewhere. A further 12 month evaluation of the case showed no pathologic sign or symptom indicating favorable success of the case. Complications such as signs of fistula, bone resorption, periodontal ligament widening and pain were carefully looked up in these two teeth separately with no trace being detectable (Fig. 4).

DISCUSSION

The most common congenitally missing permanent teeth are third molars, second premolars and lateral incisors in their order of frequency (Symons, 1993; Suprabha and Pai, 2006). Based on the literature on the prevalence of missing 5's, demand is set on preservation of the relevant primary molars (Pinkham and Casamassimo, 2005). It has long been suggested to use Pure ZOE pastes as the material of choice for root filling of primary teeth in order to give the chance of absorption of the material by the patient's defense mechanism following physiologic root resorption (Pinkham *et al.*, 2005). However, this is not the case when a subsiding tooth is missing. As mentioned earlier, 2nd premolar is the most frequent tooth after third molar indicating its important place in occlusion. Of course root treatment in primary teeth with missing successor is critically important to enable its preservation in a longer period than routinely expected. To date, most clinicians have been using different components of ZOE for this purpose alone. This has led to several failures due to numerous reasons including poor applicability, visibility, wash ability and lack of seal. In such condition a material capable of eliminating all such deficiencies is needed to achieve a more appropriate result. There have been several studies testing different materials including the conventional Gutta Percha (Cohen and Hargreaves, 2006). The concern over the difficulty caused by resorption of the root and problems following extraction of primary tooth will no longer exist as these teeth are not going to undergo any resorption soon. It is also believed that such more permanent treatment will reduce the remaining potential of resorption. One of major purposes of this is to maintain the space until the patient could receive more advanced treatments such as implants and prosthetics. This is provided if the crown restoration of severely carious primary tooth is performed using SSC following endodontic treatment (Pinkham *et al.*, 2005).

While, continues resorption of the material along with the root canal resorption is considered as the main advantage of the current root canal filling materials such as ZOE and Kri paste used in routine pulpectomy

procedures of primary teeth concerns over its disappearance from the canal remains. That is why it could be considered as a disadvantage when a primary tooth is supposed to remain longer and the filling material is expected to last that long too. Several investigations reported the complication and failure of root filling due to the use of routine materials in such cases with a later disappearance of material in absence of root resorption leaving the root canal with no medicaments for long time (Moskovitz *et al.*, 2005; Holan and Fuks, 1993). The physiologic resorption of the deciduous molars without the second premolar occurs at an average age of 22 years, 10 years later than normal exfoliation time estimate. This is considered, therefore as the best time for an implant replacement (Valencia *et al.*, 2004). Longer term follow ups have revealed that if the retained primary tooth is left with an empty root canal and no resorption or other pathologies, it will become ankylosed and will appear to be submerged (Bjerklin and Bennett, 2000). It is of note that the use of newly developed materials in endodontics including Mineral Trioxide Aggregate (MTA) and a more recently developed material called Calcium Enriched Mixture (CEM) Application of these materials in minimally filed and shaped roots of primary teeth are yet to be proved by well designed and followed clinical research considering child's lowered level of co-operation. These materials have, however been successfully tested for Pulp capping primary teeth and even vital pulpotomies. A long term study on this direction has been set to compare these materials suitability for pulpotomy of primary teeth (Torabinejad *et al.*, 1993; Asgary *et al.*, 2006; Ansari and Ranjpoor, 2008). Due to their resistance against resorption their use in routine pulpectomy of primary teeth is abandoned while in the cases where preservation of primary molar is in line such materials could be reconsidered for use.

CONCLUSION

It seems that the use of Gutta Percha point along with the ZOE mixture would enhance the roots of primary molars with missing successors to remain healthy and intact. Further long term and comparative studies are suggested to more clarify this suggestion.

REFERENCES

- Ansari, G. and M. Ranjpoor, 2008. Comparing the success rate of MTA and FC in pulpotomy of primary molar teeth, *in vivo*. Int. Endod. J. (In Press).
- Asgary, S., M. Parirokh and M.J. Eghbal, 2006. SEM evaluation of pulp reaction to different pulp capping materials in dog's teeth. Iran. Endod. J., 4: 117-123.

- Biggerstaff, R.H., 1992. The orthodontic management of congenitally absent maxillary lateral incisors and second premolars: A case report. *Am. J. Orthod Dentofacial Orthop.*, 102: 537-545.
- Bjerklin, K. and J. Bennett, 2000. Long term survival of lower second deciduous molars in subjects with agenesis of the premolars. *Eur. J. Orthod.*, 22: 245-255.
- Cohen, S. and K.M. Hargreaves, 2006. Pathways of the Pulp. 9th Edn. The CV Mosby Co, 22: 862.
- Holan and A.B. Fuks, 1993. A comparison of pulpectomies using ZOE and KRI in primary molars: A retrospective study. *Pediatr. Dent.*, 15: 249-253.
- Kokich, V.G. and V.O. Kokich, 2006. Congenitally missing mandibular second premolars: Clinical options. *Am. J. Orthod. Dentofacial Orthop.*, 130: 437-444.
- Macdonald, R.E., D. Avery and J. Dean, 2004. Dentistry for the Child and Adolescent. 8th Edn. The CV Mosby Co, pp: 400-406.
- Matt, G.D., J.R. Thorpe, J.M. Strother and S.B. Mc Clanahan, 2004. Comparative study of white and gray mineral trioxide aggregate (MTA) simulating a one or two step apical barrier technique. *J. Endod.*, 30: 876-879.
- Moskovitz, M., E. Sammara and G. Holan, 2005. Success rate of root canal treatment in primary molars. *J. Dent.*, 33: 41-47.
- Pinkham, J.R. and P.S. Casamassimo, 2005. *Fields Pediatric Dentistry; Infancy Through Adolescence*. 4th Edn. Elsevier Publications Chaps., 21, 22, 35: 623-624, 358, 388.
- Suprabha, B.S. and S.M. Pai, 2006. Ankylosis of primary molar along with congenitally missing first permanent molar. *J. Indian Soc. Pedod Prev. Dent.*, 24: 35-37.
- Symons Al, 1993. Anomalies associated with hypodontia of the permanent lateral incisor and second premolar. *J. Clin. Pediatr. Dent.*, 17: 109-111.
- Thompson, G.W., F. Popovich and D.L. 1974. Anderson, Third molar agenesis in the Burlington Growth Centre in Toronto. *Community Dent. Oral. Epidemiol.*, 2: 187-92.
- Torabinejad, M., T.F. Watson and T.R. Pitt Ford, 1993. Sealing ability of a Mineral Trioxide Aggregate when used as a root end filling material. *J. Endod.*, 19: 591-595.
- Valencia, R., M. Saadia and G. Grinberg, 2004. Controlled slicing in the management of congenitally missing second premolars. *Am. J. Orthod. Dentofacial. Orthop.*, 125: 537-543.