

## The Effect of Balm's Hydro Alcoholic Extract on Activity of Liver Enzymes and Liver Tissue

<sup>1</sup>Safieh Golkhani, <sup>2</sup>Mehrdad Modaresi and <sup>1</sup>Mehran Majlesi

<sup>1</sup>Department of Biology, Islamic Azad University, Falavarjan Branch, Falavarjan, Iran

<sup>2</sup>Department of Animal Science, Islamic Azad University, Khorasgan Branch, Isfahan, Iran

**Abstract:** Balm (*Melissa officinalis*) is a fragrant plant from Lamiaceae family which has many medical properties including relaxing, anti oxidant and anti bacterial. This study was conducted to investigate the effect of hydro alcoholic extract of balm on activity of liver enzymes including AST, ALT and ALP and also liver tissues variation in Balb/C mice. Samples were randomly divided into five groups (three treatment groups, placebo and control group) with eight members in each group. Groups were kept under similar conditions. Hydro alcoholic extract was prepared in three doses (50, 100 and 200 mg kg<sup>-1</sup>) and were IP for 20 days. Normal saline was used for placebo group. After the last injection blood samples were taken and liver tissues were separated. Changes of AST, ALT and ALP enzymes was evaluated using one way variance analysis and SPSS program (p<0.05). Tissue changes of liver were studied using coloring with H&E technique. According to results, ALT and ALP enzyme was increased (p<0.05) in 200 mg kg<sup>-1</sup> dose. Hepatocytes number and histology of liver did not show significant variations. On the whole, hydro alcoholic extract of balm could have conservative effects via reducing ALT and ALP enzymes and no harmful effects on liver tissue. So, it can play an important role in preventing and curing diseases in traditional and also current medicine.

**Key words:** Balm, liver enzymes, liver tissue, mice, Iran

---

### INTRODUCTION

Liver tissue is ready to wide range of harmful effects of alcohol drinking, drugs and infections like viral hepatitis, cancer and other disease (Stout, 1999). In primary stages of liver injuries (before immune system responding), the patient does not feel any pain, therefore this disease is called silent disease and patient may not have physical symptoms while liver tissue is hurting (Sallie *et al.*, 1991). So, the first step for diagnosing liver injuries is doing experiments for measuring level of liver enzymes.

Balm is a fragrant, vegetative perennial plant from Magnoliopsida class, Lamiales order, Lamiaceae family and *Melissa* genus (Zargari, 1995). Lemon smell is from properties of this plant and it is sometimes called lemon balm too (Lamaison *et al.*, 1991). The most common therapeutic properties of balm can be sedating, antioxidant, antispasmodic, carminative, anti-bacterial, anti-viral and anti-inflammatory properties (Yousefi *et al.*, 2011; Lamaison *et al.*, 1991). Identified compounds of balm are some of monoterpenoid aldehydes, flavonoid, polyphenolic compounds especially rosmarinic acid and monoterpene glycosides (Carnat *et al.*, 1998; Hohmann *et al.*, 1999). The essence of this plant is

anti-spasm and relaxing (Ghayour *et al.*, 2012). Balm is useful in treating childhood colic (Weizman *et al.*, 1993), eliminating chronic asthma, influenza and ague (Agata *et al.*, 1993), memory enhancing and improving Alzheimer (Bennett, 2003). Probable effects of hydroalcoholic extract of Balm on liver enzymes and tissue was investigated in this study.

### MATERIALS AND METHODS

Forty mice from Balb/C race with 25-30 g weight from the same age range were divided randomly in five groups including control, placebo and three treatment groups (50, 100 and 200 mg kg<sup>-1</sup>). Groups were kept under similar conditions (22-26°C temperature, 40-60% humidity and usual light cycle) for 14 days with free access to water and food. Plant samples were selected from young healthy plants without disease and deficits symptoms. Aerial parts of plant were separated, washed completely, dried and doses 50, 100 and 200 mg were prepared. Obtained extract was injected for 20 days every other day. Normal saline was used to inject to placebo group and control group was not injected. About 1 day after last injection blood samples were prepared using guillotine method and were poured in heparinized tubes. At last, liver tissues

were separated and kept in formalin (10%). Blood samples were centrifuged for 20 min ( $4000 \text{ cycle min}^{-1}$ ) and plasma was separated. Activity of serum aminotransferases including alanine-aminotransferase, aspartate-aminotransferase and alkaline phosphatase were evaluated using kits. Also, tissue samples were prepared using H&E Method. Obtained data were analyzed using one way variance analysis of SPSS program and mean comparisons were done using Duncan's multiple range test.

## RESULTS AND DISCUSSION

According, to results AST was increased non significantly with increase in dose which is obvious but this increase was more in 100 mg group than the other groups and control had the least amount. The amount of ALT and ALP were decrease significantly ( $p < 0.05$ ) in 200 mg  $\text{kg}^{-1}$  group (Fig. 1).

Microscopic study of liver tissue show that there were no significant differences between studied groups and balm extract did not cause any tissue destruction (Fig. 2). By injecting 50 mg  $\text{kg}^{-1}$  of extract lobules boundaries were faded highly, Hepatocytes (H) were became larger and more clear, Central Veins (CV) were obvious completely and hepatocytes of lobules central parts were more clear and bigger than marginal parts.

Also, studies showed that by injecting 100 mg  $\text{kg}^{-1}$  of extract Central Veins (CV) became a little wider and Hepatocytes (H) around them or hepatocytes of lobules centers have become bigger. By injecting 200 mg  $\text{kg}^{-1}$  of extract Central Veins (CV) became wider and also were changed in figure so that they have lost their typical global shape and became oval and even irregular. Statistical results showed that the highest number of hepatocytes were obtained min 200 mg  $\text{kg}^{-1}$  of extract whereas control group had the least number but the difference was not significant.

Results showed that Aspartate aminotransferase (AST) amount was increased non significantly in experimental groups. Also, Alanin aminotranferase (ALT) amount was decreased in treatment groups especially in last group (200 mg  $\text{kg}^{-1}$ ) which reduction was significant ( $p < 0.05$ ) in this group. Activity of alkaline phosphatase was different in various doses which in 200 mg  $\text{kg}^{-1}$  it was reduced significantly. Previous studies show that aminotransferase catalyze the chemical reactions in cells which an amino group is transferred from a donor molecule to a recipient molecule. AST is naturally located in various tissues like liver, heart, muscles, kidney and brain. This enzyme enters to blood at the time of injury to

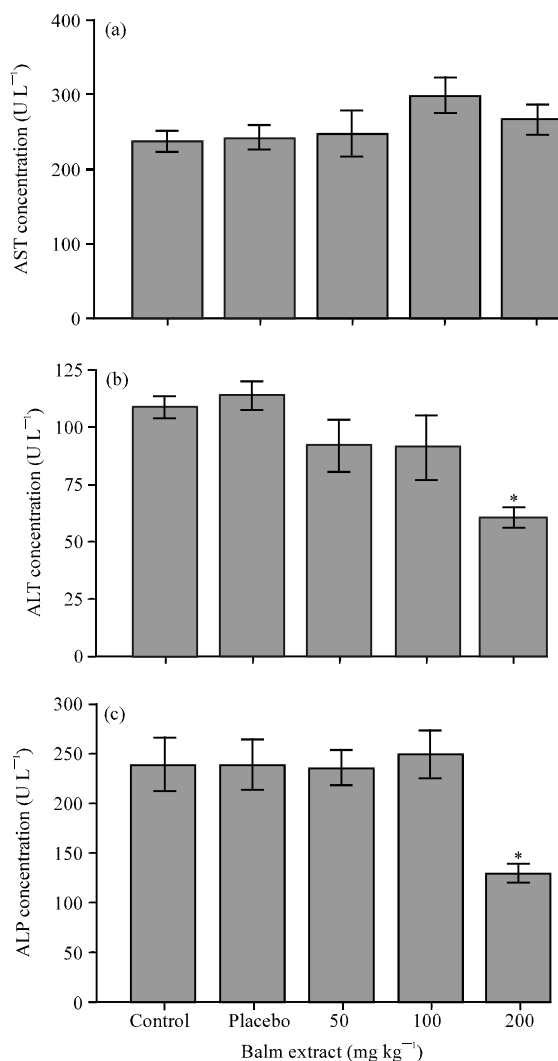


Fig. 1: Mean comparison of AST, ALT and ALP amount in various experimental groups

any of these tissues. ALT is also found naturally in liver. Although, researchers cannot say this enzyme is exclusively in liver but this tissue has the highest concentration of this enzyme. ALT is released into the bloodstream as a result of liver damage and then it is a specific indicator of liver status (Aniya *et al.*, 2005). Considering the results of this study, hydroalcoholic extract of balm caused reduction of this enzyme in 200 mg  $\text{kg}^{-1}$  treatment. In another study, mixture of balm, cinnamon and nettle extracts caused reduction in ALT amount (Malekirad *et al.*, 2012). It can be because of antioxidants existence because anti oxidants can play an important role in protect internal organs, especially heart and liver which cause aminotransferase reduction (Aniya *et al.*, 2005; Ulicna *et al.*, 2003).

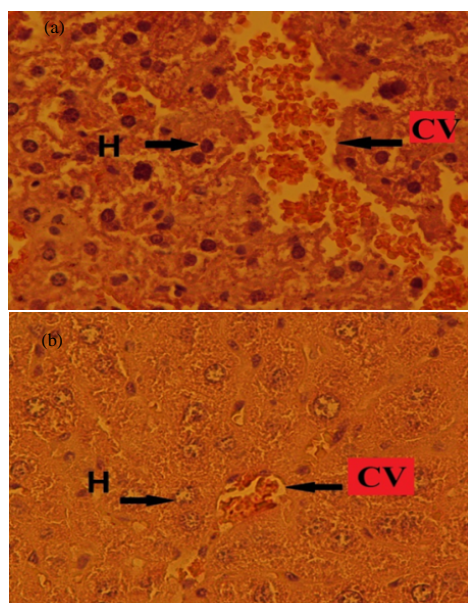


Fig. 2: Cross section of liver tissue in control group ( $\times 40$ ) in left and 200 mg kg<sup>-1</sup> in right

Activity of alkaline phosphatase was different in various doses which in 200 mg kg<sup>-1</sup>, it was reduced significantly. In a study on grape seed and oak fruit alkaline phosphatase amount was decreased also (Mirzaei *et al.*, 2011). Thioacetamide, carbon tetrachloride, ethanol and acetaminophen are matters which are metabolized by cytochrome P450 detoxification system enzymes after entering to body (Ledda-Columbano *et al.*, 1991). Free radicals are active atoms or molecules which have a strong combination tendency with their surrounding molecules because of their last atomic layer status (Chen *et al.*, 2002). These radicals can induce lipid peroxides by alkalinizing protein groups and other macro molecules and also attack to non saturated fatty acids which this can lead to liver damage. Liver necrosis leads to increase in serum level of indicator enzymes which are released from liver to blood. Increase in amount of ALT, AST and ALP enzymes and bilirubine show liver damages conventionally (Buettner, 1993). There was not considerable difference between hepatocytes number of groups of study. Also, liver tissue was also not changed considerably from histological and morphologic aspects. But, Moradkhani *et al.* (2010) in a study showed that balm reduced total cholesterol and lipid of liver tissue and also increased glutathione level in liver tissue and had protecting effects on liver of hyperlipidemic rats. Bolkent *et al.* (2005) announced also this protecting effect. Therefore, considering results of this study about very small histological and

morphological changes of liver tissue and non significant changes of hepatocytes numbers, researchers can confirm protecting effect of balm extract too.

## CONCLUSION

Finally, considering the existence of flavonoids and anti oxidants in balm extract and precautionary role of anti oxidants in radicals formation and also according to previous studies about balm effects on preventing and curing diseases like reducing extra fats of liver, being anti tumor and cancer so researchers can say that this plant have protective effects on liver tissue and researchers emphasize on proper use of herbal drugs again.

## REFERENCES

- Agata, I., H. Kusakabe, T. Hatano, O. Nishibe and T. Okuda, 1993. Melitric acids A and B, new trimeric caffeic acid derivatives from *Melissa officinalis*. Chem. Pharm. Bull., 41: 1608-1611.
- Aniya, Y., T. Koyama, C. Miyagi, M. Miyahira, C. Inomata, S. Kinoshita and T. Ichiba, 2005. Free radical scavenging and hepatoprotective actions of the medicinal herb, *Crassocephalum crepidioides* from the Okinawa Islands. Biol. Pharm. Bull., 28: 19-23.
- Bennett, C., 2003. Plant extract improves cognitive function in Alzheimer's disease. Health News, 35: 4-7.
- Bolkent, S., R. Yanardag, O. Karabulut-Bulan and B. Yesilyaprak, 2005. Protective role of *Melissa officinalis* L. extract on liver of hyperlipidemic rats: A morphological and biochemical study. J. Ethnopharmacol., 99: 391-398.
- Buettner, G.R., 1993. The pecking order of free radicals and antioxidants: Lipid peroxidation, -tocopherol and ascorbate. Arch. Biochem. Biophys., 300: 535-543.
- Carnat, A.P., A. Carnat, D. Fraisse and J.L. Lemaison, 1998. The aromatic and polyphenolic composition of lemon balm (*Melissa officinalis* L. subsp. *officinalis*) Tea. Pharm. Acta Helvetiae, 72: 301-305.
- Chen, J.W., Z.Q. Zhu, T.X. Hu and D.Y. Zhu, 2002. Structure-activity relationship of natural flavonoids in hydroxyl radical-scavenging effects. Acta. Pharmacol. Sin., 23: 667-672.
- Ghayour, M.B., M.B. Rassouli, N. Ghayour, M. Tehranipour and A.K. Abkooh, 2012. Investigating the anti-epileptic and sedative effects of hydroalcoholic extract of *Melissa officinalis* (Lemon balm) leaf on pentylenetetrazol induced *Epileptiform seizures* in wistar rat. J. Med. Plants, 8: 64-73.

- Hohmann, J., I. Zupko, D. Redei, M. Csanyi, G. Falkay, I. Mathe and G. Janicsak, 1999. Protective effects of the aerial parts of *Salvia officinalis*, *Melissa officinalis* and *Lavandula angustifolia* and their constituents against enzyme-dependent and enzyme-independent lipid peroxidation. *Plant. Med.*, 65: 576-578.
- Lamaison, J.L., C. Petitjean-Freytet, F. Duband and A.P. Carnat, 1991. Rosmarinic acid content and antioxidant activity in French Lamiaceae. *Fitoterapia*, 62: 166-171.
- Ledda-Columbano, G.M., P. Coni, M. Curto, L. Giacomini and G. Faa *et al.*, 1991. Induction of two different modes of cell death, apoptosis and necrosis, in rat liver after a single dose of thioacetamide. *Am. J. Pathol.*, 139: 1099-1109.
- Malekiran, A.A., M. Mojtabae, M. Faghih, G. Vaezi and M. Abdollahi, 2012. Effects of the mixture of *Melissa officinalis* L., *Cinnamomum zeylanicum* and *Urtica dioica* on hepatic enzymes activity in patients with nonalcoholic fatty liver disease. *Int. J. Pharmacol.*, 8: 204-208.
- Mirzaei, A., N. Mirzaei, M. Mirzaei and H. Delariz, 2011. The effect of hydroalcoholic extract of grape seed and oak (*Quercus* species) on carbon tetrachloride toxicity in rats. *Southern Med. J.*, 4: 230-239.
- Moradkhani, H., E. Sargsyan, H. Bibak, B. Naseri, M. Sadat-Hosseini, A. Fayazi-Barjin and H. Meftahizade, 2010. *Melissa officinalis* L., a valuable medicine plant. *J. Med. Plants*, 4: 2753-2759.
- Sallie, R., J.M. Tredger and R. Williams, 1991. Drugs and the liver part 1: Testing liver function. *Biopharm. Drug Dispos.*, 12: 251-259.
- Stout, R.L., 1999. The significance of liver enzyme elevations. Paper I. Hepatitis C prevalence in the insurance population. Clinical Reference Laboratory, pp:1-4. <http://www.crlcorp.com/company/PDF/liverEzymes1.pdf>.
- Ulicna, O., M. Greskshek, O. Vancovao, I. Zlatos, P. Bocek, S. Galbavy, P. Bozek and M. Nakano, 2003. Hepatoprotective effect of Rooibos tea (*Aspalathus linearis*) on CCl<sub>4</sub> induced liver damage. *Physiol. Res.*, 52: 461-466.
- Weizman, Z., S. Alkrisnawi, D. Golldfarb and C. Bitran, 1993. Efficacy of herbal tea preparation in infantile colic. *J. Pediatrics*, 122: 650-652.
- Yousefi, M., H. Hojati, M. Moshtaghi, R. Rahimian, A. Davoodiandehkordi and M. Rafieian, 2011. The effect of hydroalcoholic extract of Balm leaves on spatial learning and memory of Syrian rats. *J. Shahrekord Med. Univ.*, 4: 51-59.
- Zargari, A., 1995. *Pharmaceutical Plants*. Vol. 3, Tehran University Press, Tehran, Iran, Pages: 923.