

## The Histological Effect of Hunger Stress on the Stomach in Male Albino Rats: A Study of Light Microscope

Maisa M. Al-Qudah

Department of Allied Medical Sciences, Zarka University College,  
Al-Balqa Applied University, Jordan

**Abstract:** Emotional changes can influence feeding behavior. Feed intake is the cornerstone of animal productivity. The consequences of inadequate intake include inhibited growth, delayed puberty, infertility, reduced milk production and lowered resistance to parasites and disease. In this study, the histological changes observed in male albino rats' stomach mucosa which was exposed to hunger were examined. Pieces from stomach were taken in the 1st-5th days following last feeding. These tissue specimens were fixed by using 10% neutral formalin which was compressed. After routine tissue checks, the tissue pieces were sunk into paraffin wax and some blocks were prepared. With the aim to examine histological structures of the pieces taken, they were stained with Hematoxylin and Eosin (H and E). An increase in the number of blood cells taken part in stomach tissue was observed in the first 24 h. At the end of the 3rd day of hunger, necrosis of fundic glands, especially the base of fundus and mild congestion of mucosal blood vessels were observed. A widening in glandular epithelium lumen was seen after 2 days. A tendency to slim was observed in mucosa layer of the surface and glandular lumen during hunger. In the stomach mucosa, structural changes were caused by hunger. It was found that these changes were in direct proportion with hunger duration.

**Key words:** Fasting, histology, stomach, hunger, rats, Jordan

---

### INTRODUCTION

It is well known that food deprivation inhibits gastric and intestinal epithelial cell proliferation in adult rats (Alvares, 1987). The size of the crypts and villi (Altmann, 1972), the migration rate (Al-Dewachi *et al.*, 1975) and the crypt cell production rate (Goodlad *et al.*, 1988) are also decreased in food-deprived adult rats.

These starvation-induced hypoproliferative responses have been attributed to the increase in cell cycle time. Food deprivation has been found to stimulate cell proliferation in the gastric mucosa of suckling rats whereas the weanling period has been reported to be unresponsive in terms of proliferative activity (Palanch and Alvares, 1998).

Long-term hunger is a problem that all living species in the nature often have to cope with. It is a known fact that hunger has a considerable impact on many systems metabolically and structurally. In hungry living species, the speed of basal metabolism decreases rapidly and the amount of azoth in urine increases as an indicator of protein destruction. During hunger, first priority is given

to the central nerve system and erythrocytes that can use pure glucose as energy source. At the same period, the level of serum insulin decreases but the amount of glucagons increases and thus gluconeogenesis, i.e., the process of producing glucose from some amino acids and glycerol speeds up in the liver. Since the level of insulin decreases, blood cells begin to absorb less glucose. Yet, fatty acids can enter into these cells and they are used as energy source.

All of these occur during the first 48-72 h of hunger. The process of gluconeogenesis reaches at maximum level during the 3rd day of hunger (Sonmez and Ozan, 2005). During hunger, the process of cell mitosis slows down and cell cycles prolong with some cells staying at the G1 stage. In parallel to this, epithelium cells rate of renewing decreases (Colakolu *et al.*, 1999).

Blood pressure, glucose levels and body weight lower down depending upon the intensity level of hunger. The gastric pH of stomach decreases, i.e., the amount of gastric acid increases (Koc and Muslu, 2007). Emotional alterations, as well as pharmacological treatments can influence feeding behavior. For example, food intake is

increased by acute administration of diazepam (Britton *et al.*, 1981; Cooper, 1983; Khattab, 2007). Exposure to stressors cause an array of biochemical, physiological and behavioral changes (Sakr, 2007) and it has been described that chronic exposure to stressors of a certain severity decreases food intake and body weight in the rat (Dess *et al.*, 1988; Marti *et al.*, 1994). In addition, increased intake of sucrose has been reported in rats submitted to an inescapable shock session (Dess, 1992). Other studies showed that painful tail stimulation produced food craving during the training session although, the intake was reduced to half in the post-training period (Rowland and Antelman, 1976). Chronically stressed animals show increased ingestion of sweet food (Ely *et al.*, 1997).

Studies on humans have provided further evidence of overeating induced by emotional experiences (Yates, 1992; Silveira *et al.*, 2000). Peptic ulcers can occur anywhere in the digestive tract but are most common in the lower half of the stomach (gastric ulcer) or in the upper part of the duodenum, the first 30 cm of the small intestine directly below the stomach (duodenal ulcer). Despite their different locations, both types of ulcer are the result of excessive damage to the mucosal cells that line the stomach and duodenum (Peura and Czinn, 2004). To protect the stomach and small intestine from the corrosive gastric juices secreted to digest food (hydrochloric acid and pepsin), these cells produce a layer of mucin, a thick slippery mucus along with other factors that neutralize any acid that manages to come into contact with the stomach or intestinal lining. Mucosal cells lining the stomach and intestines are constantly renewed with normal turnover occurring every 72 h so any damaged cells are quickly replaced.

Problems only arise when normal mucosal cell function is disrupted by factors such as *Helicobacter pylori* infection, aspirin and other Non-Steroidal Anti-Inflammatory Drugs (NSAIDs), alcohol, nutrient deficiencies, stress and other factors. Regardless of the general appearance of a gastric ulcer at the time of endoscope, histological evaluation is generally considered to be warranted to rule out the possibility of malignancy (Thirunavukkarasu *et al.*, 2010). When hunger begins in the first instance glycogen storages mobilize and they become emptied in 24 h. There are various studies focusing on the histological and histo-chemical changes occurred in stomach mucosa in different phases of hunger (Koc and Muslu, 2007). In this study, the effects of hunger stress on stomach mucosa was examined.

## MATERIALS AND METHODS

This study was fulfilled in the Animal House of Department of Pharmacological Sciences, Faculty of Medicine, University of Jordan in August, 2011. All experiments in this study were accomplished according to the protocol recommended by Local Animal Care Ethical Committee. In this histological study, 15 male albino rats weighed  $300 \pm 10$  g were used. During the experiment, each subject group was kept in separate cages and in night-day periods with 12 h.

Following last feeding, pieces were taken from stomach of the subjects after applying ether anesthesia at the end of the 24th h and 2nd-5th days following last feeding. These pieces were fixed by using 10% neutral formalin which was compressed. After washing and routine checking procedures, the pieces were sunk into paraffin wax and then, blocks were prepared. The sections being 5  $\mu$  in thickness and having been taken from paraffin blocs were stained with Hematoxylin and Eosin to examine general histological structure. These preparations were examined under the Zewiss light microscope and their photographs were taken.

## RESULTS AND DISCUSSION

Stomach mucosa of the control groups were in normal histological appearance (Fig. 1). Tubular stomach glands under the surface epithelium were observed. Parietal cells were seen in gland epithelium. At the end of the first 24 h, following last feeding congestion of blood vessels were seen (Fig. 2 and 3). Some flattening and degeneration were observed in the surface epithelium and gland epithelium. An increase was seen in the congested blood veseles.

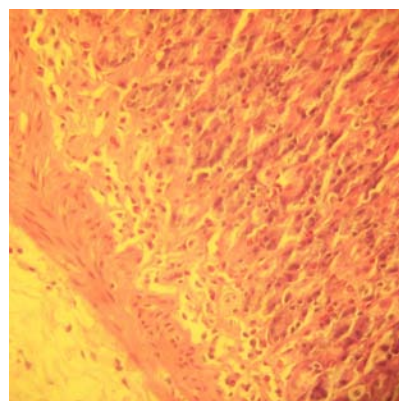


Fig. 1: Section of stomach (control), showing transverse section of fundic glands with chief cells at the base (H and E stain,  $\times 400$ )

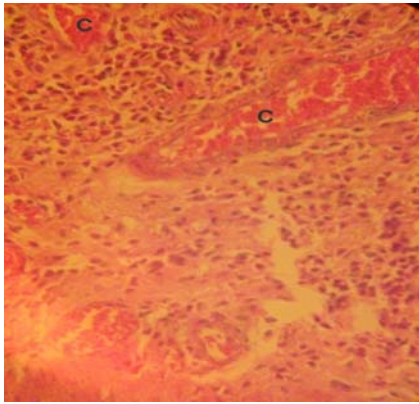


Fig. 2: Section of stomach after 1st day of last feeding, showing congestion of blood vessels (H and E stain, ×400)

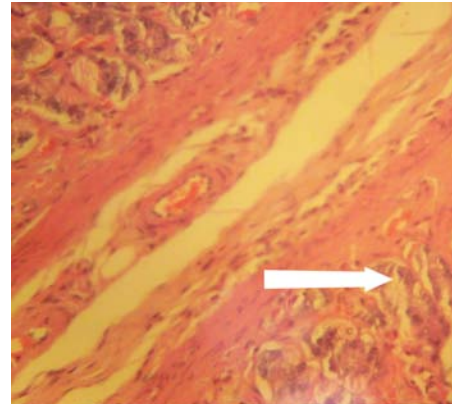


Fig. 5: Section of stomach after 2nd day of last feeding, showing degeneration and necrosis of fundic glands (arrow) (H and E stain, ×400)

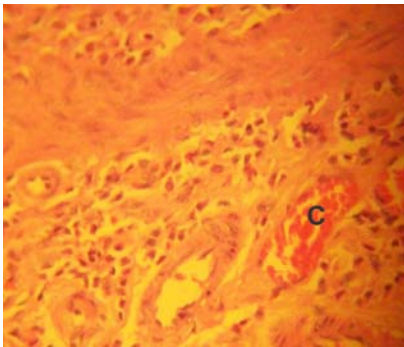


Fig. 3: Section of stomach after 1st day of last feeding, showing congestion of blood vessels of submucosal layer (H and E stain, ×400)

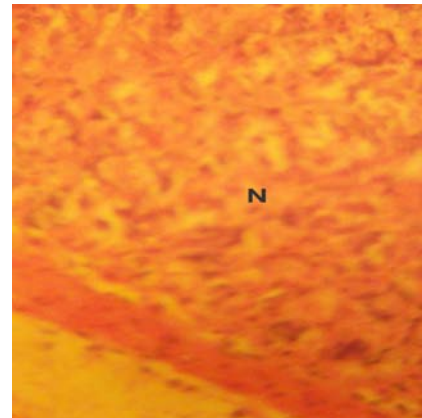


Fig. 6: Section of stomach after 3rd day of last feeding, showing necrosis of fundic glands especially the base of fundus (H and E stain, ×400)

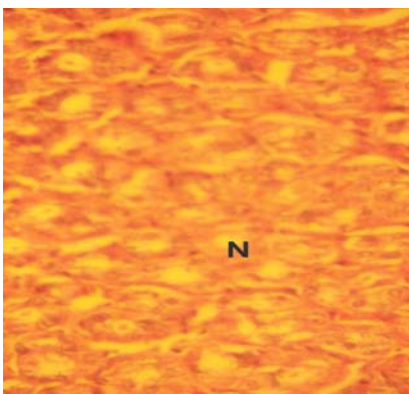


Fig. 4: Section of stomach after 2nd day of last feeding, showing necrosis of the base of fundic glands (H and E stain, ×400)

Muscular layer had normal histological appearance. In the 48th h, these changes became more obvious and degeneration and necrosis of fundic glands were

observed (Fig. 4 and 5). In addition to this, a partial destruction was observed in the surface epithelium. There was also degeneration in parietal cells morphologically. At the end of the 3rd day of hunger, necrosis of fundic glands, especially the base of fundus (Fig. 6) and mild Congestion of mucosal blood vessels (Fig. 7) were seen. It was observed that stomach glands of the rats had widened and there were disintegration in mucus cells and shrinkages in parietal cells. Necrosis of fundic glands were also seen at the end of the 4th day of hunger (Fig. 8) and congestion of blood vessels at the mucosa of the stomach (Fig. 9 and 10). At the end of the 5th day of hunger, necrosis of gastric glands and congestion of submucosal blood vessels were observed (Fig. 11 and 12). It was detected that the muscular structure was degenerated, parietal cells were suffered from structural destruction and there was a rise in the number of cells. Hunger is a situation affecting living organisms

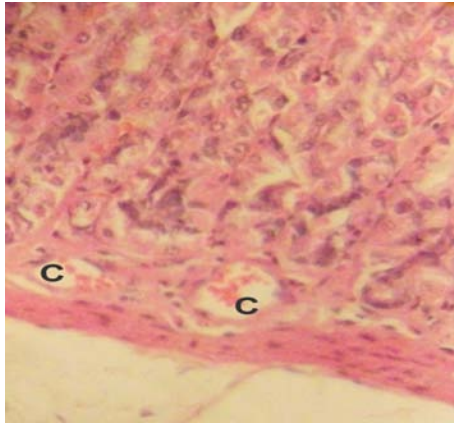


Fig. 7: Section of stomach after 3rd day of last feeding, showing mild Congestion of mucosal blood vessels (H and stain, ×400)

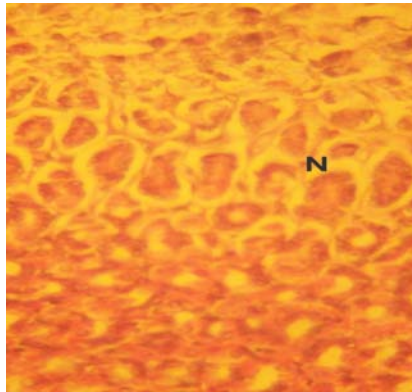


Fig. 8: Section of stomach after 4th day of last feeding, showing necrosis of fundic glands (H and E stain, ×400)

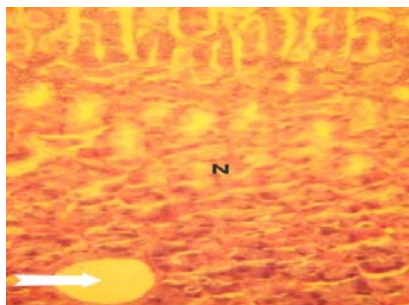


Fig. 9: Section of stomach after 4th day of last feeding, showing necrosis of mucosal area with unusual blood vessels (H and E stain, ×400)

metabolically and structurally. Secretions of the cells located in stomach glands enable the nutrients in the stomach to be decomposed and the digestion process to be started. There are studies which focus on the changes

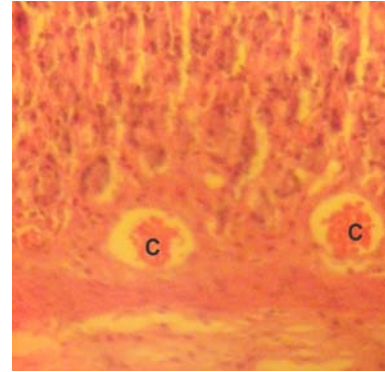


Fig. 10: Section of stomach after 4th day of last feeding, showing congestion of blood vessels at the mucosa of the stomach (H and E stain, ×400)

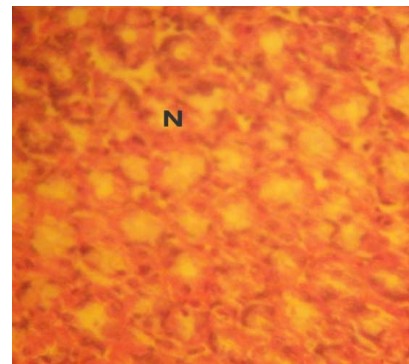


Fig. 11: Section of stomach after 5th day of last feeding, showing necrosis of gastric glands (H and E stain, ×400)

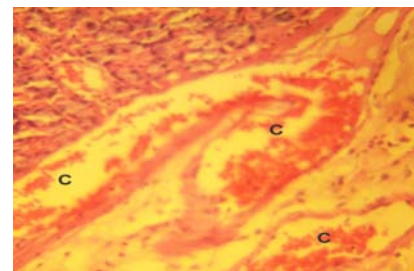


Fig. 12: Section of stomach after 5th day of last feeding, showing congestion of submucosal blood vessels (H and E stain, ×400)

in various cells of the stomach mucosa due to short-term and long-term hunger and examine these changes under the light and electron microscopes. In these studies, histological findings varied upon the genus, age and hunger level of the selected animal were obtained (Koc and Muslu, 2007; Sonmez and Ozan, 2005; Colakolu *et al.*, 1999; Ucar *et al.*, 2004 ). Blood pressure



and gastrin levels and body weight lower down significantly depending upon the intensity level of hunger (Sonmez and Ozan, 2005; Colakolu *et al.*, 1999; Ucar *et al.*, 2004). In contrast to the fluid which is a response to cellular dehydration and hypovolemia (Toth and Gardiner, 2000), the knowledge of why animals feel hunger is still poor (Smith, 2009). The size of the last meal is probably more important than the length of time since that meal which suggest that calorie intake is the most important factor (Friedman and Stricker, 1976). A feeling of satiation is probably also important for animals as it is for human, this feeling is in turn influenced by a range of factors, not just the degree of distention of the stomach.

The loss of the feeling of satiation is probably more important for the re-initiation of feeling than a feeling of hunger. The lack of knowledge about the factors controlling feeding behavior makes it difficult to evaluate the effects of fasting which is complicated by the fact that even adult animals often exhibit marked variations in body weight and feed intake. For example, even genetically identical mice (B6C8F1) can vary in weight from 30-48 g (Allaben *et al.*, 1996). Feed intake and calorie demands can in addition vary between genetic lines, age groups environments, physiological status and the opportunity to undertake physical exercise. Animals will also often overeat when large amounts of food are continually available. The body has better mechanisms for avoiding overhydration than it does for limiting overeating (Smith, 2009). In this study, the changes in stomach mucosa occurring during hunger were examined. It was assumed that hunger causes thinning in the mucus layer of stomach epithelium surface.

The first changes in the stomach mucosa resulting from hunger were detected at the end of the first 24 h following last feeding. In this period, it was observed that the lumen of stomach glands widened. The surface epithelium became flattened and degenerated. Colakolu *et al.* (1999) observed the widening in gland lumen after 3 days of hunger. Alvares (1992) detected no change in stomach mucosa of the mice after 18 h of hunger. Zaviacic *et al.* (1977) observed that there were some pouring in the surface mucus cells and shrinkages in the parietal and main cells after the 72 h of hunger. Matsumoto *et al.* (1989) observed that stomach ulcers occur in mice due to hunger.

Jacobs and Sturtevent (1982) found that there are more multi-vesicular elements in normally and limitedly feeding animals than the case in hungry animals. Furthermore, they detected that some irregularities take place in the granular endoplasmic reticulum of parietal cells during hunger. In that study, some degeneration was

observed in stomach mucosa of the rats which were kept hungry in 5 days but no sign of ulcer was observed. In this study, it was seen that the surface mucus cells get poured and some cells became shrunk after 3 days of hunger. It was found that the microvillus structures of parietal cells in the stomach were affected from hunger. In the 4 and 5th days of hunger, the tendency of shortening and becoming sparse was observed. Another change occurred in the stomach mucosa due to hunger is the degeneration and pouring in the surface epithelium. It was seen that there was some pouring in the surface mucus cells during the 3rd day of hunger.

## CONCLUSION

In this study, it was noticed that hunger causes an obvious reduction in the mucus mucosa of stomach epithelium surface. Considering this study and other related studies, researcher reach the conclusion that stomach mucosa is affected and some histo-pathological changes occur under hunger stress depending upon the duration of hunger.

## REFERENCES

- Al-Dewachi, H.S., N.A. Wright, D.R. Appleton and A.J. Watson, 1975. The effect of starvation and refeeding on cell population kinetics in the rat small bowel mucosa. *J. Anatomy*, 119: 105-121.
- Allaben, W.T., A. Turturru, J.E.A. Leaky, J.E. Seng and R.W. Hart, 1996. FDA points to consider documents: the need for dietary control for the reduction of experimental variability within animal assays and the use of dietary restriction to achieve dietary control. *Toxicologic Pathol.*, 24: 776-781.
- Altmann, G.G., 1972. Influence of starvation and refeeding on mucosal size and epithelial renewal in the rat small intestine. *Am. J. Anatomy*, 133: 391-400.
- Alvares, E.P., 1987. Circadian rhythms of mitotic activity in gastric mucosa of feeding and fasting rats. *Prog. Clin. Biol. Res.*, 227: 353-360.
- Alvares, E.P., 1992. The effects of fasting on cell proliferation in the gastric mucosa of the 14 day old suckling rat. *Braz. J. Med. Biol. Res.*, 25: 641-649.
- Britton, D.R., K.T. Britton, D. Dalton and W. Vale, 1981. Effects of naloxone on anti-conflict and hyperphagic actions of diazepam. *Life Sci.*, 29: 1297-1302.
- Colakolu, N., A. Kukner, L. Canpolat, M.R. Gezen, J. Oner and E. Ozan, 1999. Light microscopic observation of gastric mucosa changes at starvation. *Firat Tip Dergisi*, 8: 575-580.

- Cooper, S.J., 1983. Benzodiazepine-opiate antagonist interactions in relation to anxiety and appetite. Trends Pharmacol. Sci., 4: 456-458.
- Dess, N.K., 1992. Divergent responses to saccharin vs. sucrose availability after stress in rats. Physiol. Behav., 52: 115-125.
- Dess, N.K., J. Raizer, C.D. Chapman and J. Garcia, 1988. Stressors in the learned helplessness paradigm: Effects on body weight and conditioned taste aversion in rats. Physiol. Behav., 44: 483-490.
- Ely, D.R., V. Dapper, J. Marasca, J.B. Correa and G.D. Gamaro *et al.*, 1997. Effect of restraint stress on feeding behavior of rats. Physiol. Behav., 61: 395-398.
- Friedman, M.I. and E.M. Stricker, 1976. The physiological psychology of hunger: A physiological perspective. Psychol. Rev., 83: 409-431.
- Goodlad, R.A., J.A. Plumb and N.A. Wright, 1988. Epithelial cell proliferation and intestinal absorptive function during starvation and refeeding in the rat. Clin. Sci., 74: 301-306.
- Jacobs, D.M. and P.R. Sturtevant, 1982. Circadian ultrastructural changes in rat gastric Parietal cells under altered feeding regimens: A morphometric study. Anatomical Rec., 203: 101-113.
- Khattab, K.I.F., 2007. Histological and ultrastructural studies on the gastric mucosa of rat after treatment with ethylene glycol. Aust. J. Basic Applied Sci., 1: 157-168.
- Koc, N.D. and M.N. Muslu, 2007. The histological examination of *Mus musculus*' stomach which was exposed to hunger and thirst stress: A study with light microscope. Pak. J. Biol. Sci., 10: 2988-2991.
- Marti, O., J. Marti and A. Armario, 1994. Effect of chronic stress on food intake in rats: Influence of stressor intensity and duration of daily exposure. Physiol. Behav., 55: 747-753.
- Matsumoto, A., S. Asada, O. Saitoh, H. Tei, Y. Okumara, I. Hirata and S. Ohsihaba, 1989. A study on gastric ulcer induced by long-term fasting in rats. Scand J. Gastroenterol. Suppl. Nobel Kitapevi, Istanbul Turkey, 162: 75-78.
- Palanch, A.C. and E.P. Alvares, 1998. Feeding manipulation elicits different proliferative responses in the gastrointestinal tract of suckling and weanling rats. Braz. J. Med. Biol. Res., 31: 565-572.
- Peura, D.A. and S.J. Czinn, 2004. What I need to know about Peptic Ulcers. The National Digestive Diseases Information Clearings House (NDDIC) , U.S. Department of Health and Human Services.
- Rowland, N. and S.M. Antelman, 1976. Stress-induced hyperphagia and obesity in rats: A possible model for understanding human obesity. Science, 191: 310-312.
- Sakr, S.A., 2007. Ameliorative effect of Ginger (*Zingiber officinale*) on mancozeb fungicide induced liver injury in Albino rats. Aust. J. Basic Applied Sci., 1: 650-656.
- Silveira, P.P., M.H. Xavier, F.H. Souza, L.P. Manoli, R.M. Rosat, M.B.C. Ferreira and C. Dalmaz, 2000. Interaction between repeated restraint stress and concomitant midazolam administration on sweet food ingestion in rats. Braz. J. Med. Biol. Res., 33: 1343-1350.
- Smith, A., 2009. Fasting in rodents. Norecopa Veterinaeristitutet. <http://www.norecopa.no/norecopa/vedlegg/Food-deprivation.pdf>.
- Sonmez, M.F. and E. Ozan, 2005. Fasting and refeeding effects on rats stomach tissue: Light microscopic study. Firat Tip Dergisi, 10: 96-102.
- Thirunavukkarasu, P., T. Ramanathan, L. Ramkumar and R. Shanmugapriya, 2010. Anti ulcer effect of *Avicennia officinalis* leaves in albino rats. World Applied Sci. J., 9: 55-58.
- Toth, L.A. and T.W. Gardiner, 2000. Food and water restriction protocols: Physiological and behavioral considerations. Contemp. Top., 39: 9-17.
- Ucar, M., M. Eorefolu and M. Gul, 2004. Histological and histochemical alterations in the mucosa of rat stomach induced by short and long term starvation. T Klin Gastroenterohapatoloji, 15: 23-30.
- Yates, A., 1992. Biological considerations in the aetiology of eating. Pediatric Ann., 21: 739-744.
- Zaviacic, M., M. Brozman and J. Jakubovsky, 1977. Influence of starving on the rat gastric mucosa-light and electron microscopic findings. Exp. Pathol., 14: 122-130.