

## Oral Candidiasis and Oral Hyperplastic Candidiasis: Clinical Presentation

<sup>1</sup>G.A. Scardina, <sup>1</sup>G. Fucà, <sup>1</sup>A. Ruggieri, <sup>2</sup>F. Carini, <sup>1</sup>A. Cacioppo, <sup>2</sup>V. Valenza and <sup>1</sup>P. Messina

<sup>1</sup>Department of Oral Science,

<sup>2</sup>Department of Experimental Medicine, University of Palermo, Italy

**Abstract:** Oral candidiasis is an opportunistic infection of the oral cavity. It is common and underdiagnosed among the elderly, particularly in those who wear dentures and in many cases is avoidable with a good mouth care regimen. It can also be a mark of systemic disease, such as diabetes mellitus and is a common problem among the immunocompromised. Oral candidiasis is caused by an overgrowth or infection of the oral cavity by a yeast-like fungus, candida. The important ones are *C albicans*, *C tropicalis*, *C glabrata*, *C pseudotropicalis*, *C guilliermondii*, *C krusei*, *C lusitaniae*, *C parapsilosis* and *C stellatoidea*. *C albicans*, *C glabrata* and *C tropicalis* represent more than 80% of isolates from clinical infection. Oral candidiasis is the most common human fungal infection especially in early and later life. The incidence varies depending on age and certain predisposing factors. There are three broad groupings consisting of acute candidiasis, chronic candidiasis and angular cheilitis. Chronic hyperplastic candidosis/candidiasis (CHC; syn. candidal leukoplakia) is a variant of oral candidosis that typically presents as a white patch on the commissures of the oral mucosa. Risk factors include impaired salivary gland function, drugs, dentures, high carbohydrate diet, smoking, diabetes mellitus, Cushing's syndrome, malignancies and immunosuppressive conditions. The aim of the research is to describe the clinical manifestations of the disease.

**Key words:** Oral candidiasis, oral hyperplastic candidiasis, clinical presentation, oral cavity, CHC

### INTRODUCTION

Candidiasis is an opportunistic infectious condition caused by a ubiquitous, saprophytic fungi of the genus *Candida*, which includes eight species of fungi, the most common of which is *Candida albicans*. Candidiasis is usually limited to the skin and mucous membranes (Damm and Fantasia, 2006; Dreizen, 1984; Gonsalves *et al.*, 2007). *Candida* is commensal organism and part of the normal oral flora in about 30-50% of the population and is capable of producing opportunistic infections within the oral cavity when appropriate predisposing factors exist. Some authors identified three general factors that may lead to clinically evident oral candidiasis. These factors are: The immune status of the host, the oral mucosal environment and the particular strain of *C. albicans* (the hyphal form is usually associated with pathogenic infection) (Lehman, 1998; Li *et al.*, 2007; Peterson, 1992; Ugen *et al.*, 2007). Regardless of the type of candidosis, the ability of *Candida* species to persist on mucosal surfaces of healthy individuals is an important factor contributing to its virulence. This is particularly important in the mouth, where the organism has to resist the mechanical washing action of a relatively constant flow of saliva. It is of

course true that infection by an opportunistic pathogen such as *Candida* is dependent not only on virulence factors of the organism but also equally, or indeed more, on host factors (Ellepola and Samaranayake, 2001; Epstein *et al.*, 1984; Silverman *et al.*, 1984; Smith, 1985).

### HOST LOCAL FACTORS

Impaired salivary gland function can predispose to oral candidiasis. Secretion of saliva causes a dilutional effect and removes organisms from the mucosa. Antimicrobial proteins in the saliva such as lactoferrin, sialoperoxidase, lysozyme, histidine-rich polypeptides and specific anticandida antibodies, interact with the oral mucosa and prevent overgrowth of candida. Therefore, conditions such as Sjögren's syndrome, radiotherapy of the head and neck, or drugs that reduce salivary secretions can lead to an increased risk of oral candidiasis (Smith, 1985; Ugen *et al.*, 2007).

Drugs such as inhaled steroids have been shown to increase the risk of oral candidiasis by possibly suppressing cellular immunity and phagocytosis. The local mucosal immunity reverts to normal on discontinuation of the inhaled steroids.

Dentures predispose to infection with candida in as many as 65% of elderly people wearing full upper dentures. Wearing of dentures produces a microenvironment conducive to the growth of candida with low oxygen, low pH and an anaerobic environment. This may be due to enhanced adherence of *Candida* sp. to acrylic, reduced saliva flow under the surfaces of the denture fittings, improperly fitted dentures, or poor oral hygiene.

Other factors are oral cancer/leukoplakia and a high carbohydrate diet. Growth of candida in saliva is enhanced by the presence of glucose and its adherence to oral epithelial cells is enhanced by a high carbohydrate diet (Smith, 1985).

### SYSTEMIC FACTORS

Systemic factors include extremes of age, smoking, diabetes mellitus, Cushing's syndrome, immunosuppression, malignancies, nutritional deficiencies and antibiotics.

Samaranayake (1986) has reviewed the extensive literature on the role of nutritional factors in the pathogenesis of oral candidosis. A summary of the available data on the role of iron deficiency shows that oral candidosis may be caused in the deficient individual by at least four mechanisms that render the oral mucosa susceptible to infection by the fungus (Fig. 1). Iron deficiency can cause epithelial abnormalities such as hyperkeratosis and atrophy through alterations in the

kinetics of the rapidly dividing cells of the oral mucosa, which, in turn, result from an impairment of iron-dependent enzyme systems.

Iron deficiency has also been shown to cause depression of cell-mediated immunity both *in vivo* and *in vitro* and may also cause defects in phagocytosis and inadequate antibody production.

Some authors have shown that a significant proportion of patients with chronic hyperplastic candidosis suffered from a deficiency in folic acid. Some authors showed significant haematological abnormalities in patients with non-ulcerative diseases of the oral mucosa, including leukoplakia. Deficiencies of vitamins A and B1 and B2 are generally implicated in the causation of oral candidosis on the basis of animal experiments. There are also isolated reports of a link between deficiencies of vitamins C and K and zinc and the presence of oral candidosis. In a minority of cases, the condition has been associated with iron and folate deficiencies and with defective cell-mediated immunity (Samaranayake, 1986).

It is probable that deficiencies in the above-mentioned micronutrients act not only alone but also in concert, through their direct effect on the nutrition and kinetics of the oral epithelium as well as the systemic effects they may cause. Carbohydrate-rich diets are particularly implicated in oral candidal infections, although not necessarily in relation to chronic hyperplastic candidosis. Growth of *Candida* either in saliva or nutrient media supplemented with dietary carbohydrates is accompanied by acid production and a significant concomitant reduction in pH to very low levels. The reduced pH levels may potentiate candidal virulence by enhancing its growth, multiplication and adherence to host tissues, while activating the acidic proteases and phospholipases of the yeast. Furthermore, the direct cytotoxic effect of the acidic metabolites may exacerbate the host inflammatory response (Brassart *et al.*, 1991; Klotz and Smith, 1991; Lyon and Resende, 2007).

Early workers have shown that the candidal proteinases Secreted Aspartyl Proteinases (SAP) and lipases are particularly concentrated at the tips of these hyphal elements. Since adherence of *C. albicans* to epithelial cells is optimal at acidic pH and such an environment is conducive for SAP production, acidic conditions prevalent intra-orally, especially in diseased states, appear to promote candidal virulence (Brassart *et al.*, 1991; Lyon and Resende, 2007). Neutrophils are the main opponents of *Candida albicans* in chronic hyperplastic candidosis. They migrate from the circulation to the epithelium where they form microabscesses. The neutrophil chemokine interleukin-8

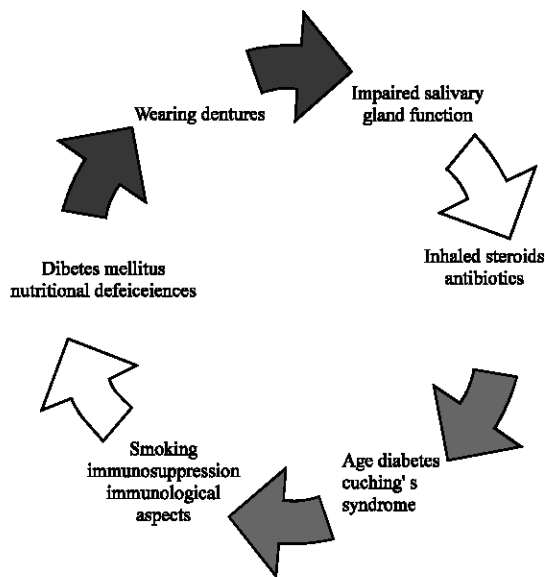


Fig. 1: Risk factors for oral candidiasis

(IL-8) might play a role in the neutrophil-Candida interaction. The neutrophil chemokine interleukin-8 (IL-8) might play a role in the neutrophil-Candida interaction. In chronic hyperplastic candidosis lesions IL-8 was strongly expressed in both vascular endothelium and mucosal epithelium. Many resident and immigrant inflammatory cells, including intraepithelial neutrophils, were IL-8 receptor A positive. In addition, IL-8 (or an analogue) was found in the candidal mother cell in chronic hyperplastic candidosis and in agar, whereas the tips of the hyphae expressed IL-8 receptor A (or an analogue) (Lyon and Resende, 2007).

The diagnosis of oral candidiasis is most frequently made on the basis of clinical appearance along with exfoliative cytology examination. This involves the histologic examination of intraoral scrapings which have been smeared microscope glass slides. The slide containing the cytologic smear can be sprayed with a cytologic fixative and stained using PAS (Periodic Acid-Schiff) stain prior to microscopic examination. A biopsy of affected tissue may be indicated, especially when candidiasis is suspected in conjunction with some concurrent pathology, such as epithelial dysplasia, squamous cell carcinoma, or lichen planus (Williams and Lewis, 2000). Biopsy is important, as a clinical condition is premalignant (CHC) and shows varying degrees of dysplasia (Cullough *et al.*, 2002).

Oral cancer supervenes in 9-40% of candidal leukoplakias compared with the 2-6% risk of malignant transformation cited for leukoplakias in general. The risk of carcinoma developing in candidal leukoplakia will depend on whether the lesion is speckled or homogeneous, the presence and degree of epithelial dysplasia and the management adopted (Cullough *et al.*, 2002). The histopathology of candidal leukoplakia includes parakeratosis and epithelial hyperplasia and Candida invasion restricted to the upper layers of epithelium.

### CLINICAL MANIFESTATION

- (Acute) Pseudomembranous candidiasis.
- Chronic hyperplastic candidiasis.
- Chronic atrophic (erythematous) candidiasis.
- Median rhomboid glossitis.
- Angular cheilitis (perleche).

Chronic Hyperplastic Candidosis/candidiasis (CHC; candidal leukoplakia) is a variant of oral candidosis that typically presents as a white patch on the commissures of the oral mucosa. Clinically, the lesions are symptomless and regress after appropriate antifungal therapy and

correction of underlying nutritional or other deficiencies (Reichart *et al.*, 2000; Sitheeque and Samaranayake, 2000). If the lesions are untreated, minor proportion may demonstrate dysplasia and develop into carcinomas (Fig. 2-4).

Candida leukoplakias are chronic lesions that vary from small, palpable, trans-lucent, whitish areas to large, dense, opaque plaques, hard and rough to the touch (plaque-like lesions). Homogeneous areas or speckled areas can be seen, which do not rub off (nodular lesions). Speckled leukoplakia counts for 3-50% of all candidal leukoplakias and they are often symptomatic. Candida leukoplakias usually occur on the inside surface of one or both cheeks, less often on the tongue.

The most common site for these lesions is the buccal mucosa, especially the commissural areas. The palate and tongue may also be involved, although less frequently, with the former being affected relatively more often. Not uncommonly, the commissural lesions of CL tend to be associated with angular cheilitis. Indeed, in about one-third of candidal leukoplakias, other forms of oral

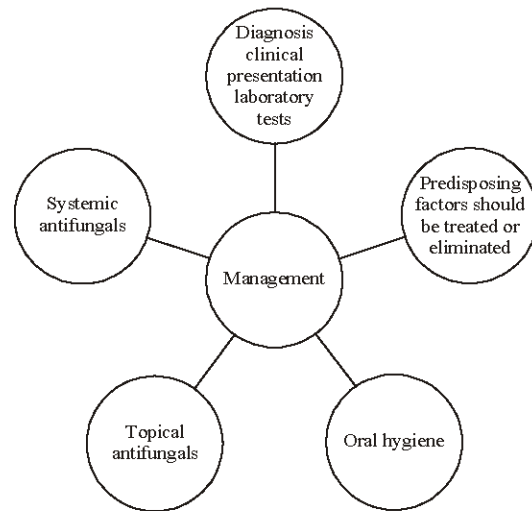


Fig. 2: Management of oral candidiasis

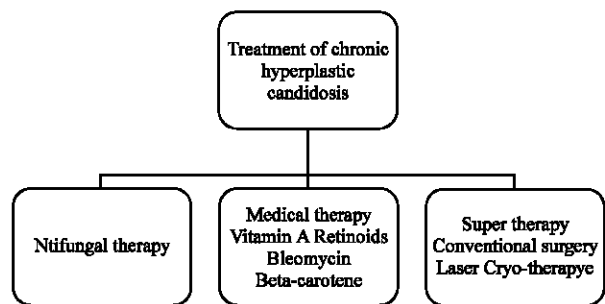


Fig. 3: Treatment of chronic hyperplastic candidosis

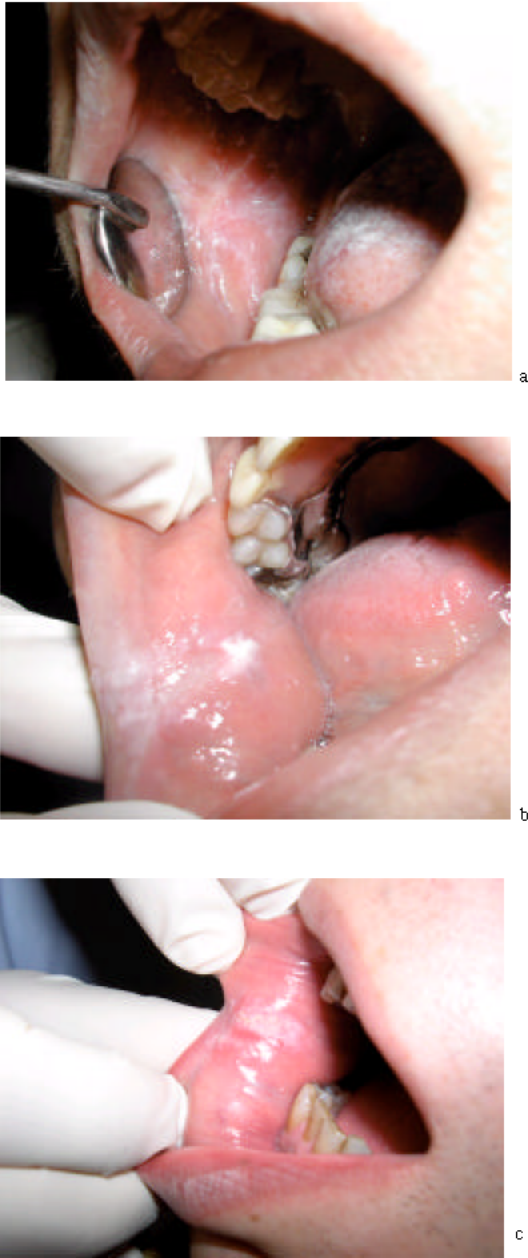

Fig. 4: The lesions are symptomless and regress

candidosis are found to coexist. These are *Candida*-associated denture stomatitis, angular cheilitis, Median Rhomboid Glossitis (MRG) and an oval or circular erythematous lesion on the palate in the area corresponding to that of MRG.

The term chronic multifocal candidosis has been used to describe this tetrad, the constant member of the group being commissural candidal leukoplakia (Blignaut *et al.*, 1999).

## REFERENCES

- Blignaut, E., M.E. Botes and H.L. Nieman, 1999. The treatment of oral candidiasis in a cohort of South African HIV/AIDS patients. *SADJ*, 54: 605-608.
- Brassart, D., A. Woltz and M. Golliard *et al.*, 1991. *In vitro* inhibition of adhesion of *Candida albicans* clinical isolates to human buccal epithelial cells by  $\text{Fuc}\alpha 1 \rightarrow 2 \text{ Gal}\beta$ -bearing complex carbohydrates. *Infect. Immun.*, 59: 1605.
- Damm, D.D. and J.E. Fantasia, 2006. Removable white lesions of buccal mucosa. *Candidiasis. Gen. Dent.*, 54: 442-444.
- Dreizen, S., 1984. Oral candidiasis. *Am. J. Med.*, 30: 28-33.
- Ellepola, A.N.B. and L.P. Samaranayake, 2001. Inhalational and topical steroids and oral candidosis: A Mini Review. *Oral Dis.*, 7: 211-216.
- Epstein, J.B., E.L. Truelove and K.L. Izutzu, 1984. Oral candidiasis: Pathogenesis and host defense. *Rev. Infect. Dis.*, 6: 96-106.
- Gonsalves, W.C., A.C. Chi and B.W. Neville, 2007. Common oral lesions: Part I. Superficial mucosal lesions. *Am. Fam. Physician.*, 75: 501-507.
- Klotz, S.A. and R.L. Smith, 1991. A fibronectin receptor on *Candida albicans* mediates adherence of the fungus to extracellular matrix. *J. Infect. Dis.*, 163: 604.
- Lehmann, P.F., 1998. Fungal structure and morphol. *Med. Mycol.*, 4: 57-58.
- Li, L., S. Redding and A. Dongari-Bagtzoglou, 2007. *Candida glabrata*: An emerging oral opportunistic pathogen. *J. Dent. Res.*, 86: 204-215.
- Lyon, J.P. and M.A. De Resende, 2007. Evaluation of adhesion to buccal epithelial cells in *Candida* species obtained from denture wearers after exposure to fluconazole. *Mycoses*, 50: 21-24.
- McCullough, M., M. Jaber, A.W. Barrett, L. Bain, P. Speight and S.R. Porter, 2002. Oral yeast carriage correlates with presence of oral epithelial dysplasia. *Oral Oncol.*, 38: 391-393.
- Peterson, D.E., 1992. Oral candidiasis. *Clin. Geriatr. Med.*, 8: 513-527.
- Reichart, P.A., L.P. Samaranayake and H.P. Philipsen, 2000. Pathology and clinical correlates in oral candidiasis and its variants: A Review. *Oral Dis.*, 6: 85-91.
- Samaranayake, L.P., Nutritional factors and oral candidiasis. *J. Oral Pathol.*, 15: 61-65.
- Silverman, S., L. Luangjarmekorn and D. Greenspan, 1984. Occurrence of oral candida in irradiated head and neck cancer patients. *J. Oral Med.*, 39: 194-196.

- Sitheequa, M.A.M. and C. Samaranayake, 2003. Chronic Hyperplastic Candidosis/Candidiasis (Candidal Leukoplakia). *Crit. Rev. Oral Biol. Med.*, 14: 253-267.
- Smith, C.B., 1985. *Candidiasis: Pathogenesis, host resistance and predisposing factors*. New York, Raven Press.
- Ugun-Can, B., T. Kadir and S. Akyuz, 2007. Oral candidal carriage in children with and without dental caries. *Quintessence Int.*, 38: 45-49.
- Williams, D.W. and M.A.O. Lewis, 2000. Isolation and identification of candida from oral cavity. *Oral Dis.*, 6: 3-11.