

## An Entire Manual for Melanoma and Non-Melanoma Types Recognizable Proof

<sup>1</sup>M. Reshma and <sup>2</sup>B. Priestly Shan

<sup>1</sup>Department of E&C, UBDT College of Engineering, Davangere, Karnataka, India,

<sup>2</sup>Eranad Knowledge City-Technical Campus, Manjeri, Kerala, India

---

**Abstract:** Skin diseases are tumors that emerge from the skin. More prominent than 90% of cases are caused by presentation to bright radiation from the Sun. It is an infection that because of the nearness of melanin color was precisely analyzed sooner than most different malignancies and that has been subjected to endless remedial methodologies. Beside early careful resection no helpful methodology has been found to bear the cost of a high probability of corrective result. This study briefs the layers of skin, separated amongst melanoma and non-melanoma, kinds of tumor which incorporates sorts of melanoma, stages, contextual analyses.

**Key words:** Lymphatic, subcutaneous, neoplasm, carcinoma, lymphoma, stages

---

### INTRODUCTION

Numerous individuals surmise that skin tumor and melanoma are a similar thing in any case, melanoma is one kind of skin malignancy. Different types of the ailment are not so much forceful but rather more typical. Melanoma is the rarest type of skin malignancy with around 76, 000 new cases analyzed every year in the US. It is additionally the most forceful skin malignancy and is well on the way to spread to different parts of the body. Henky *et al.* (1916) expressed that it was for all intents and purposes difficult to give a meaning of a tumor and many journalists, since, that time have accidentally demonstrated reality of that announcement. The measure of harm is the getting through of the basal layer by the epithelial cells. This basal layer ordinarily frames the breaking point of the epithelial cells, accordingly isolating them from the stringy tissue of the corium. Invasion, once the membrane is ruptured, may take place in any one of several ways. The cancer cells may invade practically en masse they may form more or less solid alveoli they may push forward in long alveoli or they may branch out like the branches of a tree or they may invade singly or in small groups. The mode of invasion depends on at least two factors. One the inherent power of reproduction of the cancer cell and the other the resisting power of the invaded tissue. Development happens by the growth cells either attacking between the connective tissue strands through the lymphatic or something else or by substantial pushing the connective tissue aside or all the more as a rule by a blend of the two strategies. These attacking cells

could conceivably hold association with the principle body of the tumor. In the more dangerous sorts of tumors, cells may disappear to the lymphatic organs or might be conveyed by veins to remote parts of the body or on the other hand they may spread out and frame isolate masses in the vicinity of the parent neoplasm.

In malignancy the development more often than not happens through the lymph spaces and lymph vessels. By virtue of this spread through the lymphatic framework, usually difficult to separate amongst metastasis and neighborhood infiltrative development; Truth be told it is attractive not to endeavor to recognize them for they are basically the same. Squamous cell carcinoma and basal cell carcinoma are two different sorts of skin disease. They shape in the upper and center layers of the epidermis, individually. Both are named "Nonmelanoma" and once in a while spread to different parts of the body. Conceivable indications of nonmelanoma incorporate irregular changes in the skin for example, regions that are little, raised, smooth or red or skin that is unpleasant, red and layered.

### MATERIALS AND METHODS

**Skin layers; Skin has three layers:** The epidermis, the furthest layer of skin, gives a waterproof obstruction and makes our skin tone. The dermis, underneath the epidermis, contains extreme connective tissue, hair follicles and sweat organs. The more profound subcutaneous tissue (hypodermis) is made of fat and connective tissue.

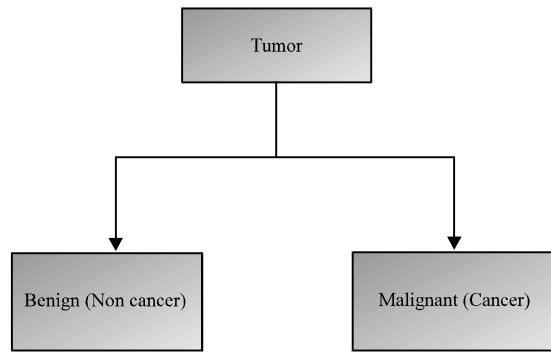


Fig. 1: Classification of tumor

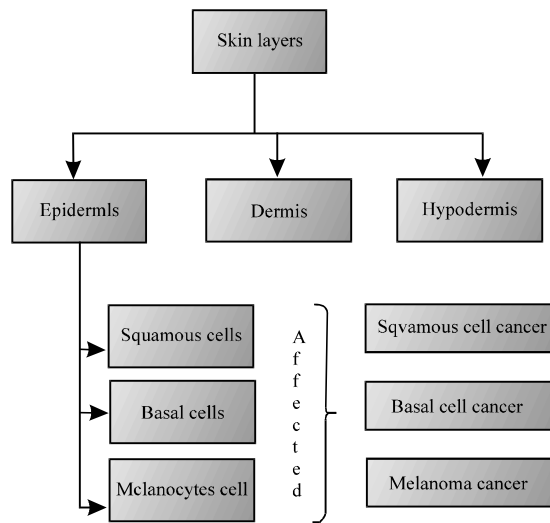


Fig. 2: Layers of skin

**Epidermis:** The upper or external layer of the two principle layers of cells that make up the skin. The epidermis is for the most part comprised of level, scale-like cells called squamous cells (Betta *et al.*, 2006). Under the squamous cells are round cells called basal cells.

The most profound piece of the epidermis additionally contains melanocytes. Non-melanoma skin growth begins in round cells called basal cells found in the best layer of the skin (epidermis). This kind of growth is called Basal Cell Carcinoma (BCC) and makes up around 75% B 80% of all skin diseases. Non-melanoma skin growth can likewise begin in squamous cells of the skin which are level cells found in the external piece of the epidermis. This sort of malignancy is called Squamous Cell Carcinoma (SCC) and makes up around 20% of all skin diseases. BCC and SCC have a tendency to develop

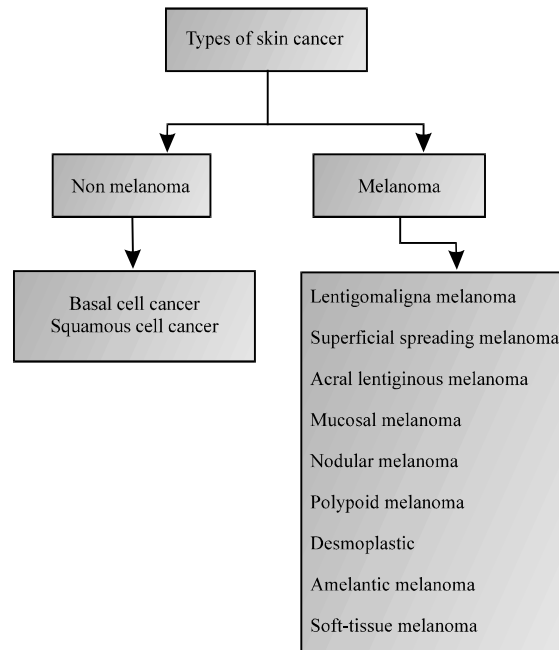


Fig. 3: Different types of ski cancer

gradually and are regularly discovered early. Uncommon kinds of non-melanoma skin tumor can likewise create.

These incorporate Merkel cell carcinoma and cutaneous T-cell lymphoma. Melanoma starts in the melanocytes which are the cells in the most reduced layer of the epidermis. Conceivable signs and side effects of melanoma incorporate an adjustment in the presence of a mole or pigmented zone of the skin. The classification of the Tumor and the layers of skin is shown in Fig 1-3.

**Distinction between melanoma and non melanoma:** With the skin as the biggest organ of the body it is justifiable skin malignancy is the most widely recognized kind of human tumor. The American Cancer Society appraises there will be around 73, 000 new instances of melanoma analyzed in 2015 and 3.5 million instances of basal and squamous cell skin malignancy. In its essential shape, growth happens when a formerly ordinary cell experiences a change and starts to develop anomalous and duplicate. As the irregular cells increase they frame a mass or tumor. On the off chance that the tumor is dangerous it will start to attack neighboring tissues, confining oxygen and fundamental supplements required for the encompassing tissues to survive. Harmful tumors may likewise metastasize or travel by means of the circulatory system to different organs (Zouridakis *et al.*, 2004). Numerous

Table 1: Stages of melanoma

Stages	Stage 0	Stage 1	Stage 2	Stage 3		Stage 4	
				Stage 2A	Stage 2B	Stage 3A	Stage 3B
Description	The malignancy is just in the best or external layer of the skin (epidermis)	The malignancy is 2 cm or littler	Tumor is bigger than 2 cm	Tumor may have spread to close-by, bone muscle, ligament or belt (connective tissue that folds over muscles, nerves, veins and organs)	The tumor has spread to close by lymph hubs	There are regions of tumor between where the malignancy began) and the nearest lymph hubs. It might likewise have spread to close-by lymph hubs	The malignancy has spread to different parts of the body, tissues under the skin or lymph hubs more remote from where the tumor began the lungs or the liver

individuals consider skin growth and melanoma to be synonymous when in certainty melanoma is just a single type of skin disease. Melanoma is by a wide margin the most forceful and destructive and maybe the most allaround known. Melanoma starts in the cells found in the most reduced layer of the epidermis alluded to as the melanocytes. These cells are in charge of shade inside the skin giving it a dark colored shading.

Melanoma frequently is found on the skin, even on regions typically not presented to the sun and can likewise begin in different parts of the body for example, the eyes or mouth. The danger of melanoma increments as individuals age (Friedman *et al.*, 1985). The dominant part of skin growth events are non-melanoma with the two most basic composes being Basal Cell Carcinoma (BCC) and Squamous Cell Carcinoma (SCC). While they are harmful they are far less inclined to spread to different parts of the body and are more effectively treated than melanoma. BCC shapes in basal cells found in the center layer of the epidermis while SCC surfaces in the upper layer in the squamous cells. BCC has a tendency to develop all the more gradually while SCC can develop into more profound layers of the skin. Non-melanoma skin diseases can as a rule be cured if recognized and treated early. "At the point when discovered early, melanoma is treatable, yet, it is a conclusion that must be observed intently forever," says Dr. Paul S. Dudrick, careful oncologist with Premier Surgical Associates. "While the danger of repeat goes down following 5 years it never totally leaves." A wide range of skin tumor, melanoma and non-melanoma, can happen any place in the body. Melanoma is most normally found on zones of the skin presented to daylight for example, the face, neck, hands, lips, ears, back of the hands and arms however can likewise surface in unexposed territories, for example, the scalp and bottoms of the feet. The most well-known advance can take in forestalling skin disease is staying away from overexposure to the sun and utilizing

sunscreen. The best method to expand your possibility of survival from skin tumor is early location and satisfactory treatment (Pariser and Pariser, 1987).

**Stages of melanoma:** Arranging portrays or orders a growth in view of how much tumor there is in the body and where it is when initially analyzed. This is frequently called the degree of disease. Data from tests is utilized to discover the measure of the tumor which parts of the skin have growth, regardless of whether the malignancy has spread from where it initially began and where the disease has spread. For melanoma there are 5 phases B arrange 0 took after by stages 1-4 explained in Table 1. Regularly the stages 1-4 are composed as the Roman numerals 1-4. By and large, the higher the stage number, the more the malignancy has spread.

**Types of skin cancer:** ABCDE lead is a simple manual for the typical indications of melanoma. Be vigilant and speedily tell the essential care doctor or dermatologist about any spots that match the accompanying depiction. A few melanomas don't fit the ABCDE control depicted, so, it is imperative to see changes in skin markings or new spots on skin (Friedman *et al.*, 1991). Other cautioning signs are: sore that does not mend, new development, spread of shade (shading) from the fringe of a spot to encompassing skin, redness or another swelling past the fringe, change in sensation B irritation, delicacy or agony, change in the surface of a mole B scaling, overflowing, dying or the presence of a knock or knob (Goodson and Grossman, 2009).

## RESULTS AND DISCUSSION

**Treatment of melanoma skin cancer, by stage:** The forecast in the malignancy of the skin relies upon a few factors first the kind of skin growth, second the phase of the sickness, third the circumstance of the tumor and last ability of the doctor who has charge of the case.

Table 2: Types of non melanoma

Type of non melanoma	Location	Appearance	Causes	Protection	Images
Basal Cell Carcinoma (BCC)	BCC are regular on the head, neck and arms, yet can frame anyplace on the body, including the chest, guts, and legs	Flesh-colored, pearl-like bump or a pinkish patch of skin	Bright light (UV), particularly bright B (UVB, 290-320 nm) Indoor tanning, reasonable cleaned appearance, earlier radiation presentation and acquired hereditary conditions	Sun avoidance, Sun protective clothing, sunblock (*****)	
Squamous cell carcinoma (SCC)	Occur most as often as possible on Sun uncovered regions (head, neck, ears lips, back of the hands and lower arms)	Dull red, rough, scaly raised skin lesions	Due to ultraviolet (UV) light exposure	Sun avoidance, Sun protective clothing, Sunblock (Menzies <i>et al.</i> , 2005)	

**Treating stage 0 melanoma:** Stage 0 melanomas have not turned out to be more remote than the best layer of the skin (the epidermis). They are regularly treated by restorative system (wide extraction) to remove the melanoma and a little edge of standard skin around it. The ousted test is then sent to a lab to be looked an amplifying instrument. In case tumor cells are seen at the edges of the case a repeat extraction of the region may be done.

**Treating stage 1 melanoma:** Stage 1 melanoma is managed by wide extraction (medicinal methodology to remove the melanoma and furthermore an edge of run of the mill skin around it). The edge of customary skin removed depends upon the thickness and region of the melanoma. A couple of pros may recommend a sentinel lymph center point biopsy, especially, if the melanoma is arrange IB or has diverse characteristics that make it more slanted to have spread to the lymph centers (Table 2 and 3).

**Treating stage 2 melanoma:** Wide extraction (medicinal methodology to empty the melanoma and an edge of run of the mill skin around it) is the standard treatment for mastermind 2 melanoma. The measure of normal skin ousted depends upon the thickness and zone of the melanoma. Since, the melanoma may have spread to lymph centers near the melanoma, various authorities recommend a sentinel lymph center point biopsy too. For a couple of patients (for instance those with lymph centers containing tumor), masters may admonish treatment with interferon after medicinal method (adjuvant treatment). Distinctive solutions or perhaps antibodies may similarly be endorsed as a part of a clinical starter to attempt to cut down the shot the melanoma will return.

**Treating stage 3 melanoma:** These sicknesses have quite recently accomplished the lymph centers when the melanoma is first examined. Watchful treatment for orchestrate 3 melanoma as a rule requires wide extraction of the basic tumor as in earlier stages, nearby lymph center point evisceration. After restorative system, adjuvant treatment with immunotherapy (for instance, nivolumab (Opdivo), ipilimumab (Yervoy) or interferon) or concentrated on treatment (for malignancies with BRAF quality changes) may help cut down the peril of the melanoma returning. Diverse meds or perhaps inoculations may in like manner be recommended as an element of a clinical starter to endeavor to lessen the likelihood the melanoma will return. Another decision is to give radiation treatment to the domains where the lymph center points were emptied, especially if gigantic quantities of the center points contain development. Other possible pharmaceuticals may join concentrated on treatment, immunotherapy, chemotherapy or a blend of immunotherapy and chemotherapy (biochemotherapy).

**Treating stage 4 melanoma:** Stage 4 melanomas are consistently hard to fix as they have viably spread to out of reach lymph center points or distinctive domains of the body. Skin tumors or expanded lymph centers causing signs can habitually be removed by therapeutic technique or treated with radiation treatment. Metastases that reason signs anyway can't be cleared may be treated with radiation, immunotherapy, coordinated treatment or chemotherapy. Since, sort out 4 melanoma is hard to fix with current meds, patients may need to consider sharing in a clinical starter. Regardless of the way that stage 4 melanoma is much of the time hard to fix a little section of people respond to a great degree well to treatment and make due for quite a while in the wake of finding.

Table 3: Types of melanoma

Type of melanoma	Characteristics	Fatality rate (%)	Symptoms	Existence	Images
lentigo maligna melanoma	It is an early sort of melanoma in which the perilous cells are limited to the tissue of beginning stage, the epidermis from this time forward normally declared as "in situ" melanoma determination, Irregular shape	5	large, flat, tan-colored lesions containing differing shades of brown or as in other melanomas, black, blue, red, gray or white	Head and neck with a preference for the nose and cheek	
Superficial spreading melanoma		70	The obscuring in one a player in a previous mole or the presence of another mole on unaffected, typical skin (Soyer <i>et al.</i> , 1987)	Appear on the trunks of men, the legs of women	
Acral lentiginous melanoma	Individuals with dim skin are additionally defenseless against ALM. As individuals with dim skin are less inclined to different types of melanoma, ALM is the main source of melanoma in individuals with darker skin	<5	a nail streak ,a changing spot an irregularly-shaped, unusual color an elevated, thickened patch growing on the sole of the foot or palm of the hand	Appears on the palms, soles or under the nails	
Mucosal melanoma	Uncommon kind of melanoma that happens on mucosal surfaces Mucous films are wet surfaces that line pits inside the body Not pigmented	0.7-0.8	Nose bleeds, bleeding lump, ulcers, loss of sense of smell, nasal obstruction, a discolored area in the mouth, dentures that stop fitting properly anus or rectal areas bleeding, pain in the area, diarrhea, constipation, a mass that. is present	Eyes, mouth, head, neck, respiratory tract, gastrointestinal tract, vagina and vulva, anus	
Nodular melanoma	Nodular melanoma is more typical in men than ladies. It has a tendency to develop all the more quickly in thickness (enter the skin) than in width	10-15	A light-colored or non-pigmented NM lesion may escape detection because the appearance is not alarming, however an ulcerated and/or bleeding lesion is common	Trunk, the head, or the neck	
Polypoid melanoma	Polypoid melanoma is a subtype of nodular melanoma, the most forceful type of melanoma	8	New growths on the skin, dome-shaped darkly-colored but they may be light brown or light pink, grow very quickly, often becoming quite tall	Unexpected places like the nasal mucous membranes and the rectum	
Desmoplastic melanoma	It is an uncommon type of invasive melanoma, a skin disease that emerges from color cells (melanocytes). Desmoplastic melanoma regularly includes nerve strands when it is called neurotropic melanoma	4	Desmoplastic melanoma usually lacks the ABCD melanoma warning signs. sometimes described as scar-like. It is often skin colored but may be pigmented	A thickened injury, More noteworthy number of hues, particularly blue or dark, Ulceration or dying Tingling or stinging.	
Amelanotic melanoma	Sores that are just somewhat without shade while genuinely amelanotic melanoma where sores do not have all all color is uncommon. Non dangerous compared to any other form of melanoma (Bono <i>et al.</i> , 1996)	1-8	The essential side effect of amelanotic melanoma is a bizarre skin development Not at all like pigmented melanoma, be that as it may, amelanotic black melanomas are regularly exceptionally out. They might be pink or red. mending scores take after a little scar or skin. A few break out that is	History of severe sunburns, more moles	
Soft-tissue melanoma	It is an exceptionally uncommon tumor speaking to a minority of all delicate tissue sarcomas	3	A bump or mass is the most widely recognized delicate tissue sarcoma sign Awkward swelling is another indication of delicate tissue sarcoma, particularly when it is situated in the arms and legs	Foot, knee, heel, ankle	

## CONCLUSION

This study outlines the melanoma and non melanoma where one can mindful of stages,

indications of every melanoma can without much of a stretch distinguish the kind of melanoma. Medications for each stage has been said for survival of patient.

## REFERENCES

- Betta, G., G. Di Leo, G. Fabbrocini, A. Paolillo and P. Sommella, 2006. Dermoscopic image-analysis system: Estimation of atypical pigment network and atypical vascular pattern. Proceedings of the IEEE International Workshop on Medical Measurement and Applications (MeMea 2006), April 20-21, 2006, IEEE, Benevento, Italy, ISBN:1-4244-0253-0, pp: 63-67.
- Bono, A., S. Tomatis, C. Bartoli, N. Cascinelli and C. Clemente *et al.*, 1996. The invisible colours of melanoma: A telespectrophotometric diagnostic approach on pigmented skin lesions. *Eur. J. Canc.*, 32: 727-729.
- Friedman, R.J., D. Rigel, M.K. Silverman, A.W. Kopf and K.A. Vossaert, 1991. Malignant melanoma in the 1990s: The continued importance of early detection and the role of physician examination and self-examination of the skin. *CA. Canc. J. Clini.*, 41: 201-226.
- Friedman, R.J., D.S. Rigel and A.W. Kopf, 1985. Early detection of malignant melanoma: The role of physician examination and self-examination of the skin. *CA. Canc. J. Clini.*, 35: 130-151.
- Goodson, A.G. and D. Grossman, 2009. Strategies for early melanoma detection: Approaches to the patient with nevi. *J. Am. Acad. Dermatol.*, 60: 719-735.
- Henky, H., A.B. Hazen and M.D. Professor, 1916. Skin cancer. PhD Thesis, Department of Medical, Georgetown University, Washington, DC., USA.
- Menzies, S.W., L. Bischof, H. Talbot, A. Gutenev and M. Avramidis *et al.*, 2005. The performance of SolarScan: An automated dermoscopy image analysis instrument for the diagnosis of primary melanoma. *Arch. Dermatol.*, 141: 1388-1396.
- Pariser, R.J. and D.M. Pariser, 1987. Primary care physicians errors in handling cutaneous disorders: A prospective survey. *J. Am. Acad. Dermatol.*, 17: 239-245.
- Soyer, H.P., J. Smolle, H. Kerl and H. Stettner, 1987. Early diagnosis of malignant melanoma by surface microscopy. *Lancet*, 330: 803-803.
- Zouridakis, G., M. Doshi and N. Mullani, 2004. Early diagnosis of skin cancer based on segmentation and measurement of vascularization and pigmentation in nevoscope images. Proceedings of the IEEE 26th Annual International Conference on Engineering in Medicine and Biology Society (IEMBS'04) Vol. 1, September 1-5, 2004, IEEE, San Francisco, California, USA., pp: 1593-1596.