

Feline Gastric Mucosa Positive for *Helicobacter* sp.: Endoscopic and Microscopic Changes

¹Daniela A. Sousa, ¹Kassia V.G.C. Silva, ¹Clarice M. Cascon, ²Marcela F.V. Mello,

²Juliana S. Leite, ³Ana Beatriz M. Fonseca and ^{1,2}Ana Maria R. Ferreira

¹Clinical and Animal Reproduction, Faculty of Veterinary Medicine,
Universidade Federal Fluminense, Niteroi, RJ-Brazil

²Department of Pathology and Veterinary Clinics, Faculty of Veterinary Medicine,
Universidade Federal Fluminense, Niteroi, RJ-Brazil

³Department of Statistics, Faculty of Mathematics, Universidade Federal Fluminense,
Niteroi, RJ-Brazil

Abstract: *Helicobacter pylori* was described as a causative agent of gastric pathologies in human as gastritis, gastric MALT lymphoma and carcinoma. The genus of these tightly coiled bacteria has been intensively studied and described in different animals. The aim of this study was to evaluate the macroscopic and microscopic changes in feline gastric mucosa positive for *Helicobacter* sp. Embedded paraffin gastric samples from 20 stray cats were selected from the archive of the veterinary anatomic pathology laboratory based on previous positive results for helicobacter spp in the Rapid Urease Test (RUT) and cytology. Infection by *Helicobacter* sp. was confirmed by histopathology using the Warthin Starry (WS) staining method. Archived data recorded during gastroscopy were analysed and related to microscopic findings obtained from histopathology. Gastroscopy evaluation showed changes as edema, hyperemia, erosion and/or ulcer in 30% of the animals. On histopathological analysis mild or moderate inflammatory cell infiltrate was observed in 75% of them.

Key words: Histopathology, gastroscopy, *Helicobacter* sp., gastritis, cats

INTRODUCTION

Since, *Helicobacter pylori* was described as a causative agent of gastric pathologies, studies on this genus have been conducted in order to evaluate the pathogenic potential of the other species. Researches have led to the description of helicobacter species which infect the stomach of mammals, birds and reptiles (Schrenzel *et al.*, 2010; Jankowski *et al.*, 2016). A variety of other *Helicobacter* sp. can infect the stomach of cats, and to date *Helicobacter heilmanni*, *Helicobacter felis*, *Helicobacter bizzozeroni* and *Helicobacter salomonis* have been reported (Neiger and Simpson, 2000).

The presence of *Helicobacter* sp. has been reported in stomachs of clinically healthy cats as well as in association with gastric pathologies such as chronic gastritis and gastric MALT lymphoma (Bridgeford *et al.*, 2008). The pathogenicity of *Helicobacter* sp. in cats

is still unknown and is probably dependent on the species or on the strain of bacteria (Haesebrouck *et al.*, 2009).

Endoscopy plays an important role in the diagnosis of *Helicobacter*-associated disease in animals. It is highly useful for more clearly defining a specific problem or problems based on the findings of gross examination and the identification of histopathologic abnormalities. *Helicobacter*-associated disease is considered a possibility when the histologic examination shows evidence of gastric inflammation in conjunction with the presence of a significant number of *Helicobacter* organisms; variable degrees of inflammation may occur (Tams, 2011).

Endoscopic aspect of suspected gastritis associated with *Helicobacter* sp. is variable, ranging from mucosa with normal appearance to a hyperemic mucosal with erosions. Some patients have diffuse nodular gastritis with increased follicular appearance, caused by an accumulation of lymphocytes (Denovo, 2003). Thus, the

aim of this study was to evaluate the macroscopic and microscopic changes in feline gastric mucosa positive for *Helicobacter sp.*

MATERIALS AND METHODS

This study was approved by the ethics Committee for the use of animals (CEUA, Comissao de Etica do Uso Animal) at Universidade Federal Fluminense under the protocol number 48/2011. Embedded paraffin gastric samples from 20 stray cats were selected from the archive of the veterinary anatomic pathology laboratory of Universidade Federal Fluminense in Rio de Janeiro, Brazil, based on previous positive results for *Helicobacter sp.* in the Rapid Urease Test (RUT) and cytology. Archived data recorded during gastroscopy were analysed. This endoscopic evaluation was done based on WSAVA international gastrointestinal standardization group (WSAVA *et al.*, 2010) where three gastric regions were analyzed: Fundus, body and antrum. The presence of edema, hyperemia, erosions and ulcers were analyzed. When observed changes in the gastric mucosa, they were classified as mild, moderate or severe gastritis.

On histopathological analysis sections of 3-5 μm in thickness were first stained with WS method and the infection by *Helicobacter sp.* was confirmed. New histological sections were then stained with hematoxylin and eosin (H and E) for the analysis of inflammatory infiltrate cells. It was made under a light microscope with a 40x objective and the type of inflammatory infiltrate was characterized and classified according to the following scale: 0 (no change): Up to 20 inflammatory cells per field; 1 (mild gastritis): 11-50 inflammatory cells per field; 2 (moderate gastritis): 51-100 inflammatory cells per field; and 3 (severe gastritis): >100 inflammatory cells per field (WSAVA *et al.*, 2010).

For statistical analysis, it was used the χ^2 -test, McNemar's test and the cramer coefficient. The level of significance was set to 5%.

RESULTS AND DISCUSSION

Endoscopic evaluation of the 20 positive cats for *Helicobacter sp.* showed that 6 animals (30%) had changes in their gastric mucosa. Alterations observed included hyperemia in all cats, edema in one cat, erosion in 3 cats and ulcer in one cat (Fig. 1). The other 14 animals (70%) had intact gastric mucosa with pale pink color and soft folds in the region of the stomach body.

All selected positive samples for *Helicobacter sp.* by RUT and citology had their results confirmed by WS,

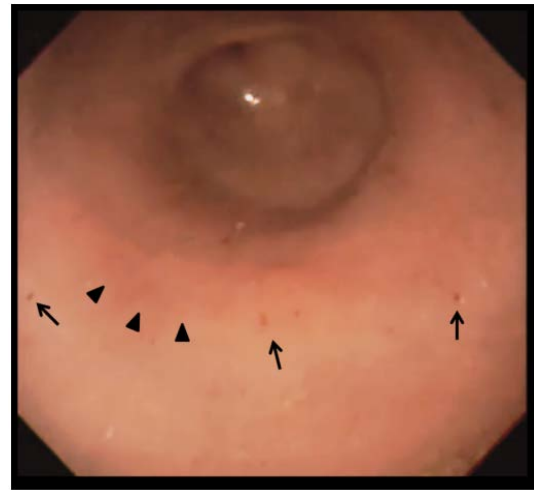


Fig. 1: Gastroscopy procedure. Note the presence of hyperemia (arrow heads) and erosions (arrows) in the gastric antrum of a cat

observing black spiral organisms in mucus layer, gastric pits and parietal cells (Fig. 2A). On histopathological examination of the inflammatory infiltrate was observed that 5 cats (25%) showed no changes in any gastric region. Mononuclear cell infiltrates were identified in 15 cats (75%). Mild infiltrate was observed in 13 cats (65%) and moderate infiltrate in 2 cats (10%) in at least one gastric region. This analysis showed the presence of lymphocytes and plasma cells. Fourteen samples from the antrum, 12 from the body and 9 samples from the fundus had Score 0. The Score 1 was assigned to 6 samples from the antrum, 7 samples from the body and 10 samples from the fundus. The Score 2 was assigned to only one sample from the body and one from the fundus. The Score 3 was not assigned to any of the samples. Therefore, the samples were classified as either mild lymphoplasmacytic gastritis (Score 1) or moderate lymphoplasmacytic gastritis (Score 2) (Fig. 2B).

When comparing the macroscopic changes observed during endoscopy and histopathological analysis, 30% of the animals had changes in the gastric mucosa on gastroscopy evaluation while 75% of them had changes on histopathological analysis, although no statistical significance was observed.

The present study showed gastric spiral bacteria in all feline gastric samples analyzed confirmed by WS staining method. The results of this study suggest that cats are frequently colonized by *Helicobacter* species agreeing with Simpson *et al.* (2000) and Araujo *et al.* (2010) who suggested the presence of *Helicobacter sp.* in cats with a high prevalence reaching from 41-100%.

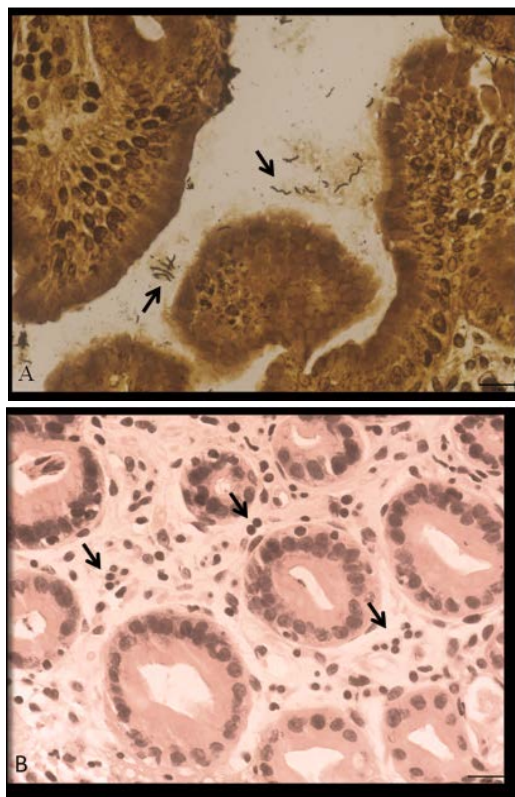


Fig. 2: Feline gastric mucosa. A: *Helicobacter sp.* in spiral shape (arrow). Warthin Starry stain. Barr = 16 μ m. B: Note inflammatory infiltrate in the lamina propria of the mucosa. H and E stain. Barr = 16 μ m

According to Megraud (1996) to be considered a positive *Helicobacter sp.* specimen, more than one diagnostic method must be employed so that the possibilities of false positives and false negatives are reduced. In this study WS method was done to confirm positive results obtained in RUT and cytology previously made.

Neiger *et al.* (1998) observed in their study that cats with *Helicobacter sp.* showed microscopic but not macroscopic changes. In the present study, 14 cats (70%) showed no changes in the gastric mucosa during macroscopic evaluation performed by endoscopy, while in the microscopic analysis only 5 animals (25%) had no mucosal changes, being classified as score 0. Six cats (30%) showed changes in gastric mucosa on endoscopic analysis and 15 animals (75%) had an increase in the number of inflammatory cells on microscopic analysis. These data showed that there was no relation between macroscopic and microscopic results in the evaluation of the presence of gastritis. This finding is in agreement with the results obtained by Akhtardanesh *et al.* (2006), who

observed macroscopic changes in only 26.3% of animals while histopathological changes were found in 66.7% of the studied samples. In contrast, Happonen *et al.* (1996) have shown in their researches an association between *Helicobacter* species infections and mild to moderate gastritis, especially in feline gastric body. Simpson *et al.* (2000) reported that it can not be assured that the presence of *Helicobacter sp.* can cause the development of gastric diseases since it is present both in healthy or sick cats. This may also be demonstrated in other studies where a high frequency of *Helicobacter sp.*, in the stomach of healthy and sick cats was found (Happonen *et al.*, 1996; Norris *et al.*, 1999; Bridgeford *et al.*, 2008). In humans, the prevalence of *H. pylori* can reach 80-90% in some countries but only 10-15% of these people develop clinical signs of infection (Simpson *et al.*, 2000; Lukinykh and Varvanina, 2015) which leads to believe that this relation with *Helicobacter sp.* can also be present in cats. In the present study there were endoscopic changes in 30% and an increase in inflammatory infiltrate in 75% of the animals. However, it was not possible to know whether these changes led to the presentation of clinical signs since the animals were caught on the street and taken to a shelter.

The pathogenicity of feline gastric *Helicobacter sp.*, has been studied but it is not yet well known. However, the pathogenicity of *H. pylori* has already been demonstrated in researches with gastric human samples. Chaturvedi *et al.* (2014) demonstrated the mechanism of cell changes caused by *Helicobacter pylori* leading to the onset of neoplasia. In the present study no statistical significance was found between the presence of *Helicobacter sp.* and the macroscopic changes or with the degree of mononuclear cell infiltration. Nevertheless, the infection by *Helicobacter sp.* in the stomach of cats can lead to the development of chronic gastritis with the presence or absence of macroscopic changes. Furthermore, Bridgeford *et al.* (2008) suggested a relationship between *Helicobacter sp.* and the development of lymphoma in cats.

Therefore, animals with clinical signs of gastric disease that underwent endoscopy procedure should always have their stomachs biopsied even if there are no endoscopic changes. While the pathogenicity of the species of *Helicobacter sp.* is not well described, it is important to treat infected cats showing chronic gastrointestinal clinical signs. Infection with *Helicobacter sp.* should be included in the differential diagnosis for all cats showing chronic gastrointestinal clinical signs.

CONCLUSION

It was concluded that infection by *Helicobacter sp.* can lead to microscopic gastric changes even when the macroscopic appearance is normal. Therefore, animals with clinical signs of gastric disease that underwent endoscopy procedure should always have their stomachs biopsied and histopathological analysis performed, even if there are no endoscopic changes.

ACKNOWLEDGEMENT

The researchers would like to thank the coordination of Improvement of higher education personnel (CAPES-Brazil) for financing the research.

REFERENCES

- Akhtardanesh, B., S.H. Jamshidi and F. Sasani, 2006. *Helicobacter sp.* infection and gastric lesions in domestic and stray cats. *Veterinarski ARHIV.*, 76: 479-488.
- Araujo, I.C., S.B. Mota, D.M.H.C. Aquino and A.M.R. Ferreira, 2010. Helicobacter species detection and histopathological changes in stray cats from Niteroi, Brazil. *J. Feline Med. Surg.*, 12: 509-511.
- Bridgeford, E.C., R.P. Marini, Y. Feng, N.M. Parry and B. Rickman *et al.*, 2008. Gastric Helicobacter species as a cause of feline gastric lymphoma: A viable hypothesis. *Vet. Immunol. Immunopathol.*, 123: 106-113.
- Chaturvedi, R., M. Asim, M.B. Piazuelo, F. Yana and D.P. Barry *et al.*, 2014. Activation of EGFR and ERBB2 by *Helicobacter pylori* results in survival of gastric epithelial cells with DNA damage. *Gastroenterol.*, 146: 1739-1751.
- Denovo, R.C., 2003. Diseases of the Stomach. In: *Handbook of Small Animal Gastroenterology*, Tams, T.R. (Ed.). Elsevier, Amsterdam, Netherlands, pp: 159-194.
- Haesebrouck, F., F. Pasmans, B. Flahou, K. Chiers and M. Baele *et al.*, 2009. Gastric helicobacters in domestic animals and nonhuman primates and their significance for human health. *Clin. Microbiol. Rev.*, 22: 202-223.
- Happonen, I., S. Saari, L. Castren, O. Tyni, M.L. Hanninen and E. Westermarck, 1996. Occurrence and topographical mapping of gastric Helicobacter-like organisms and their association with histological changes in apparently healthy dogs and cats. *J. Vet. Med. A.*, 43: 305-315.
- Jankowski, M., J. Spuzak, K. Kubiak, G.K. Suchocka and M. Biernat, 2016. Detection of *Helicobacter sp.* in the saliva of dogs with gastritis. *Polish J. Vet. Sci.*, 19: 133-140.
- Lukinykh, L.M. and S.E. Varvanina, 2015. The modern view of the issue of *Helicobacter pylori* infection. *Res. J. Med. Sci.*, 9: 39-42.
- Megraud, F., 1996. Advantages and disadvantages of current diagnostic tests for the detection of *Helicobacter pylori*. *Scand. J. Gastroenterol.*, 31: 57-62.
- Neiger, R. and K.W. Simpson, 2000. Helicobacter infection in dogs and cats: Facts and fiction. *J. Vet. Internal Med.*, 14: 125-133.
- Neiger, R., C. Dieterich, A. Burnens, A. Waldvogel and C.I. Theulaz *et al.*, 1998. Detection and prevalence of helicobacter infection in pet cats. *J. Clin. Microbiol.*, 36: 634-637.
- Norris, C.R., S.L. Marks, K.A. Eaton, S.Z. Torabian and R.J. Munn *et al.*, 1999. Healthy cats are commonly colonized with *Helicobacter heilmannii* that is associated with minimal gastritis. *J. Clin. Microbiol.*, 37: 189-194.
- Schrenzel, M.D., C.L. Witte, J. Bahl, T.A. Tucker and N. Fabian *et al.*, 2010. Genetic characterization and epidemiology of helicobacters in non-domestic animals. *Helicobacter*, 15: 126-142.
- Simpson, K., R. Neiger, R. DeNovo and R. Sherding, 2000. The relationship of Helicobacter spp infection to gastric disease in dogs and cats. *J. Vet. Internal Med.*, 14: 223-227.
- Tams, T.R., 2011. Gastroscopy. In: *Small Animal Endoscopy*, Tams, T.R. and C.A. Rawlings (Eds.). 3rd Edn., Mosby of Elsevier Inc., Philadelphia, pp: 96-172.
- WSAVA International Gastrointestinal Standardization Group, R.J. Washabau, M.J. Day, M.D. Willard and E.J. Hall *et al.*, 2010. Endoscopic, biopsy and histopathologic guidelines for the evaluation of gastrointestinal inflammation in companion animals. *J. Vet. Internal Med.*, 24: 10-26.