

Studies on Clinical Identification, Elisa, Bacteriological Isolation, PCR and X-Ray Radiography for Diagnosis of Ovine Caseous Lymphadenitis

¹Atef F. Oreiby, ¹Yamen M. Hegazy, ¹Magdy H. Al-Gaabary, ¹Salama A. Osman,

²Mohamed A. Marzok and ³Mohamed Abushhiwaa

¹Department of Animal Medicine (Infectious Diseases),

²Department of Surgery, Faculty of Veterinary Medicine, Kafrelsheikh University, Egypt

³Department of Surgery and Theriogenology, Faculty of Veterinary Medicine,
University of Tripoli, Tripoli, Libya

Abstract: This study was conducted to investigate the gap between clinical and serological approaches as well as those between bacterial isolation and PCR technique to identify ovine Caseous Lymphadenitis (CL) cases. In addition, the possibility of using x-ray imaging technique as a diagnostic tool to detect visceral CL lesions was evaluated. Clinical detection and serological identification by recombinant Phospholipase D ELISA (rPLD-ELISA) were conducted on 188 sheep belong to 9 mobile flocks at Kafrelsheikh governorate, Egypt. Clinical examination showed a 24 (12.76%) clinical cases. Abscessation of head and neck lymph nodes were the most common findings. On the other hand, rPLD-ELISA showed the positivity of 64.89% of the examined sheep. *Corynebacterium pseudotuberculosis* (*C. pseudotuberculosis*), the causative bacterium of CL was isolated only from 5 (20.83%) clinical cases. Because of the low isolation rate, PCR was conducted on the 11 culture negative cases and showed a positivity percentage of 72.7%. X-ray radiography was conducted on an Algerian ewe which was suffering from multiple superficial lesions, chronic progressive emaciation and respiratory distress. Radiography had showed a pulmonary radio-opaque mass that was identified after PM examination to be CL lesion.

Key words: Caseous lymphadenitis, clinical, isolation, ELISA, PCR, x-ray

INTRODUCTION

Caseous lymphadenitis is a bacterial wasting disease of sheep worldwide (Arsenault *et al.*, 2003). Reduction in the production of wool, meat and milk, decreased reproductive efficiency and condemnation of hides and carcasses are the most prominent economic losses from CL. The definitive diagnosis of such disease is the cornerstone for its control (Oreiby, 2015).

The clinical signs of CL are abscesses in external lymph nodes, progressive emaciation, coughing and difficulty with deglutition. Although, clinical signs of CL is considered diagnostic (Dorella *et al.*, 2006), Subclinical and visceral cases may escape clinical detection. However, in an abattoir-based study superficial form was more prevalent than visceral form in sheep (Al-Gaabary *et al.*, 2010).

Therefore, Enzyme-Linked Immunosorbent Assay (ELISA) has been presented as an economical screening test for CL. Several types of ELISA have been developed,

recombinant phospholipase-D is a highly sensitive and specific antigen for serological diagnosis of CL. Additionally, PLD-based ELISA proved to have 86.3% sensitivity and a specificity of 82.1% (Menzies *et al.* 1994). Recently, Menzies *et al.* (2004) and Sting *et al.* (2011) reported higher specificities for PLD-based ELISAs of 97 and 98%, respectively.

Isolation of *C. pseudotuberculosis* is considered confirmatory but isolation failure and inaccessibility of visceral lesions are big problems associated with such diagnostic method (Oreiby, 2015). PCR may show higher sensitivity than isolation it has been recommended to replace bacteriological methods for the diagnosis of CL (Ilhan, 2013). However, PCR is unable to detect visceral lesions when it was performed on blood samples (Pacheco *et al.*, 2007).

The similarity between CL abscesses and tuberculosis lesions, in addition to the recognition of x-ray radiography as a tool to diagnose human thoracic tuberculosis suggested the possibility of using x-rays to detect visceral CL.

This study aimed to: first, investigate the gap between clinical and serological approaches as well as between bacterial isolation and PCR, to identify CL cases and second, investigate the possibility of using x-ray imaging techniques to detect visceral CL lesions.

MATERIALS AND METHODS

Clinical and serological aspects: In this study, nine motile flocks (717 sheep) at Kafrelsheikh governorate (North of the Nile delta, Egypt) were selected randomly and a sampling fraction of approximately 25% of the sheep in each flock was examined for CL. A total of 188 (26.22%) sheep were examined clinically according to Rosenberger *et al.* (1979). Pus samples were collected aseptically from abscesses. Blood samples were also collected; the serum was separated and preserved at -20°C until used for ELISA.

C. pseudotuberculosis serotype 1 recombinant Phospholipase-D (rPLD) 100 µg vials (HYPHEN BioMed, France) was used as a coating antigen. Coating was performed on Nunc MaxiSorp® flat-bottomed 96-well plates (eBioscience, USA). The ELISA was applied and analyzed and the optical density cut-off value was estimated to be 0.4, according to Menzies *et al.* (2004).

Bacteriological isolation: Pus samples were collected aseptically by syringe aspiration after disinfection with ethanol. The samples to be used for isolation were sent to the laboratory on ice. Culture was done on blood agar at 37°C for 48-72 h according to the method described by Bailey and Scott.

PCR: To compare between isolation and PCR to identify CL, culture negative pus samples of 11 individual cases at the same studied area was used. DNA extraction and purification from pus samples were performed using GeneJET Genomic DNA Purification Kit (Fermentas Life Sciences). The extracted DNA was kept at -20°C until used.

Primer targeting *pld* gene was used and designed according to Pacheco *et al.* (2007). Serial two-fold dilutions (1:4 and 1:8) of the tested pus samples were performed to diminish the effect of PCR inhibitors. PCR was performed according to Pacheco *et al.* (2007). PCR was performed under the following conditions: initial denaturation at 95°C for 3 min followed by 40 cycles of 95°C for 1 min, 58°C for 40 sec and 68°C for 1 min 30 sec. The final extension was done at 68°C for 7 min. Electrophoresis was performed on 1% (w/v) agarose gel which were stained with ethidium bromide and finally visualized.

X-ray radiography: Lateral chest radiographs were taken for an Algerian ewe at the veterinary clinic, University of Tripoli, Tripoli, Libya. The animal had showed external CL lesions and an evidence of visceral lesions (chronic progressive emaciation and respiratory distress). Survey radiographic evaluation of the caudal thoracic and cranial abdominal regions consisted of three 14×17 inch radiographs: one positioned vertically for the caudal thorax; the second positioned horizontally for both caudal thorax and cranial abdomen and the third positioned horizontally for both cranial and caudal abdomen. The exposure factors were 25-35 mAs and 55-65 kV at a distance of 90-120 cm. Standard speed film and intensifying screens were used. The animals were tranquilized and radiographed in left lateral recumbency.

RESULTS AND DISCUSSION

Clinical and serological findings: Clinically, superficial CL was detected in 12.76% of the tested animals: 24 out of the 188 animals examined showed superficially localized abscesses, usually in external lymph nodes and rarely in subcutaneous tissues. Abscesses were not associated with cardinal signs of inflammation, were movable and of variable size and location. Lymph nodes draining the head, neck and shoulders were the most commonly affected. Some abscesses were found to be opened after trauma or after a long ripening period. The lesion contents were creamy but occasionally milky in consistency and light greenish to white in color. Recurrence of some lesions after complete disappearance was noticed. Emaciation and progressive weight loss were found in a few cases.

A total of 122 (64.89%) out of 188 examined animals were seropositive; 14 seropositive animals out of the 24 clinically diseased animals and 108 seropositive animals out of the 164 clinically healthy animals. A highly significant variation ($p < 0.0001$) between clinical and serological methods is existing. Optical density values of the serologically tested sheep are shown in Fig. 1.

Bacterial isolation: *C. pseudotuberculosis* was isolated from 5 (20.83%) out of the 24 sheep examined that showed superficial abscesses. Isolation was more feasible from closed than from opened lesions; the latter mostly yielded *Staphylococcus* sp.

PCR assay: Eight (72.7%) out of the 11 selected culture-negative pus samples were positive on PCR; three (27.2%) pus samples were negative. Both dilutions (1:4 and 1:8) of the eight samples were similarly likely to be positive but the amplicon bands were clearer in those samples diluted to 1:8, indicating the effect of PCR inhibitors.

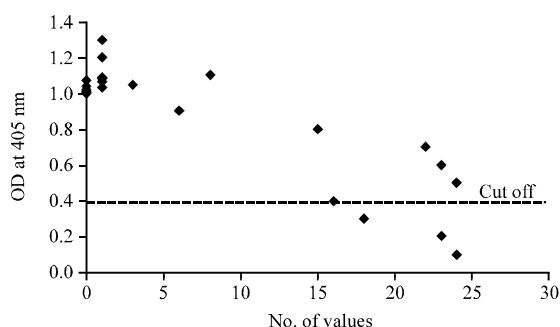


Fig. 1: OD values of the sheep serologically tested for caseous lymphadenitis using rPLD ELISA

X-ray radiography: Radiography was able to detect a pulmonary radio-opaque mass over the base of the heart in a 2 year old Algerian ewe that was suffering from external CL lesions accompanied by chronic progressive weight loss and chronic respiratory distress. For confirmation of the x-ray findings, the animal was euthanized and a mediastinal lymph node lesion was examined on post mortem examination as shown in Fig. 2a and b).

A successful control program for CL is based mainly on detection and identification of clinical and subclinical cases (Hoelzle *et al.*, 2013). Unfortunately, diagnostic tests for CL have limited sensitivity and are therefore, not conclusive. Therefore, this study was conducted to investigate variations in the diagnostic characteristics of clinical identification, rpld-based ELISA, bacterial isolation, PCR and x-ray radiography to identify CL cases.

In this study, CL abscesses were often found in the external lymph nodes, particularly of the head and neck but occasionally in subcutaneous tissues. These abscesses result from the engulfment of *C. pseudotuberculosis* cells by macrophages after transfer to the regional draining lymph node (Baird and Fontaine, 2007). The non-inflammatory nature of the lesions is mainly due to the chronicity of the disease (Al-Gaabary *et al.*, 2010).

Lymph nodes of the head and neck (particularly the parotid, superficial cervical and mandibular nodes) were the most frequently affected superficial tissues. Exposure of the anterior parts of the body to abrasions from harsh thorny food, head butting and rough scratching against hard objects as well as shearing, increase the chance of infection of these regional lymph nodes (Al-Gaabary *et al.*, 2010). Abscesses were mostly found to be closed by encapsulation with thick fibrous connective tissue, characteristic of the slow ripening nature of CL lesions.

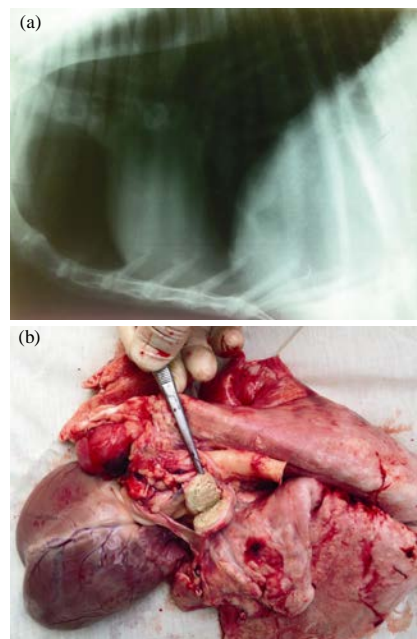


Fig. 2: a) Lateral chest radiograph of 2 year old sheep with caseous lymphadenitis. There is a radio-opaque mass over the base of the heart. The rest of the lung tissue is radiographically normal. The most likely diagnosis of the radio-opaque mass is a calcified mediastinal lymph node; b) mediastinal lymph node lesion after euthanasia of the X-ray examined sheep

A significant gap between clinical detection (12.76%) and serological identification (64.89%) is reported. High seroprevalence may indicate the presence of animals with visceral lesions or clinically unapparent cases (Arsenault *et al.*, 2003). Although, clinical signs of CL are unique and diagnostic (Al-Gaabary *et al.*, 2010) but seronegativity of 10 clinical cases may indicate another disease, a stage at which cellular immunity predominate over humoral response or any other factor results in immunosuppression. Seronegativity of some confirmed cases of CL (Binns *et al.*, 2007) has been reported previously.

Isolation of *C. pseudotuberculosis* is a confirmatory standard method but isolation failure is a problem. Isolation failure may result from over-growth of contaminants, sterile abscesses or old calcified lesions contain little pus and few viable organisms (Baird and Fontaine, 2007). This was confirmed by PCR which had showed the positivity of 72.7% of culture negative samples.

X-ray radiography proved to be useful in diagnosing CL lesions in the thorax. Similarly, chest radiography is used to detect pulmonary tubercles in humans (Kumar *et al.*, 1995) and owing to the similarity between tuberculosis and CL lesions, the possibility of using this approach in cases of CL was tested and it proved to be effective.

From this study, it can be concluded that clinical identification of CL is useful but a screening test such as ELISA is necessary. Bacteriological isolation is a confirmatory diagnostic method but PCR must be conducted on culture negative cases before a decision is taken. Finally, x-ray radiography can be used as a diagnostic tool for visceral CL lesions.

Ethical standards: All researchers gave their informed consent prior to their inclusion in the study. The study has been performed in accordance with the ethical standards laid down in the 1964, declaration of Helsinki and its later amendments.

CONCLUSION

The clinical detection of CL is insufficient and ELISA is necessary, culture negative cases must be tested by PCR before a decision is taken and finally, x-ray radiography may be used to detect visceral CL lesions.

REFERENCES

- Al-Gaabary, M.H., S.A. Osman, M.S. Ahmed and A.F. Oreiby, 2010. Abattoir survey on Caseous Lymphadenitis in sheep and goats in Tanta, Egypt. *Small Rum. Res.*, 94: 117-124.
- Arsenault, J., C. Girard, P. Dubreuil, D. Daignault and J.R. Galarneau *et al.*, 2003. Prevalence of and carcass condemnation from maedi-visna, paratuberculosis and caseous lymphadenitis in culled sheep from Quebec, Canada. *Prev. Vet. Med.*, 59: 67-81.
- Baird, G.J. and M.C. Fontaine, 2007. *Corynebacterium pseudotuberculosis* and its role in ovine caseous lymphadenitis. *J. Comp. Pathol.*, 137: 179-210.
- Binns, S.H., L.E. Green and M. Bailey, 2007. Development and validation of an ELISA to detect antibodies to *Corynebacterium pseudotuberculosis* in ovine sera. *Vet. Microbiol.*, 123: 169-179.
- Dorella, F.A., L.G.C. Pacheco, S.C. Oliveira, A. Miyoshi and V. Azevedo, 2006. *Corynebacterium pseudotuberculosis*: Microbiology, biochemical properties, pathogenesis and molecular studies of virulence. *Vet. Res.*, 37: 201-218.
- Hoelzle, L.E., T. Scherrer, J. Muntwylet, M.M. Wittenbrink, W. Philipp and K. Hoelzle, 2013. Differences in the antigen structures of *Corynebacterium pseudotuberculosis* and the induced humoral immune response in sheep and goats. *Vet. Microbiol.*, 164: 359-365.
- Ilhan, Z., 2013. Detection of *Corynebacterium pseudotuberculosis* from sheep lymph nodes by PCR. *Rev. Med. Vet.*, 164: 60-66.
- Kumar, D., K.M. Citron, J. Leese and J.M. Watson, 1995. Tuberculosis among the homeless at a temporary shelter in London: Report of a chest X-ray screening programme. *J. Epidemiol. Comm. Health*, 49: 629-633.
- Menzies, P.I., C.A. Mucle, Y.T. Hwang and J.G. Songer, 1994. Evaluation of an enzyme linked immunosorbent assay using an *Escherichia coli* recombinant phospholipase D antigen for the diagnosis of *Corynebacterium pseudotuberculosis* infection. *Small Rum. Res.*, 13: 193-198.
- Menzies, P.I., T.I. Hwang and J.F. Prescott, 2004. Comparison of an interferon gamma to phospholipase D enzyme linked immunosorbent assay for diagnosis of *Corynebacterium pseudotuberculosis* infection in experimentally infected goats. *Vet. Microbiol.*, 100: 129-137.
- Oreiby, A.F., 2015. Diagnosis of caseous lymphadenitis in sheep and goat. *Small Rum. Res.*, 123: 160-166.
- Pacheco, L.G.C., R.R. Pena, T.L.P. Castro, F.A. Dorella and R.C. Bahia *et al.*, 2007. Multiplex PCR assay for identification of *Corynebacterium pseudotuberculosis* from pure cultures and for rapid detection of this pathogen in clinical samples. *J. Med. Microbiol.*, 56: 480-486.
- Rosenberger, G., H.D. Dirksen, E. Grunert, D. Krause, M. Stober and R. Mack, 1979. Clinical Examination of Cattle. 1st Edn., Verlag Paul Parey, Berlin, Hamburg, Germany.
- Sting, R., B. Wagner, A. Sari-Turan, M. Stermann, M. Reule, M. Eichner and W. Beyer, 2011. Serological studies on *Corynebacterium pseudotuberculosis* infections in goats in Baden-Wuerttemberg (Germany) and seroreactions on antigens used for newly developed Enzyme-Linked Immunosorbent Assays (ELISA). *Berl. Munch. Tierarztl. Wochenschr.*, 125: 67-75.