

The Efficacy and Mechanism of Dexmedetomidine on the Myocardial Apoptosis Induced by Grave Scalding Rat Model

¹Wang Huishu, ²Zhang Shiduo, ³Xu Shiyuan and ²Zhang Liangcheng

¹Southern Medical University, Guangzhou, Guangdong Province, China

²Affiliated Union Hospital, Fujian Medical University, Fuzhou, Fujian, China

³Department of Anesthesiology, Zhujiang Hospital of Southern Medical University, Guangzhou, Guangdong Province, China

Abstract: To investigate the efficacy and mechanism of dexmedetomidine on myocardial apoptosis induced by grave scalding rat model. Grave scalding rat model was established. The 50 SD rats were randomly divided into five groups (n = 10): normal control (group C), simple scald group (group B), scald and 50 $\mu\text{g kg}^{-1}$ dexmedetomidine group (group D1), scald and 30 $\mu\text{g kg}^{-1}$ dexmedetomidine group (group D2), scald and 10 $\mu\text{g kg}^{-1}$ dexmedetomidine group (group D3). Blood pressure and heart rate were atraumatic measured at 0, 3, 6, 9 and 12 h, the blood and the myocardial tissue from ventriculus sinister were harvested which were assayed the troponin, myocardial apoptosis and the expression of caspase-12, GRP78 and CHOP by immunohistochemistry, terminal deoxynucleotidyl Transferase-mediated dUTP Nick End Labeling (TUNEL) and Western blotting. The HR (Heart Rate) was various in the five groups which was significant difference ($p < 0.05$). The number of buffy-stained nucleolus in the myocardial cell was the most in the simple scald group. The number of buffy-stained nucleolus of myocardial cells in the D1 and D3 group were more than that in the D2 group which were more than in the normal control group. The expression of caspase-12 obviously increased in the simple scald group compared with that in the normal control. The amount of caspase-12 was the most in the simple scald group. The expression of caspase-12 obviously decreased in the D2 group compared with that in the D1 and D3 group. The proteinic expression of GRP78 and CHOP increased in the B and D1 group which were higher than that in the normal control ($p < 0.05$). The proteinic expression of GRP78 and CHOP in the D2 and D3 groups were less than that in the B group ($p < 0.01$). The proteinic expression of GRP78 in the D2 group was less than that in the D3 group ($p < 0.05$). The proteinic expression of CHOP in the D2 and D3 groups were more than in the normal control ($p < 0.05$). The 30 $\mu\text{g kg}^{-1}$ dexmedetomidine could lessen the myocardial cellular apoptosis induced by scald, inhibit the expression of caspase-12, GRP78 and CHOP which may be the optimal option for the prevention and therapy of the shock heart compared with 10 and 50 $\mu\text{g kg}^{-1}$ dexmedetomidine.

Key words: Dexmedetomidine, myocardial apoptosis, rat, blood pressure, China

INTRODUCTION

α_2 -adrenergic agonists have been proved to have the protective effects on the ischemic myocardium such as coronary artery stenosis or myocardial stunning and attenuate the plasma NE levels and preserve myocardial blood flow in the inner layers (MeiBner *et al.*, 1998; Roekaerts *et al.*, 1996a, b; Yoshitomi *et al.*, 2012). It is well known that the central sympatholytic effect of α_2 -adrenergic agonists may be beneficial during myocardial ischemia-reperfusion injury (Riha *et al.*, 2012). α_2 -adrenoreceptors also exist at sympathetic nerve endings and cardiac presynaptic α_2 -adrenoreceptor stimulation decreased NE release from sympathetic nerve

endings (Matko *et al.*, 1994). Thus, cardiac presynaptic α_2 -adrenoreceptor stimulation would attenuate the elevation of NE concentration in ischemic myocardium. However, the effects of cardiac presynaptic α_2 -adrenoreceptor stimulation on ischemia-reperfusion myocardium have not yet been clarified.

Dexmedetomidine (DEX) is a highly specific and selective α_2 -adrenergic agonist. α_2 -adrenergic agonists are useful adjuncts to anesthesia because of their sedative, analgesic, sympatholytic and specific hemodynamic effects (Maze and Tranquilli, 1991). It has been shown that DEX was associated with a trend toward improved cardiac outcomes in a clinical setting (Biccard *et al.*, 2008). The aims of this study were to

investigate whether DEX could exert direct protective effects against myocardial apoptosis and damage induced by grave scalding.

Dexmedetomidine is new type high selectivity and specificity α_2 -adrenergic receptors agonist which possessed sedative, antianxiety and analgesic effect by dose dependent. It often is used in the process of the operations on burned patients. Myocardial damage is one of the grave complication of burned patients which is also named as shock heart. Its major mechanism is ischemia-reperfusion injury, inflammation out of control, the dysbolismus of oxygen and energy and the myocardial apoptosis by different degree. Some studies demonstrated that dexmedetomidine could protect the organs by lessening the inflammation and the damage of ischemia-reperfusion injury (Tosun *et al.*, 2013; Ji *et al.*, 2013; Ibacache *et al.*, 2012). However, the efficacy and mechanism of dexmedetomidine on myocardial apoptosis by grave scalding rat model has not been yet reported from domestic and abroad. The traditionary apoptosis way is named as caspase dependent cellular death way which consists of death receptor dependent way and mitochondria dependent way. Recent study demonstrated that endoplasmic reticulum stress could also mediate cellular apoptosis. Therefore, grave scalding rat model was established, the effect of different dose of dexmedetomidine on myocardial apoptosis and the related proteinic expression of endoplasmic reticulum stress was analyzed by immunohistochemistry, TUNEL and Western blotting. The efficacy and mechanism of dexmedetomidine on myocardial apoptosis induced by grave scalding were studied.

MATERIALS AND METHODS

Animals: The SPF grade male sprague-dawley rats (purchased from Medical Laboratory Animal Center in Fujian Medical University, Fujian, China), weighing between 0.22 and 0.28 kg. The rats were quarantined and acclimatized 1 week before the experiments in the Animal Laboratory of Fujian Medical University, Fujian, China. The experiments were performed on the rats under standard conditions throughout the study as follows: room temperature $23\pm 2^\circ\text{C}$, relative humidity $60\pm 10\%$ and alternating 12 h light-dark cycles (8 am to 8 pm). All experimental procedures conformed to the statement for the use of animals and were approved by the Medical Ethics Committee of Fujian Medical University.

Animal experiments procedure: The grave scalding rat model was established as follows: The rats were anesthetized by intraperitoneal injection of 40 mg kg^{-1}

napental, shaved the hair on the back whose back were immersed into the 94°C hot water for 12 sec, until the 30% of the body surface area was 3°C burns. The 30 SPF male SD rats were randomly divided into five groups ($n = 6$): normal control (group C), simple scald group (group B), scald and $50\text{ }\mu\text{g kg}^{-1}$ dexmedetomidine group (group D1), scald and $30\text{ }\mu\text{g kg}^{-1}$ dexmedetomidine group (group D2), scald and $10\text{ }\mu\text{g kg}^{-1}$ dexmedetomidine group (group D3). In the group C, the rats were fake burned by immersing into the 37°C warm water for 12 sec. The $2\text{ }\mu\text{g mL}^{-1}$ dexmedetomidine was prepared by isotonic saline solution. In the group D1, the rats were injected $50\text{ }\mu\text{g kg}^{-1}$ dexmedetomidine intraperitoneally after the grave scalding was established and in the group D2 and group D3, $30\text{ }\mu\text{g kg}^{-1}$ and $10\text{ }\mu\text{g kg}^{-1}$ dexmedetomidine were separately injected by intraperitoneal injection after the grave scalding was established. The rats in the group D1, D2 and D3 were injected fluid infusion of isotonic saline solution intraperitoneally according to the formula of Parkland except for group C. The rats in all the groups were bred in the single cage, respectively for taking food and drinking freely. Blood pressure and heart rate were atraumatic measured at 0, 3, 6, 9 and 12 h, the blood and the myocardial tissue from the ventriculus sinister were harvested which were divided into 3 portions and assayed the troponin, myocardial apoptosis and the expression of caspase-12, GRP78 and CHOP by immunohistochemistry, terminal deoxynucleotidyl Transferase-mediated dUTP Nick End Labeling (TUNEL) and Western blotting.

Immunopathology and immunohistochemistry:

Myocardial tissue blocks from the ventriculus sinister were harvested and studied using standard histologic and immunohistochemical analysis. The 6 mm serial paraffin sections were prepared for immunohistologic study by the Avidin-Biotin-Peroxidase Complex Method and for Hematoxylin-Eosin (H&E). Myocardial tissue blocks were fixed in 4% paraformaldehyde and then embedded in paraffin. Serial sections were cut and stained with hematoxylin-eosin. The sections were analyzed under light microscope. The myonecrosis, inflammatory cell infiltration and edema were evaluated in the section.

Serial paraffin sections were prepared, deparaffinage and dehydration, incubated in 3% H_2O_2 for 20 min, put in $92\text{--}98^\circ\text{C}$ microwave oven for 4 min, sealed off by goat serum, labeled by mouse polyclonal antibody (caspase-12 polyclonal antibody, 1:50 dilution) and by biotin-conjugated goat anti-rabbit immunoglobulin-G (American Qualtex, CA) which was depleted of cross-react anti-rat immunoglobulin-G. The photos were collected by Olympus BX51 Automated Image Acquisition System. (R&D corporation).

TUNEL assay: The TUNEL assay (terminal deoxynucleotidyl transferase-mediated dUTP nick end labeling) was operated as follows: after sacrifice, the myocardial tissue blocks were fixed in 4% paraformaldehyde in Phosphate-Buffered Saline (PBS), dehydrated through ethanol and xylene and embedded in paraffin. The 5 μ m thick sagittal sections through the myocardial tissue blocks were obtained and mounted on poly-L-lysine-coated glass slides. The ApopTag peroxidase kit (Oncor, Gaithersburg, MD) was applied on paraffin sections according to the manufacturer's instructions. Briefly, residues of digoxigenin-nucleotide were catalytically added by TdT to the 3'-OH ends of double- or single-stranded DNA. The labeled product was visualized using Diaminobenzidine (DAB) which yielded brown granules mainly localized to apoptotic cells. Following this the sections were counterstained with 1% Methyl green. Omission of TdT or digoxigenin-nucleotide gave completely negative results not shown. Comparisons of levels of neuronal cell death were determined from the number of morphologically intact cells and the number of deep brown-stained, TUNEL-positive, damaged myocardial cells in the ventriculus sinister. Apoptotic cells were identified by the distinctive condensed or fragmented nuclear structure within cells stained with the terminal deoxynucleotidyl Transferase-mediated dUTP Nick End-Labeling (TUNEL) assay (KeyGEN). The number of TUNEL-positive cells was presented as a percentage of the total cardiomyocytes. Preparations were imaged using a bright field microscope (Nikon Microscope Eclipse E600W Tokyo-Japan) and were photographed with a microscope digital camera (Nikon DP70 Tokyo-Japan).

TEM (Transmission Electron Microscope): The myocardial tissue blocks were fixed by 5% glutaraldehyde in 4°C for 3 h and rinsed by 0.1 mol L⁻¹ PBS with 6% cane sugar, fixed by 2% OsO₄ for 1 h, gradually dehydrated by acetone, blocked dyeing by 1% uranyl acetate (dispensed by dehydrated alcohol) for 1 h, embedded by epoxide resin, located by serial section (1-2 μ m) was ultramicrocut (50-70 nm) was double staining by uranyl acetate and medlar hydrochloric acid lead, observed and taken a picture by HitachiH-600.

Western blotting analysis: Western blot analysis was performed using a previous method (Porter *et al.*, 2003). In brief, the cytoplasm and nuclear protein samples (30 mg per lane) were prepared with Nuclear Extract kit (Active Motif, Carlsbad CA) and measured by a BCA Protein Assay kit (Pierce, Rockford, IL) were mixed with 6×SDS reducing sample buffer and boiled for 5 min before

loading. Proteins were separated by 10% sodium dodecyl sulfate-polyacrylamide gel electrophoresis (SDS-PAGE gel) and transferred electronically onto PVDF membranes (Millipore, USA). The membranes were blocked with 5% non-fat milk in TTBS (50 mM Tris (pH 7.5), 0.9% NaCl and 0.1% Tween-20) for 1 h at room temperature, incubated with primary antibodies against GRP or Chop (1:1000) overnight at 4°C (Cell signaling, USA) and then with horseradish peroxidase-conjugated secondary antibody for 1 h at room temperature. The secondary antibody was biotin-conjugated goat anti-mouse immunoglobulin-G (American Qualtex, CA) which was depleted of cross-react anti-rat immunoglobulin-G. All primary antibodies were used at a dilution of 1:1000. Subsequently, membranes were incubated with secondary antibodies at a 1:5000 dilution at 37°C for 30 min. The blots were visualized with ECL-Plus reagent (Santa Cruz, USA) and analyzed with Quantity One System Image Analysis Software (Bio-Rad, USA). The expression of protein was analyzed by the reinhoit zahl of target protein and β -actin protein.

Statistical analysis: All values were presented as the mean±SD. All statistical analyses were performed with SPSS Software, Version 13.0, the number of cells stained positively by immunohistochemistry for each first antibody was compared between the control and the treated groups using the same non-parametric test. The other data were compared by one-way analysis of variance and a probability value of 0.05 was considered statistically significant.

RESULTS AND DISCUSSION

The assay of the HR of the rat: The Heart Rate (HR) was various in the five groups which was significant difference ($p < 0.05$). The HR among different times was also various which was significant difference ($p < 0.05$). The HR in the simple scald group was obviously higher than that in the other four groups which maybe due to the stress accelerated heart beat by scald. The assay of blood pressure in the five groups were within the range of normal values (Table 1).

Table 1: The effect of dexmedetomidine on the HR of the rat (n = 10)

Groups	HR				p-values
	3 h	6 h	9 h	12 h	
B	363.67±5.74	363.33±5.89	367.65±5.25	369.33±4.99	<0.05
C	304.67±7.62	306.5±5.11	305.33±9.06	307.5±7.11	<0.05
D1	326.0±6.45	326.83±5.59	328.17±8.11	345.5±8.91	<0.05
D2	333.33±7.98	331.17±9.05	331.17±6.50	331.83±5.08	<0.05
D3	343.0±6.38	341.17±4.05	342.83±8.37	341.0±6.64	<0.05
p-values	<0.05	<0.05	<0.05	<0.05	<0.05

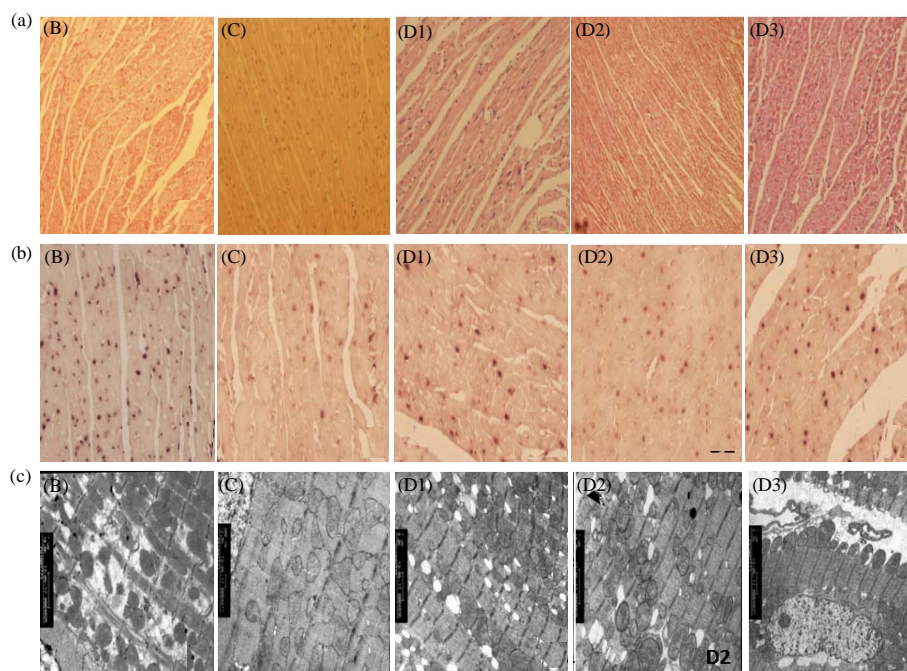


Fig. 1: The results of HE, TUNELs and TEM assay; a) the result of immunopathology; b) the result of TUNELs assay; c) the result of TE. The simple scald group (the B group); C: the normal Control group (the C group); D1: the $50 \mu\text{g kg}^{-1}$ Dexmedetomidine group (the D1 group); D2: the $30 \mu\text{g kg}^{-1}$ Dexmedetomidine group (the D2 group); D3: the $10 \mu\text{g kg}^{-1}$ dexmedetomidine group (the D3 group)

The results of immunopathology: Myocardial tissue blocks from the ventriculus sinister were harvested and studied using standard histologic analysis. It was shown that the structure of myocardium was integrated and clear, fusiform myocardiums were almost the same size with the clarity of nuclear structure. The cardiac myocyte from the ventriculus sinister was observed clearly to be normal cardiac myocyte and cardiac muscle fiber without edema and degeneration in the normal control group (group C). The cardiac myocyte in the simple scald group (group B) was obviously edema with mesenchymal hyperaemia and myofibrosis cordis, the transverse striation even vanished and was cloudiness. In the scald and $50 \mu\text{g kg}^{-1}$ dexmedetomidine group (group D1) and the scald and $10 \mu\text{g kg}^{-1}$ dexmedetomidine group (group D3), the cardiac myocyte was slightly less edema with mesenchymal hyperaemia and myofibrosis cordis than that in the B group. In the scald and $30 \mu\text{g kg}^{-1}$ dexmedetomidine group (group D2), the cardiac myocyte was less edema with mesenchymal hyperaemia and myofibrosis cordis than that in the group D1 and D3. The rat pathology and morphology of myocardium in the scald and $30 \mu\text{g kg}^{-1}$ dexmedetomidine group (group D1) were less deteriorative than that in the group D1 and D3. It

indicated that the efficacy of $30 \mu\text{g kg}^{-1}$ dexmedetomidine on the myocardial cellular apoptosis may be the optimal, compared with 50 and $10 \mu\text{g kg}^{-1}$ dexmedetomidine (Fig. 1a).

The results of TUNELs assay: Myocardial tissue blocks from the ventriculus sinister were harvested and studied using TUNEL assay (terminal deoxynucleotidyl transferase-mediated dUTP nick end labeling). The normal nucleolus of myocardial cell should be blue-stained. In the simple scald group, the nucleolus of myocardial cell was obviously stained buffy with chromatin agglutination and condense which indicated that the apoptosis of myocardial cell was stained buffy. The number of buffy-stained nucleolus of myocardial cell was the most in the simple scald group. The number of buffy-stained nucleolus of myocardial cells in the D1 and D3 group were more than that in the normal control group. The number of buffy-stained nucleolus of myocardial cell in the D2 group was less than that in the D1 and D3 group which was nearly the same to the normal control group. It indicated that the efficacy of $50 \mu\text{g kg}^{-1}$ dexmedetomidine on the myocardial cellular apoptosis may be the optimal, compared with 30 and $10 \mu\text{g kg}^{-1}$ dexmedetomidine (Fig. 1b).

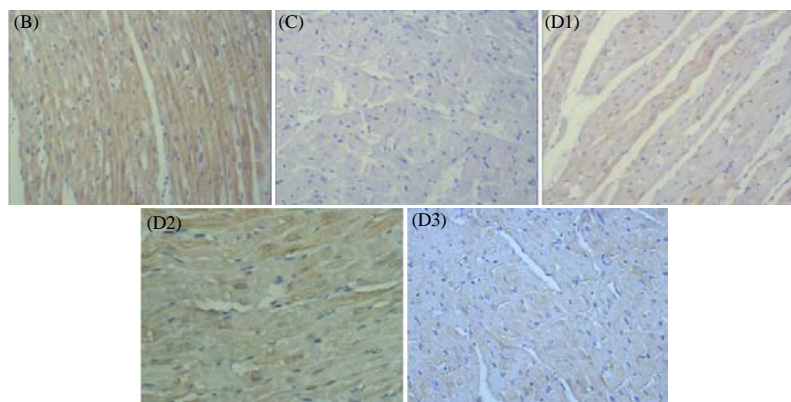


Fig. 2: The effect of dexmedetomidine on caspase-12 by immunohistochemistry assay; B: the simple scald group (the B group); C: the normal control group (the C group); D1: the 50 $\mu\text{g kg}^{-1}$ dexmedetomidine group (the D1 group); D2: the 30 $\mu\text{g kg}^{-1}$ dexmedetomidine group (the D2 group); D3: the 10 $\mu\text{g kg}^{-1}$ dexmedetomidine group (the D3 group)

Transmission electron microscope: Myocardial tissue blocks from the ventriculus sinister were harvested and studied using TEM (Transmission Electron Microscope). The microstructure of myocardial tissue blocks was clear and integrity including undamaged nucleolus, regular assay of endoplasmic reticulum and amount of mitochondria in the normal control group. In the simple scald group, the microstructure of myocardial tissue blocks was unclear and incomplete including damaged nucleolus and swell mitochondria. It was observed the edema and discrete of rough endoplasmic reticulum, the chaotic and swell structure of mitochondria and its number decreased. In the D2 and D3 group, it was also observed that the microstructure of myocardial tissue blocks was unclear and incomplete including damaged nucleolus and swell mitochondria, however in the D2 group, the microstructure of myocardial tissue blocks was better than that in the D1 and D3 group with the integrity of structure, regular assay of endoplasmic reticulum and amount of mitochondria (Fig. 1c).

The analysis of caspase-12 by immunohistochemistry assay: Caspase-12 was located on the endoplasmic reticulum in the myocardial cells, distributed by macrobead, the positive proteinic expression of caspase-12 was blue staining in the cytoplasm. The expression of caspase-12 obviously decreased in the normal control group compared with that in the simple scald group with the least amount. The amount of caspase-12 was the most in the simple scald group. However, the expression of caspase-12 obviously increased in the D1 and D3 group compared with that in the D2 group. The amount of caspase-12 in the D1 group was nearly equal to that in the normal control. It indicated

that the effect of 30 $\mu\text{g kg}^{-1}$ dexmedetomidine on the inhibition of the myocardial cellular apoptosis may be the better than that in the D2 and D3 group (Fig. 2).

The expression of GRP78 and CHOP by Western blot assay: The proteinic expression of GRP78 increased in the B and D1 group which were higher than that in the normal control ($p < 0.05$). The proteinic expression of GRP78 in the D2 and D3 groups were less than that in the B group ($p < 0.01$). The proteinic expression of GRP78 in the D2 group was less than that in the D3 group ($p < 0.05$). The proteinic expression of CHOP in the B, D1, D2 and D3 groups were more than that in the normal control ($p < 0.05$). The proteinic expression of CHOP in the D2 and D3 groups were less than that in the B group ($p < 0.01$). It demonstrated that the inhibitory effect of 30 $\mu\text{g kg}^{-1}$ dexmedetomidine on the expression of GRP78 and CHOP may be the better than that in the 50 and 10 $\mu\text{g kg}^{-1}$ dexmedetomidine group (Fig. 3).

Dexmedetomidine (Precedex) is an α_2 -adrenergic agonist that shares physiologic similarities with clonidine. It currently is approved by the FDA for continuous infusions up to 24 h in adult ICU patients who are initially intubated and received mechanical ventilation as well as for being monitored anesthesia care (Tobias *et al.*, 2011; Xue *et al.*, 2013). To date there are no FDA-approved indications for its use with myocardial ischemia-reperfusion injury and shock heart induced by grave scald and burn. As with any sedative agent, the potential exists for adverse end-organ effects with dexmedetomidine. Although, dexmedetomidine was uncommon related with hemodynamic and respiratory impairment, potential cardiovascular effects included bradycardia, sinus pause and cardiac arrest. Hypotension also has been reported as well as hypertension. The latter

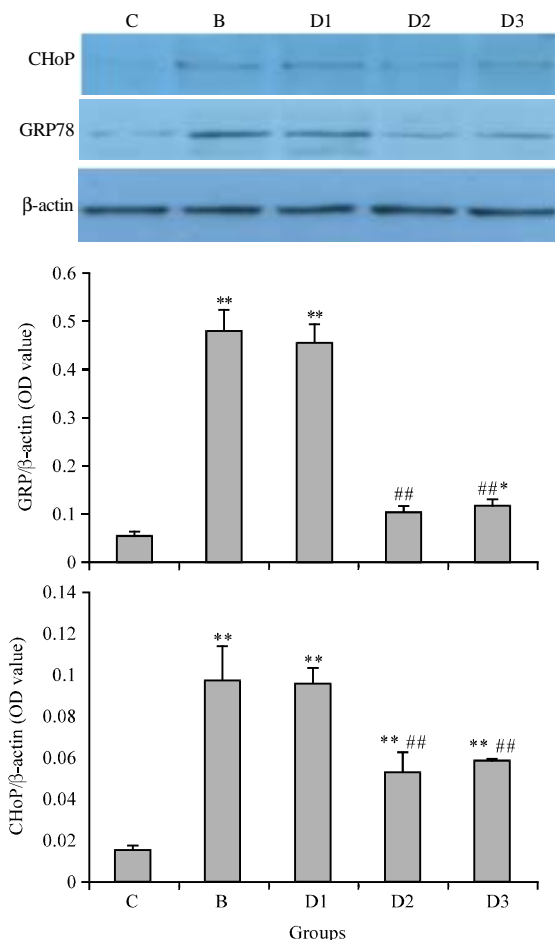


Fig. 3: The effect of dexmedetomidine on the proteinic expression of GRP78 and CHOP by Western blot assay; B: the simple scald group (the B group); C: the normal control group (the C group); D1: the 50 $\mu\text{g kg}^{-1}$ dexmedetomidine group (the D1 group); D2: the 30 $\mu\text{g kg}^{-1}$ dexmedetomidine group (the D2 group); D3: the 10 $\mu\text{g kg}^{-1}$ dexmedetomidine group (the D3 group) ** $p < 0.01$ vs. the normal control; * $p < 0.05$ vs. the D3 group; ## $p < 0.01$ vs. the B group

is thought to be due to peripheral α_2 -agonist with peripheral vasoconstriction. Hypotension and bradycardia occur more commonly with the initial loading dose with comorbid cardiovascular disease and with the coadministration of dexmedetomidine with other medications that have negative chronotropic effects (Tokuhira *et al.*, 2009). The impact of these effects must be considered especially for the patient with CHD. There are very limited data available describing the impact of dexmedetomidine on patients with myocardial damage induced by grave scald or burn (Ozaki *et al.*, 2014). In

contrast, for specific patient populations such as patients with myocardial damage induced by grave scald or burn, relative slowing of the heart rate may be beneficial.

Although, a more rapid administration of the bolus dose is not recommended for routine clinical practice, its hemodynamic effect has recently been investigated (Jooste *et al.*, 2010). To a cohort of 12 patients undergoing cardiac catheterization and surveillance biopsy after transplantation, dexmedetomidine in a dose of either 0.25 or 0.5 $\mu\text{g kg}^{-1}$ was administered over 5 sec. The investigators noted a statistically significant increase in diastolic and systolic blood pressure on both the systemic and pulmonary sides of the circulation together with a decrease in heart rate. The effect on the systemic circulation exceeded the effect on the pulmonary circulation. The effect on the diastolic blood pressure exceeded the effect on the systolic blood pressure in both circulations. These hemodynamic changes returned to baseline in 5 min. No change in cardiac output, central venous pressure or pulmonary vascular resistance was noted. Given its favorable sedative and anxiolytic properties together with its limited effects on hemodynamic and respiratory function there is growing interest in the use dexmedetomidine for the patient with myocardial ischemia-reperfusion injury and shock heart.

It was found that grave scald on the back of the rats could increase the HR, induce the myocardial damage by the assay of TUNELs and HE staining. It indicated that grave scald was closely related with myocardial damage which may be one of the precipitating factor of shock heart.

The studies demonstrated that dexmedetomidine could step down HR within the normal range, compared with the simple scald group which indicated that dexmedetomidine could prevent the heart from the damage of shock heart induced by scalding. On the other hand, dexmedetomidine could inhibit the expression of GRP78 (glucose-regulated protein 78) and caspase-12 induced by scalding, compared with the simple scald group. Dexmedetomidine could inhibit the myocardial cellular apoptosis also evidenced by the result of TUNELs assay.

It was reported that caspase-12 play an important role in myocardial ischemia-reperfusion injury by ERS (Endoplasmic Reticulum Stress) could interfere in the activity of ERS and caspase-12 excessively therefore, it may be the new drug target to prevent and cure the myocardial ischemia-reperfusion injury (Rao *et al.*, 2002; Nakagawa *et al.*, 2000; Tan *et al.*, 2006; Crosby *et al.*, 2007). Caspase-12 is in the endoplasmic reticulum as one of the plasmalemmal composite protein which is located in the hyalomitome of the endoplasmic reticulum as the form of inactive prosoma. It could be activated by

endoplasmic reticulum stress. ERS is one of the cellular self-care mechanism which could mediate the up-regulation of GRPs, CRT and protein foldase, enhance the capacity of cellular stress tolerance, recover the function of endoplasmic reticulum. However, excessive duration of ERS could lead to ERAD (Endoplasmic Reticulum Associated Dead) and the damage of myocardial tissue and cells. The activation of caspase-12 could make the ERS induce apoptosis all by itself which is the onset factor of apoptosis. Caspase-12 plays a critical role in the process of ERAD (Morishima *et al.*, 2002; Wang *et al.*, 2007). The inhibitory effect of dexmedetomidine on the expression of caspase-12 and GRP78 may be one of the mechanism of myocardial injury healing. GRP78 is also located in the endoplasmic reticulum, separated from the compound without binding to the unfold protein when ERS happens which could make the activation and release of caspase, leading to the myocardial apoptosis (Rao *et al.*, 2002). Excessive ERS could result in the clearance of the GRP78, caspase-7 and caspase-12 composites, inducing the myocardial apoptosis (Rao *et al.*, 2002).

CONCLUSION

In the study, it was found that the effect of 30 $\mu\text{g kg}^{-1}$ dexmedetomidine on the myocardial cellular apoptosis and HR induced by grave scald was the optimal among the three concentrations including 50, 30 and 10 $\mu\text{g kg}^{-1}$ dexmedetomidine. The effect of 30 $\mu\text{g kg}^{-1}$ dexmedetomidine on the expression of GRP78, CHOP and caspase-12 was also the optimal among the five groups. It indicated that 30 $\mu\text{g kg}^{-1}$ dexmedetomidine could be the optimal option for the treatment of the myocardial damage induced by grave scald or burn such as shock heart, compared with 50 and 10 $\mu\text{g kg}^{-1}$ dexmedetomidine.

REFERENCES

- Biccard, B.M., S. Goga and J. de Beurs, 2008. Dexmedetomidine and cardiac protection for non-cardiac surgery: A meta-analysis of randomised controlled trials. *Anaesthesia*, 63: 4-14.
- Crosby, K.M., B.J. Connell and T.M. Saleh, 2007. Estrogen limits ischemic cell death by modulating caspase-12-mediated apoptotic pathways following middle cerebral artery occlusion. *Neuroscience*, 146: 1524-1535.
- Ibacaache, M., G. Sanchez, Z. Pedrozo, F. Galvez and C. Humeres *et al.*, 2012. Dexmedetomidine preconditioning activates pro-survival kinases and attenuates regional ischemia/reperfusion injury in rat heart. *Biochim. Biophys. Acta (BBA)-Mol. Basis Dis.*, 1822: 537-545.
- Ji, F., Z. Li, H. Nguyen, N. Young, P. Shi, N. Fleming and H. Liu, 2013. Perioperative dexmedetomidine improves outcomes of cardiac surgery. *Circulation*, 127: 1576-1584.
- Jooste, E.H., W.T. Muhly, J.W. Ibinson, T. Suresh and D. Damian *et al.*, 2010. Acute hemodynamic changes after rapid intravenous bolus dosing of dexmedetomidine in pediatric heart transplant patients undergoing routine cardiac catheterization. *Anesth. Analg.*, 111: 1490-1496.
- Matko, I., E. Feher and E.S. Vizi, 1994. Receptor mediated presynaptic modulation of the release of noradrenaline in human papillary muscle. *Cardiovasc. Res.*, 28: 700-704.
- Maze, M. and W. Tranquilli, 1991. Alpha-2 adrenoceptor agonists: Defining the role in clinical anesthesia. *Anesthesiology*, 74: 581-605.
- Meibner, A., T.P. Weber, H. van Aken, K. Zbieranek and N. Rolf, 1998. Clonidine improves recovery from myocardial stunning in conscious chronically instrumented dogs. *Anesth. Analg.*, 87: 1009-1014.
- Morishima, N., K. Nakanishi, H. Takenouchi, T. Shibata and Y. Yasuhiko, 2002. An endoplasmic reticulum stress-specific caspase cascade in apoptosis cytochrome c-independent activation of caspase-9 by caspase-12. *J. Biol. Chem.*, 277: 34287-34294.
- Nakagawa, T., H. Zhu, N. Morishima, E. Li and J. Xu *et al.*, 2000. Caspase-12 mediates endoplasmic-reticulum-specific apoptosis and cytotoxicity by amyloid- β . *Nature*, 403: 98-103.
- Ozaki, M., J. Takeda, K. Tanaka, Y. Shiokawa and S. Nishi *et al.*, 2014. Safety and efficacy of dexmedetomidine for long-term sedation in critically ill patients. *J. Anesth.*, 28: 38-50.
- Porter, A.C., S.P. Svensson, W.D. Stamer, J.J. Bahl, J.G. Richman and J.W. Regan, 2003. Alpha-2 adrenergic receptors stimulate actin organization in developing fetal rat cardiac myocytes. *Life Sci.*, 72: 1455-1466.
- Rao, R.V., S. Castro-Obregon, H. Frankowski, M. Schuler and V. Stoka *et al.*, 2002. Coupling endoplasmic reticulum stress to the cell death program An Apaf-1-independent intrinsic pathway. *J. Biol. Chem.*, 277: 21836-21842.
- Riha, H., T. Kotulak, A. Brezina, L. Hess and L. Kramar *et al.*, 2012. Comparison of the effects of ketamine-dexmedetomidine and sevoflurane-sufentanil anesthesia on cardiac biomarkers after cardiac surgery: An observational study. *Physiol. Res.*, 61: 63-72.

- Roekaerts, P.M.H.J., F.W. Prinzen and S. De Lange, 1996a. Beneficial effects of dexmedetomidine on ischaemic myocardium of anaesthetized dogs. *Br. J. Anaesth.*, 77: 427-429.
- Roekaerts, P.M., F.W. Prinzen, H.M. Willigers and S. De Lange, 1996b. The effects of alpha2-adrenergic stimulation with mivazerol on myocardial blood flow and function during coronary artery stenosis in anesthetized dogs. *Anesth. Analg.*, 82: 702-711.
- Tan, Y., N. Dourdin, C. Wu, T. de Veyra, J.S. Elce and P.A. Greer, 2006. Ubiquitous calpains promote caspase-12 and JNK activation during endoplasmic reticulum stress-induced apoptosis. *J. Biol. Chem.*, 281: 16016-16024.
- Tobias, J.D., P. Gupta, A. Naguib and A.R. Yates, 2011. Dexmedetomidine: Applications for the pediatric patient with congenital heart disease. *Pediatr. Cardiol.*, 32: 1075-1087.
- Tokuhira, N., K. Atagi, H. Shimaoka, A. Ujio, Y. Otsuka and M. Ramsay, 2009. Dexmedetomidine sedation for pediatric post-Fontan procedure patients. *Pediatr. Crit. Care Med.*, 10: 207-212.
- Tosun, Z., M. Baktir, H.C. Kahraman, G. Baskol, G. Guler and A. Boyaci, 2013. Does dexmedetomidine provide cardioprotection in coronary artery bypass grafting with cardiopulmonary bypass? A pilot study. *J. Cardiothoracic Vasc. Anesth.*, 27: 710-715.
- Wang, X., B. Wang, Z. Fan, X. Shi, Z.J. Ke and J. Luo, 2007. Thiamine deficiency induces endoplasmic reticulum stress in neurons. *Neuroscience*, 144: 1045-1056.
- Xue, F.S., Y. Cheng and R.P. Li, 2013. Li RP. Safety of dexmedetomidine sedation in postoperative cardiac surgery patients. *Crit. Care*, Vol. 17. 10.1186/cc12724.
- Yoshitomi, O., S. Cho, T. Hara, I. Shibata, T. Maekawa, H. Ureshino and K. Sumikawa, 2012. Direct protective effects of dexmedetomidine against myocardial ischemia-reperfusion injury in anesthetized pigs. *Shock*, 38: 92-97.