

The Morphometric Properties of the Lumbar Spinal Cord Segments in Horses

M. Lutfi Selcuk and Sadullah Bahar
Department of Anatomy, Faculty of Veterinary Medicine,
Selcuk University, Konya, Turkey

Abstract: The aim of this study was to determine morphometric features of lumbar segments of the spinal cord of horses. Spinal cords of six horses from different breeds and sexes were used. Lumbar parts of the cords were dissected out from vertebral columns and segmentation was performed. Macroscopic measurements were done on the segments and then routine histological procedure was applied. Segments were sliced transversally at 3.8 mm thickness. Samples were cut at 10 µm thickness and stained with May-Grunwald-Giemsa. Slides images were used by stereo investigator. Diameter measurements were carried out and area and volume calculations were performed by using Cavalieri principle. The weight, length and volume ratios of the lumbar parts to spinal cord were 14.7, 13 and 14%, respectively. A decrease in lengths of the segments from L₁ to L₆ was observed. In the microscopic analysis, L₄ and L₅ had the biggest transverse diameters however L₆ had the largest vertical diameter. L₅ had the largest values of cross-sectional and white matter area however L₆ had the largest value of gray matter. Volumes of all segments except for L₆ were similar to each other and the largest volume of gray matter and the largest volume of white matter were observed in L₅ and L₃, respectively. It was determined that the volume ratio of gray matter to the volumes of segments increased from L₁ to L₆ whereas volume of white matter was decreased in those segments. In conclusion, the data obtained will contribute to the morphology of related region and the further studies.

Key words: Cavalieri principle, spinal cord, lumbar segments, segmental morphometry, gray matter

INTRODUCTION

Lumbar section of the spinal cord in horses is important for being both a moving part of the spine and an exit zone for the important nerves. Spinal cord diseases which are locally (compressive) effective and causing morphometric changes in segments have a special importance due to their high prevalence, clinic symptoms and the often poor prognosis (Malikides *et al.*, 2007; Laugier *et al.*, 2009; Levine *et al.*, 2010). Consequently, segmental morphometric data in healthy animals, provides valuable help to physician in the treatment of diseases. The topographic relationship between spinal cord segments and vertebrae are clinically very important regarding the diagnosis of diseases of the nervous system related to the area (Habel, 1951). In the diagnosis and prognosis follow-up of these diseases in horses as well as radiography, medical imaging techniques (MRI, CT) are also used in the recent years. In these diagnostic methods, just as in histopathological methods, morphometric evaluations of spinal cord and some of the surrounding tissues are frequently used (Fujiwara *et al.*, 1988; Hudson and Mayhew, 2005; Claridge *et al.*, 2010).

The different morphometric aspects of spinal cord segments of human and animal species (length, diameter, cross section, volume, etc.) were revealed in various studies. These researches can be divided into three groups according to their methodologies such as macroscopic (Thomas and Combs, 1962, 1965; Ko *et al.*, 2004) the microscopic (Kameyama *et al.*, 1996; Portiansky *et al.*, 2004; Turgut *et al.*, 2007) medical imaging (Sherman *et al.*, 1990; Da Costa *et al.*, 2006). In the third group as the segment borders cannot be separated clearly in spinal cord, the vertebral border were taken into account or manual segmentation was performed (Sherman *et al.*, 1990; Van Uiter *et al.*, 2005; Claridge *et al.*, 2010). In the first two groups which the segmentation was carried out clearly, it was observed that diameter and cross-section measurements were done on a particular region of the segment or on a single sample taken from a midpoint length.

After 1980s, stereological techniques are frequently used in unbiased and high-accuracy calculations of volume, surface area, length and number parameters of tissues which basically depends on sampling biological tissue effectively (Mouton, 2002; Howard and Reed, 2005). These techniques are often used especially in the

calculation of volume in the brain, cortical surface area and number of cells (West, 1993; Zarow *et al.*, 2004). Studies carried out on spinal cord by using this technique on rats (Bjugn and Gundersen, 1993) and chicks (Turgut *et al.*, 2007) some information, albeit limited is given on the segment morphometry.

The aim of this study was to determine morphometric properties of lumbar segments of spinal cord in horses such as length, diameter, weight, volume and volume ratios (gray matter, white matter, central canal).

MATERIALS AND METHODS

The research was conducted between 2008 to 2009 on 6 cadaver animals (1 pony weight 230 kg; age 15 female, 2 Arabian horses ages 13 and 15; weights 300-340 kg female, 1 Belgian age 15; weight 480 kg, 2 English ages 10 and 12; weights 420-450 kg male) Selcuk University, Faculty of Veterinary Medicine from Equestrian Facility which were decided for euthanasia due to various orthopedic disorders and allocated to the Department of Anatomy for the application of this decision and for the preparation of cadaver. The research procedure was approved by Selcuk University, Faculty of Veterinary Medicine Ethics Committee (Decision No.: 2011/015-2011/03).

Dissection and segmentation: In the dissection process, initially soft tissues were dissected from atlas to caudal vertebrae on the dorsal of vertebral column. Following this procedure, arcus vertebrae of the vertebral column forming vertebral column was removed and spinal cord was revealed by using laminectomy. Spinal nerves from C₁ to filum terminale were removed by incision from the surface leaving the vertebral canal and spinal cord was removed, protecting the dura mater. Before starting the segmentation process, dura mater spinalis and arachnoidea spinalis was opened from the dorsal. Starting from C₁ segmentation was implemented to the whole spinal cord except caudal segments. The midpoint of the distance between dorsal root of the consecutive spinal nerve was considered as the segment border lumbar segments were separated from each other by making transversal cuts from this area.

Macroscopic measurements: Following the segmentation procedure, weight, length, transverse and vertical diameters (from the middle part of the segment) of the animals were determined with digital caliper and the volume was determined with Archimedes Method.

Lumbar segments sampling and histological process: Lumbar segments were sliced transversally suitable for histological processing. For the slicing process, a tissue

slicer prepared in the laboratory using microtome blades ranging between 3.8 mm. Segments were placed perpendicular to blades on this tissue slicer, the first 3.8 mm section was placed randomly and slicing process was carried out. At the end of this process, a number of samples were taken from these segments ranging from 5-14. The samples were placed on histologic process trays taking the cranial surface into consideration. Paraffin blocks were prepared from the regularly histologically followed-up samples from the cross-section to their cranial surfaces. One of the 10 µm from first 30 sections was taken randomly to gelatinous lam by using rotary microtome (RM 2125 RT, Leica, Nussloch, Germany). The sections were oven-dried at 37°C for 24 h and then staining with May Grunwald-Giemsa. In order to measure the diameter of the sectional images obtained in the study, the cross sections were imaged in JPG 2000 format by using Stereo Investigator (Version 10.0, Inc. MicroBrightField) virtual slice module.

Microscopic measurements: Transversal and vertical diameters of segments were measured by using ImageJ Software and the data was recorded.

Area and volume calculations in segments: Area and volume measurements (spinal cord, white matter, gray matter, central canal) were carried out on images taken under 2.5x objective by using virtual slice module. For the volume calculations, Stereo-Investigator estimator cavalieri probe was utilized. For this purpose, pointed area measurement ruler with different point frequency (for spinal cord 2 mm for gray matter 1 mm and for central canal 60 µm) was placed on cross-sectional images. A different marker for each area was selected and the spots marked on the areas were counted separately. Images obtained from each segment point numbers were divided to the number of cross-sections and the average cross-section areas of structures focused on the segments were determined. The volumes of focused structures on the segments were calculated separately with using equation (Gundersen *et al.*, 1999); Yucel *et al.*, 2003; Howard and Reed, 2005):

$$V = \left(\frac{a}{p} \right) \times \sum_p \times t$$

Where:

V = Volume of the focused sample

a/p = Area in the measurement table of a dotted point

Σ_p = Total number of points on the focused structure

t = The average cross-section thickness (3, 4 mm)

The volume of whole segment was calculated with $V_{Total} = V_1 + V_2 + \dots + V_n$ equation (Bjugn and Gundersen, 1993):

In the research, the area and the volume of white matter were calculated by subtracting the area and the volume of gray matter and central canal from the whole spinal cord.

Proportioning an anatomical structure located within the reference volume to the reference volume is a frequently used important parameter (Gundersen, 1986; Gundersen *et al.*, 1988; Howard and Reed, 2005). In the research, area (Eq. 1) and volume (Eq. 2) proportions of whole segment on the gray matter, white matter and central canal segment basis were calculated with the following equation:

$$V_A(X,Y) = \frac{\text{Area of X' in Y'}}{\text{Area of Y'}} \times 100 \quad (1)$$

$$V_V(X,Y) = \frac{\text{Area of X' in Y'}}{\text{Area of Y'}} \times 100 \quad (2)$$

Where:

X = The area (volume) of gray matter

Y = The area (volume) of spinal cord

The point counts marked on gray matter and spinal cord can be used instead of volume (Turgut *et al.*, 2007):

$$V_V(\text{gray matter, spinal cord}) = \frac{\Sigma_p \text{ gray matter}}{\Sigma_p \text{ spinal cord}}$$

Where:

Σ_p gray matter = The sum of all points corresponding to the gray matter

Σ_p spinal cord = The total number of points corresponding on the spinal cord

Determination of Coefficient Error (CE) in volume calculations: Particularly in volume measurements, error coefficient value is preferred to be equal to or smaller than 10%. In stereology studies, more than one methods are used for error coefficient calculation. In this study, the following coefficient by Gundersen *et al.* (1999) was used:

$$CE = \frac{\sqrt{\Sigma_{var}}}{\Sigma_p}$$

$$\Sigma_{var} = \text{Noise} + \text{Var}_{SRS}$$

$$\text{Noise} = 0.0724 \times \frac{b}{\sqrt{a}} \times \sqrt{n \times \Sigma_p}$$

$$\text{Var}_{SRS} = \sum_{i=1}^n a = \frac{3 \times (A - \text{Noise}) - 4 \times (B + C)}{12}$$

$\text{Var}_{SRS} = \Sigma_{i=1}^n a$ = Indicates the statistically significant variability of systematic random sampling in all areas. In this equation, noise represents the complexity of the cross-section areas taken from spinal cord whereas b/\sqrt{a} represents the edge complexity of the areas of the focused structures of cross-section. In the equation, b = edge length and a = area of the cross-section. The number 0.0724 in the formula is a number used in the calculation of complexity, Σ_p represents the total number of points on cross-sections (Gundersen and Jensen, 1987; West, 1993; Ohm *et al.*, 1997; Gundersen *et al.*, 1999; Garcia-Finana *et al.*, 2003).

Statistical analysis: The morphometric data obtained in this study from the segment length, diameter, area and volume were evaluated using Duncan test (SPSS 17.0). The $p < 0.05$ value of was considered the significance limit.

RESULTS

The animal body weights, all weights of spinal cord and lumbar part of spinal cord their lengths and volumes and the ratios related to these morphometric data in the study were given in Table 1.

The length measurements of lumbar segments before and after histological process were given in Fig. 1. As a result of macroscopic and microscopic length measurements, it was found that the segment lengths have shortened in an average of 12.43% affected by the histological process.

The (average) transversal and vertical diameter measurements of segments done before and after histological processes were given in Fig. 2, the (average) diameter measurements of central canal done after histological processes were given in Fig. 3. The

Table 1: Some morphometric values of the animals used in the study

Parameters	Mean±SE
Body weight (kg)	370.0±39.3
Spinal cord	
Weight (g)	244.0±19.4
Length (cm)	167.1±6.2
Volume (cm ³)	242.2±19.5
Lumbar spinal cord	
Weight (g)	35.5±2.4
Length (cm)	22.5±0.8
Volume (cm ³)	35.1±2.7
Ratio lumbar part/spinal cord	
Weight	14.7±0.5
Length	13.5±0.5
Volume	14.5±0.3
Relative weight	
Spinal cord	0.068±0.004
Lumbar part	0.010±0.001

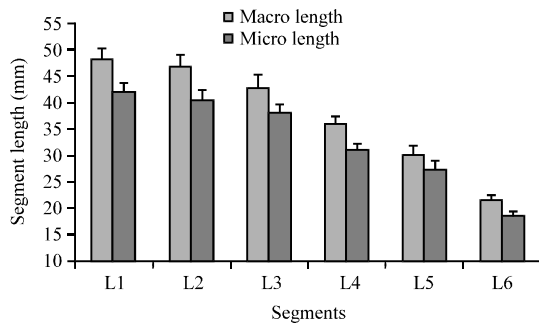


Fig. 1: The measured lengths of lumbar segments before (macroscopic) and after (microscopic) histological process (Mean±SE)

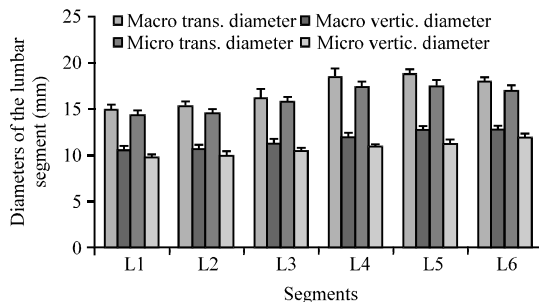


Fig. 2: The measured diameters of lumbar segments before (macroscopic) and after (microscopic) histological process (Mean±SE)

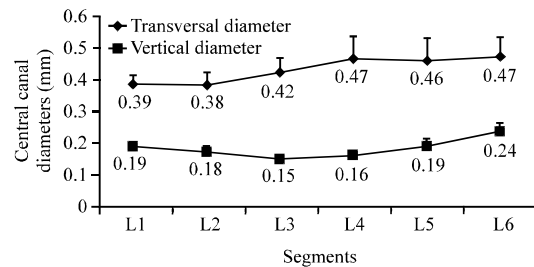


Fig. 3: Transversal and vertical diameters of the central canal (Mean±SE)

transversal and vertical tissue shrinkage ratios formed in segments before and after histological process were 5.1 and 7.8%, respectively.

The average cross-section, the gray matter, white matter and central canal volumes in all lumbar segments were given in Table 2. All the segments and the gray matter areas in L₆ and the white matter area in L₅ was found to be the highest ($p < 0.05$). No statistically significant difference was detected in central canal area between the segments. The ratios of gray and white matter and central canal to the entire cross-sectional area

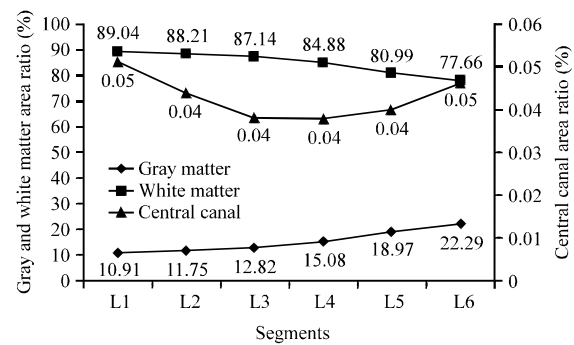


Fig. 4: The area ratios of gray matter, white matter and central canal in lumbar segments

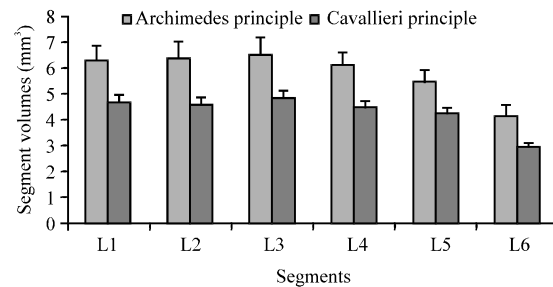


Fig. 5: Segment volumes determined with Archimedes and Cavalieri principles (Mean±SE)

Table 2: The average cross-section, the gray matter, white matter and central canal areas in the lumbar segments (Mean±SE)

Segments	Cross-sectional area (mm²)	Gray matter (mm²)	White matter (mm²)	Central canal (mm²)
L1	111.2±4.1 ^b	12.1±0.5 ^a	99.0±3.7 ^c	0.057±0.005
L2	114.0±2.2 ^b	13.4±0.7 ^{ab}	100.6±2.0 ^c	0.050±0.006
L3	127.6±5.2 ^b	16.4±0.6 ^d	111.2±5.0 ^{bc}	0.048±0.009
L4	145.5±6.3 ^a	21.9±1.2 ^e	123.5±5.3 ^{ab}	0.055±0.016
L5	158.8±6.9 ^a	30.1±2.0 ^f	128.6±5.3 ^a	0.063±0.017
L6	159.1±8.0 ^a	35.5±1.6 ^f	123.6±6.9 ^{ab}	0.073±0.014

^{a-f}The different letters in the same column are statistically significant ($p < 0.05$)

in the segments were given in Fig. 4. It was observed that gray matter ratio increased from L₁ towards L₆ while white matter ratios decreased.

The volume measurements of segments made with Archimedes principle and volume values calculated with Cavalieri principle were given in Fig. 5. A difference of 26.2% between the two results was recorded as the tissue shrinkage formed in lumbar segments of the spinal cord.

Total segment, gray and white matter and central canal volume values calculated after the histological procedures in lumbar segments were given in Table 3. While it was observed that gray matter volume in L₅ and white matter volume in L₃ was highest, no statistically significant difference was observed in central canal between the segments ($p > 0.05$).

Table 3: The segment, the gray and white matter and central canal volumes in lumbar spinal cord (Mean±SE)

Segments	Segment volume (cm ³)	Gray mat. (cm ³)	White mat. (cm ³)	Central canal (mm ³)
L ₁	4.68±0.74 ^a	0.51±0.09 ^d	4.16±0.66 ^{ab}	2.34±0.52
L ₂	4.60±0.67 ^a	0.54±0.09 ^{cd}	4.06±0.61 ^{ab}	2.01±0.33
L ₃	4.85±0.74 ^a	0.62±0.08 ^{bc}	4.23±0.69 ^a	1.84±0.85
L ₄	4.53±0.57 ^a	0.68±0.09 ^b	3.85±0.49 ^{ab}	1.71±1.00
L ₅	4.28±0.49 ^a	0.80±0.07 ^a	3.47±0.45 ^b	1.68±1.07
L ₆	2.96±0.34 ^b	0.66±0.06 ^b	2.30±0.30 ^c	1.31±0.56

^{a-d}The different letters in the same column are statistically significant (p<0.05)

CE values obtained in the study as a result of volume measurements for total segment, white matter, gray matter and central canal were found to be 4.6, 4.9, 5.3 and 2.9%, respectively.

DISCUSSION

Mayhew reported that the spinal cord length of a horse weighing 500 kg is approximately 200 cm. These values in this study were 370±39 kg and 167.1±6.2 cm. Nickel reported that the spinal cord length of the horses was 160-200 cm and the weight was 250-300 g. The findings are parallel with Mayhew and Nickel.

In the presented study, the weight of lumbar spinal cord was 35.5±2.4 g, the length was 22.5±0.8 cm and the volume was 35.1±2.4 cm³. The lumbar spinal cord length in donkeys was reported as 12.1 and 11.1 cm in Angora goats, 10.8-13.9 cm in deer (Lima *et al.*, 2010).

It was reported that 11.3% of the spinal cord length was lumbar part in donkeys, 20.7% in the Angora goat, 18.9-21.1% in deer (Lima *et al.*, 2010) and 13.6% in humans (Barson and Sands, 1977). In the study, this value was determined as 13.5±0.5% and this was similar to humans. Regarding the segment lengths forming the lumbar part, the longest segment in horses donkeys and humans (Ko *et al.*, 2004) and in monkeys was L₁ (Thomas and Combs, 1965) and this segment lengths were shortened in a regular basis towards the last segment. The data obtained in the current study were found to be compatible with horses, donkeys, humans and apes. However in Angora goats, L₃ was reported as the longest segment.

Braun reported the highest and the lowest values of transversal diameters in lumbar segments were lumbar transverse diameter in the direction of the segment's largest and smallest values as L_{2,3} and L₆, respectively and in the vertical diameters as L₆ and L_{2,3}, respectively. In the presented study, the highest and the lowest transversal diameters were L₅ and L₂, respectively and in the vertical diameter L₆ and L₁, respectively. The current difference between the two studies is thought to be to arise from the methodological differences and the material used.

In studies on spinal cord of horses, transversal and vertical diameters of central canal from L₁ towards L₆ was reported as 480, 570, 710, 700, 780, 760 and 110, 20,

30, 90, 120, 560 µm. And in the presented study these morphometric values were 387±0.03, 383±0.04, 423±0.05, 467±0.07, 462±0.07, 473±0.06 µm and 190±0.01, 175±0.02, 152±0.01, 163±0.02, 193±0.02, 236±0.03, respectively and found that they were not in accordance with the data by Braun. The difference is thought to be derived from methodological differences used in the research or racial differences and the differences in the number of animals. In donkeys these diameters were reported as 378, 320, 320, 243, 230 and 128, 77, 90, 134, 192 µm. Evaluating these three studies in terms of vertical diameters it was found that these values were high in the first and the third segments and lower in the middle segments. It was concluded that this might be due to the enlargement of spinal cord in this area.

Cross section, gray matter and matter areas and area ratios of spinal cord in lumbar segments were presented as a parameter on studies carried out on horses donkeys monkeys (Thomas and Combs, 1965) humans (Ko *et al.*, 2004) and rats (Portiansky *et al.*, 2004). In the study, it was determined that the average cross-section area increased from L₁ towards L₆ in regular basis however as a result of the statistical analysis L₁, L₂ and L₃ among each other and L₄, L₅, L₆ among each other were found to be similar. Regarding the area ratios, the area ratios between gray matter and white matter were inversely proportional from cranial towards caudal. This result was found to be similar to donkeys but not to horses, monkeys, humans and rats. As a result of the literature studies, no information was found regarding the area and volume of central canal. The morphometric data relating to these anatomical structures (Fig. 3, 4 and Table 2, 3) were given in this research for the first time in detail.

In humans (Ko *et al.*, 2004) and monkeys (Thomas and Combs, 1965) as a result of the macroscopic measurements, it was found that lumbar segment values decreased from cranial towards caudal. In the study, this morphometric data was obtained with macroscopic (Archimedes principle) and microscopic (Cavalieri principle) measurements and found to be in accordance with humans and monkeys.

The error coefficient in volume calculations done with Cavalieri principle was 10% and lower and this was an important parameter regarding the reliability of the study (Gundersen and Jenson, 1987; Gundersen *et al.*, 1999; Garcia-Finana *et al.*, 2003). In the study, this value was calculated separately for segment, gray matter, white matter and central canal and found that the values obtained were reliable.

CONCLUSION

When the study results evaluated the following conclusions were obtained. The morphometric studies on

spinal cord were limited in the literature and no morphometric information was acquired except some few parameters. Whereas it is obvious that these morphometric data would be very helpful in the diagnosis of spinal cord diseases and treatment. The data obtained and presented at the end of the research will contribute to correct the deficiencies on this subject. In the study, morphometric measurements were done before (macroscopic) and after (microscopic) histological procedures on spinal cord and these values were presented separately in figures and tables. This information will contribute significantly to the future studies on this subject. Stereological methods in the determination of morphometry (area and volume) of segments of lumbar part in spinal cord were successfully implemented for the first time in this study and this will contribute significantly to the future studies on this subject. Segment lengths of lumbar part decreased from cranial towards caudal but this was not observed in segment diameters and volumes, volume ratios increased except gray matter and decrease was observed in white matter and central canal volume ratios.

ACKNOWLEDGEMENTS

This research was summarized from the researchers M.Sc. thesis. The research abstract was presented and published in National Congress of Veterinary Anatomy, Side/Antalya 2011.

REFERENCES

- Barson, A.J. and J. Sands, 1977. Regional and segmental characteristics of the human adult spinal cord. *J. Anat.*, 123: 797-803.
- Bjugn, R. and H.J. Gundersen, 1993. Estimate of the total number of neurons and glial and endothelial cells in the rat spinal cord by means of the optical dissector. *J. Comp. Neurol.*, 328: 406-414.
- Claridge, H.A.H., R.J. Piercy, A. Parry and R. Weller, 2010. The 3D anatomy of the cervical articular process joints in the horse and their topographical relationship to the spinal cord. *Equine Vet. J.*, 42: 726-731.
- Da Costa, R.C., J.M. Parent, G. Partlow, H. Dobson, D.L. Holmberg and J. LaMarre, 2006. Morphologic and morphometric magnetic resonance imaging features of Doberman Pinschers with and without clinical signs of cervical spondylomyelopathy. *Am. J. Vet. Res.*, 67: 1601-1612.
- Fujiwara, K., K. Yonenobu, K. Hiroshima, S. Ebara, K. Yamashita and K. Ono, 1988. Morphometry of the cervical spinal cord and its relation to pathology in cases with compression myelopathy. *Spine*, 13: 1212-1216.
- Garcia-Finana, M., L.M. Cruz-Orive, C.E. Mackay, B. Pakkenberg and N. Roberts, 2003. Comparison of MR imaging against physical sectioning to estimate the volume of human cerebral compartments. *Neuroimage*, 18: 505-516.
- Gundersen, H.J. and E.B. Jenson, 1987. The efficiency of systematic sampling in stereology and its prediction. *J. Microsc.*, 147: 229-263.
- Gundersen, H.J., 1986. Stereology of arbitrary particles. A review of unbiased number and size estimators and the presentation of some new ones, in memory of William R. Thompson. *J. Microsc.*, 143: 3-45.
- Gundersen, H.J., E.B. Jensen, K. Kieu and J. Nielsen, 1999. The efficiency of systematic sampling in stereology-reconsidered. *J. Microsc.*, 193: 199-211.
- Gundersen, H.J.G., P. Bagger, T.F. Bendtsen, S.M. Evans, L. Korbo and N. Marcussen *et al.*, 1988. The new stereological tools: Disector, fractionator nucleator and point sampled intercepts and their use in pathological research and diagnosis. *APMIS*, 96: 857-881.
- Habel, R., 1951. The topography of the equine and bovine spinal cord. *J. Am. Vet. Med. Assoc.*, 118: 379-382.
- Howard, V. and M. Reed, 2005. *Unbiased Stereology: Three-Dimensional Measurement in Microscopy*. Garland Science, Oxon, UK.
- Hudson, N.P.H. and I.G. Mayhew, 2005. Radiographic and myelographic assessment of the equine cervical vertebral column and spinal cord. *Equine Vet. Educ.*, 17: 34-38.
- Kameyama, T., Y. Hashizume and G. Sobue, 1996. Morphologic features of the normal human cadaveric spinal cord. *Spine*, 21: 1285-1290.
- Ko, H.Y., J.H. Park, Y.B. Shin and S.Y. Baek, 2004. Gross quantitative measurements of spinal cord segments in human. *Spinal Cord*, 42: 35-40.
- Laugier, C., J. Tapprest, N. Foucher and C. Sevin, 2009. A necropsy survey of neurologic diseases in 4,319 horses examined in normandy (France) from 1986 to 2006. *J. Equine Vet. Sci.*, 29: 561-568.
- Levine, J.M., P.V. Scrivani, T.J. Divers, M. Furr and I.J. Mayhew *et al.*, 2010. Multicenter case-control study of signalment, diagnostic features and outcome associated with cervical vertebral malformation-malarticulation in horses. *J. Am. Vet. Med. Assoc.*, 237: 812-822.

- Lima, F., A.L.Q. Santos, B.C. Lima, G.V. Vieira and L.Q.L. Hirano, 2010. Topographic anatomy of the spinal cord and vertebromedullary relationships in Mazamagouazoubira (*Artiodactyla: Cervidae*). *Biol. Sci.*, 34: 189-194.
- Malikides, N., D.R. Hodgson and R.J. Rose, 2007. Neurology. In: *Manual of Equine Practice*, Rose, R.J. and D.R. Hodgson (Eds.). 2nd Edn., Elsevier, New York.
- Mouton, P.R., 2002. *Principles and Practices of Unbiased Stereology*. John Hopkins University Press, Baltimore, Maryland, USA., ISBN: 9780801867972, Pages: 214.
- Ohm, T.G., C. Busch and J. Bohl, 1997. Unbiased estimation of neuronal numbers in the human nucleus coeruleus during aging. *Neurobiol. Aging*, 18: 393-399.
- Portiansky, E.L., C.G. Barbeito, R.G. Goya, E.J. Gimeno and G.O. Zuccolilli, 2004. Morphometry of cervical segments grey matter in the male rat spinal cord. *J. Neurosci. Methods*, 139: 217-229.
- Sherman, J.L., P.Y. Nassaux and C.M. Citrin, 1990. Measurements of the normal cervical spinal cord on MR imaging. *Am. J. Neuroradiol.*, 11: 369-372.
- Thomas, C.E. and C.M. Combs, 1962. Spinal cord segments. A. Gross structure in the adult cat. *Am. J. Anat.*, 110: 37-47.
- Thomas, C.E. and C.M. Combs, 1965. Spinal cord segments. B. Gross structure in the adult monkey. *Am. J. Anat.*, 116: 205-216.
- Turgut, M., A.T. Tunc, H. Aslan, A.C. Yazici and S. Kaplan, 2007. Effect of pinealectomy on the morphology of the chick cervical spinal cord: A stereological and histopathological study. *Brain Res.*, 1129: 166-173.
- Van Uitert, R., I. Bitter and J.A. Butman, 2005. Semi-automatic spinal cord segmentation and quantification. *Int. Congress Ser.*, 1281: 224-229.
- West, M.J., 1993. New stereological methods for counting neurons. *Neurobiol. Aging*, 14: 275-285.
- Yucel, F., N. Unal, M. Ercakir and G. Guven, 2003. Determination of age-related volume changes in rat brain by Cavalieri's Method. *Erciyes Med. J.*, 25: 179-185.
- Zarow, C., T.S. Kim, M. Singh and H.C. Chui, 2004. A standardized method for brain-cutting suitable for both stereology and MRI-brain co-registration. *J. Neurosci. Methods*, 139: 209-215.