

Intraurethral Uttarbasti Application for Urethral Injury in Rats

Fatih Rustu Yalcinkaya, Mursel Davarci, Ahmet Gokce, Esref Oguz Guven, Mehmet Inci, Mustafa Kerem, Ali Ayyildiz, Rajendra Haribhau Amilkanthwar and Ayper Kacar
Department of Urology, Faculty of Medical, Mustafa Kemal University,
31100 Hatay, Turkey

Abstract: Urethral stricture is an illness that can be repeated and that has a troublesome treatment process. Uttarbasti which is used in traditional Indian wound healing is a mixture consisting of rock salt, honey and sesame oil. In traditional treatment, there are studies about the effects of honey, wax and sesame oil on wound healing. Researchers aimed at searching the efficiency of the treatment by using uttarbasti in urethral stenosis. In the experiment 18 Wistar Albino type rats which are around 200-250 g were used. These rats were divided into 3 groups and each has 6 rats. Urethra was marked till external meatus with 18G sting. To the 1st group, not any drug was given. To the 2nd group, for 3 weeks saline (1 cc) was given into urethra. To the 3rd group for 3 weeks uttarbasti (1 cc) was applied into urethra. At the end of the 3rd week, all the groups were decapitated. They were taken into histopathological search with their penis tissue and urethra.

Key words: Uttarbasti, intraurethral, urethra, urethral stricture, wound healing, rats

INTRODUCTION

Urethral injuries commonly cause scar structures narrowing the urethral lumen and resulting in strictures. In such cases, urethral dilatation, intermittent catheterization, internal urethrotomy, impermanent or permanent stent application, laser application, balloon dilatation and open surgery can be used as the option of therapy (Hafez *et al.*, 2005). The open surgery is not applicable in all centers since, it requires more skills (Andrich and Mundy, 2000). Although, they have significant recurrence rates, internal urethrotomy and urethral dilatation are the most commonly used methods for the treatment of urethral strictures (Andrich and Mundy, 2000). Prevention of the scar tissue formation is the main goal in treatment procedure. Therefore, oral and intraurethral materials have been used previous clinically and experimentally study (Ayyildiz *et al.*, 2004).

Wound repair is a process which begins with inflammation and ends with the formation of scar tissue. This condition is a complicated occurrence which includes extracellular matrix, cells, growth factors and cytokines (Da-Silva *et al.*, 2002). Mainly significant factors for the formation of scar tissue are the aggregation and proliferation of fibroblasts in the wound and the increases in the accumulation of other extracellular matrix components such as collagen and Glycosaminoglycans (GAG) (Da-Silva *et al.*, 2002).

The extracellular matrix plays a significant function in the biophysical possessions of the tissue during the repair period. While the prevalent GAG in the extracellular matrix is the hyaluronic acid, the dermatan sulphate becomes prevalent during urethral repair process (Da-Silva *et al.*, 2002). Ayyildiz *et al.* (2007) got successful results in urethral stricture treatment with intraurethral honey application.

In previous study, researcher applied uttarbasti in urethral stricture in human and it was confirmed the curative role of uttarbasti in urethral stricture (Amilkanthwar and Rajendra, 2004). In this study, researchers applied uttarbasti which consists of honey, sesame oil and rock-salt and is used in traditional Indian wound healing treatment (Anonymous, 1000 BC).

MATERIALS AND METHODS

After the approval of the local ethics committee, a total of 18 Wistar albino male rats (200-250 g) were anaesthetized with a combination of ketamine-xylazine intraperitoneally. The urethral damage was created with a 29 G needle which was given a shape of a hook by scratching the ventral surface of the urethral epithelium starting from approximately 0.5 cm proximal to external meatus (Ayyildiz *et al.*, 2007). The rats were then randomly divided into three groups: 6 rats were allocated into the control group (Group 1), 6 rats into the sham group

(Group 2), 6 rats into the group where uttarbasti was applied intraurethraly with a canule every weeks for 3 week (Group 3). Both uttarbasti ($1200 \text{ mosmol kg}^{-1}$) and saline solutions ($300 \text{ mosmol kg}^{-1}$) were applied 1 mL in every application.

The rats were housed in individual cages in a temperature ($22-24^{\circ}\text{C}$), humidity (50-55%) and light-dark cycle controlled room (12 h/12 h of light and dark) with free access to food and water for 3 weeks. Water was changed daily. Sterilized dust-free wood shavings were used as bedding material and changed three times per week. At the end of 3 weeks, rats were killed under an excessive dose of pentobarbital sodium (100 mg kg^{-1} , intraperitoneal) and penectomy was carried out with a lancet from the proximal of the injured region. The penectomy materials of all groups were placed separately into 10% formol.

All the penile materials were included totally after sectioning transversally at 0.5 mm intervals from glans penis to proximally then embedded in paraffine blocks and stained with H-E and Masson Trichrome. All specimens were investigated under light microscopy in order to evaluate the urethral diameter, luminal narrowing, architectural distortion, epithelial injury, fibrosis, bleeding and inflammation.

Urethral diameter was measured by means of an oculometry. Two measurements were taken in the midportion of every specimen and for each measurement the largest two cross section were taken into account. Then for each specimen the average is calculated for the narrowest portion. Luminal narrowing was considered when no space was left between any two sides of the lumen. Architectural distortion was either in the form of complete or incomplete occlusions or irregular fibrous thickenings with significant change in the shape of the urethra. Epithelial injury was determined in presence of focal erosions and bleeding was detected intraluminally and/or in the form of extravasated erythrocytes. Old bleeding was considered when hemosiderin-laden macrophages were seen in the vicinity. Fibrosis was found mostly in the form of periurethral irregular thickenings that sometimes cause distortions in the shape. Inflammation was noted when there were lymphocytic and/or granulocytic infiltrations of the epithelium and/or subepithelial tissue.

Statistical analysis: The statistical data were analyzed using Statistical Package for the Social Sciences (SPSS, Chicago, IL, USA) Version 12.0 for Windows. All values were expressed as mean \pm SD. The differences between two groups were carried out using test of Mann-Whitney U. $p < 0.05$ was considered statistically significant.

RESULTS AND DISCUSSION

In Group 1, the histopathologic features such as urethral epithelium and connective tissue irregularities, narrowing of urethral lumen, papillary formation were present in all rats. Hyperemia-bleeding was found in five rats and was absent in one rat in which no inflammation and no healing was observed (Fig. 1). In Group 2, regularity in urethral epithelium was observed in two rats and regularity in the connective tissue was present in one rat. While narrowing of urethral lumen and papillary formations were present in six rats (Fig. 2). When Group 2 was compared with Group 1, no significant difference was observed according to the same parameters ($p > 0.05$). In Group 3 when compared with Group 2, increase in urethral stricture was observed ($p < 0.05$) (Fig. 3).

Urethral stricture is either post traumatic or post inflammatory. Trauma may be iatrogenic or external. Inflammation is due to UTI, most commonly Gonococcal infection. Abundant smooth muscle and elastic tissue is

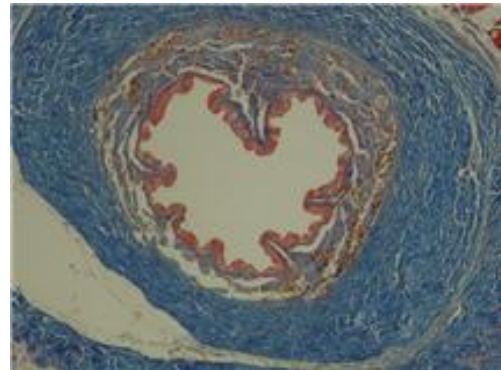


Fig. 1: MTRx100, no fibrous thickening, no luminal narrowing, no epithelial injury. Total healing is achieved

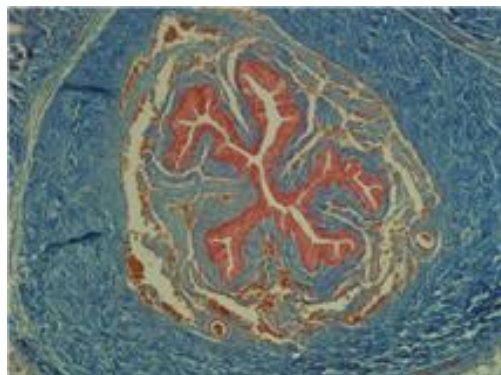


Fig. 2: MTRx100, periurethral fibrous thickening and luminal narrowing and epithelial injury

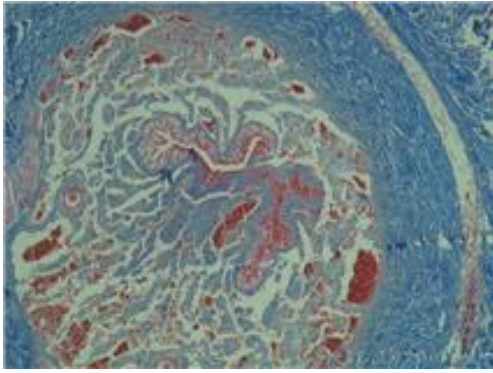


Fig. 3: H-Ex100, total obstruction of the urethra. No healing

found in the postinflammatory strictures. The scar tissue from post-traumatic strictures merely shows dense collagen.

An anatomical basis for the well known difference between the fibrous and the resilient stricture is demonstrated (Hafez *et al.*, 2005). As urethral stricture is a surgical entity, the recent approach of treatment is also surgical. Recent modes of treating urethral stricture include periodic dilatation of urethra, urethrotomy and urethroplasty (Hafez *et al.*, 2005).

Several chemicals and substances have been investigated in urethral injuries until now. Transurethral triamcinolone, hydrocortisone-furacin combination have been clinically used and tumour growth factor- β oligodeoxynucleotide, halofuginone, recombinant viral solution carrying reporter gene and mitomycin-C have been experimentally applied intraurethally for the prevention of urethral scarring (Kumar *et al.*, 2004).

Ayyildiz *et al.* (2007) in their study with intraurethral honey application, found the positive effect of honey treatment on urethral stricture. Uttarbasti is a non invasive approach to the treatment of urethral stricture to break this cycle. It requires no instrumentation as only medicated oil is instilled through urethra. Sesame oil acts as a medium for other ingredients and also softens tissue, increases elasticity, penetrates up to deep tissue, promotes regeneration and healing (Amilkanthawar and Rajendra, 2004; Anonymous, 1000 BC). This action has been described in Ayurved. Sesame oil enhances re-epithelialization and repair by providing required nutrients and low partial pressure of oxygen as well as removing necrotic tissues through its unique drainage mechanism (Cho *et al.*, 2007).

Honey is constituted of mono and disaccharides such as fructose, glucose and maltose, hydrogen peroxide, enzymes, growth factors, tissue nourishing

minerals and vitamins. The natural acidic pH and osmotic and hygroscopic effects also support the healthful image of honey (Aljadi and Yousef, 2003). Although, the antibacterial effect of honey is well-known, the mechanism is still controversial. The high osmolarity due to high sugar content and low pH due to presence of glycolic acid are probably the most important factors for antibacterial effect (Aljadi and Yousef, 2003). Besides hydrogen peroxide ingredient in honey is thought to have an important antibacterial effect. Additionally, the presence of organic components obtained from surface of flowers such as syringic acid, methyl syringate, flavonoids, pinocembrin, phenolic acids, caffeic acid, ferulic acid, vanillic acid, cinnamic acid, benzoic acid, kaempferol and gallic acids form the other non-peroxide activity (Aljadi and Yousef, 2003). Honey has been shown to decrease free oxygen radicals and increase tumour necrosis factor- α to a significant level (Tonks *et al.*, 2001). The application of honey into a newly formed wound increases wound contraction and accelerates wound healing (Osuagwu *et al.*, 2004). Rock salt softens the fibrosed hypertrophied tissue and also increases the penetration of sesame oil. The combination of sesame oil, honey and rock salt is being used since thousands of years in ancient medical science of India without any adverse effects (Amilkanthawar and Rajendra, 2004).

For this reason, researchers thought a effective treatment for urethral stricture by using this mixture. According to the results, this mixture has negative effect on urethral stricture treatment. The application of honey into a newly formed wound increases wound contraction and accelerates wound healing (Osuagwu *et al.*, 2004). Honey, used as healer in skin scars (Gurdal *et al.*, 2003) can be thought not beneficial for urethral stricture because it narrow the lumen by wound contraction.

CONCLUSION

There was not found any histopathological difference between the Group 1 to which not any drug was given and Group 2 to which saline was injected into urethra ($p>0.05$). However, in the Group 3 which had uttarbasti into urethra, urethral stricture was observed to be more severe ($p<0.05$). It can be thought that uttarbasti which is useful in wound healing treatment can make the problem more severe in urethral stricture treatment.

REFERENCES

- Aljadi, A. and K. Yousef, 2003. Isolation and identification of phenolic acids in Malaysian honey with antibacterial properties. *Turk. J. Med. Sci.*, 33: 229-236.

- Amilkanthawar and H. Rajendra, 2004. Role of uttarbasti in management of mutra marga sankoch (urethral stricture). *Indian J. Traditional Knowl.*, 3: 177-181.
- Andrich, D.E. and A.R. Mundy, 2000. Urethral strictures and their surgical treatment. *BJU Int.*, 86: 571-580.
- Ayyildiz, A., B. Nuhoglu, B. Gulerkaya, M. Caydere, H. Ustun, C. Germiyanoglu and D. Erol, 2004. Effect of intraurethral mitomycin-c on healing and fibrosis in rats with experimentally induced urethral stricture. *Int. J. Urol.*, 11: 1122-1126.
- Ayyildiz, A., K.T. Akgul, O. Cebeci, B. Nuhoglu, M. Caydere, H. Ustun and C. Germiyanoglu, 2007. Intraurethral honey application for urethral injury: An experimental study. *Int. Urol. Nephrol.*, 39: 815-821.
- Cho, K.Y., S.J. Lee, J.S. Burm and E.A. Park, 2007. Successful combined treatment with total parenteral nutrition fluid extravasation injuries in preterm infants. *J. Korean Med. Sci.*, 22: 588-594.
- Da-Silva, E.A., F.J. Sampaio, M.C. Dornas, R. Damiao and L.E. Cardoso, 2002. Extracellular matrix changes in urethral stricture disease. *J. Urol.*, 168: 805-807.
- Gurdal, M., E. Yucebas, A. Tekin, M. Beysel, R. Aslan and F. Sengor, 2003. Predisposing factors and treatment outcome in fournier's gangrene. Analysis of 28 cases. *Urol. Int.*, 70: 286-290.
- Hafez, A.T., A. El-Assmy, M.S. Dawaba, O. Sarhan and M. Bazeed, 2005. Long-term outcome of visual internal urethrotomy for the management of pediatric urethral strictures. *J. Urol.*, 173: 595-597.
- Kumar, S., P. Wong and D. Leapar, 2004. What is new in wound healing? *Turk. J. Med. Sci.*, 34: 147-160.
- Osuagwu, F.C., O.W. Oladejo, I.O. Imosemi, A. Aiku and O.E. Ekpos *et al.*, 2004. Enhanced wound contraction in fresh wounds dressed with honey in wistar rats (*rattus norvegicus*). *West. Afr. J. Med.*, 23: 114-118.
- Tonks, A., R.A. Cooper, A.J. Price, P.C. Molan and K.P. Jones, 2001. Stimulation of tnf-alpha release in monocytes by honey. *Cytokine*, 14: 240-242.