

Effects of Fermentation Astragalus Polysaccharides on Experimental Hepatic Fibrosis

^{1,2}Zhe Qin, ²Jianxi Li, ²Zhiqiang Yang, ²Kai Zhang, ²Jinyan Zhang,
²Jiaren Meng, ²Long Wang and ²Lei Wang

¹College of Veterinary Medicine, Gansu Agricultural University,
Lanzhou, 730070 Gansu, China

²Chinese Academy of Agricultural Sciences,
Lanzhou Institute of Animal and Veterinary Pharmaceutics Sciences,
Lanzhou, 730070 Gansu, China

Abstract: This study aims to explore the antagonistic function of Fermentation Astragalus Polysaccharides (FAPS) on experimental hepatic fibrosis induced by CCl₄ and its possible mechanism. Hepatic fibrosis was induced by subcutaneous injection with carbon tetrachloride twice weekly for 8 weeks in Sprague-Dawley rats. Different doses of Fermentation Astragalus Polysaccharides (FAPS) (50, 100 and 150 mg/(kg/day)) and colchicines (50 mg/(kg/day)) were administered intragastrically daily to carbon tetrachloride-treated rats. After the experiment, rats from all the groups were weighed and the following parameters were measured: Alanine Aminotransferase (ALT), Aspartate aminotransferase (AST), Alkaline Phosphatase (ALP), Hyaluronic Acid (HA), Laminin (LN), IV type of Collagen (CIV) and ammonia terminal Procollagen β peptide (PCIII) in their sera and of Total Antioxidant Capacity (T-AOC), Glutathione Peroxidase (GSH-Px), Malondialdehyde (MDA) and Hydroxyproline (Hyp) in homogenate in the animal livers. Additionally, partial liver tissues were examined histopathologically as well as by Hematoxylin and Eosin (H and E) and Masson chromoscopy. Results showed that compared with the control group, rats from the model group had a significant decrease in body weight, a significant rise in ALT, AST and ALP levels in the serum and also a remarkable lift of HA, LN, CIV and PCIII the four indicators of hepatic fibrosis. Moreover, T-AOC, GST and GSH-Px enzyme activities were reduced significantly in model rats while concentrations of MDA, Hyp and reduced GSH were raised substantially ($p < 0.01$). Histopathological examination, Hematoxylin and Eosin (H and E) and masson chromoscopy revealed an evident change in hepatic fibrosis in the livers of the model group. Compared with the model group, animals treated with FAPS all had a greater weight, a lower activity of ALT, AST and ALP in the sera, lower levels of HA, LN, CIV and ammonia terminal PCIII as well as less Hyp. In addition, FAPS significantly increased the reduced MDA, GSH-Px and GST values, elevated Total Antioxidant Capacity (T-AOC) and brought the abnormally high reduced GSH back to a normal level. Such effects on hepatic fibrosis in animals from the FAPS_H group all turned out stronger than those of Col group animals ($p < 0.05$). Thus, the data indicates that FAPS can produce an apparent antagonism to hepatic fibrosis and the mechanism by which it does this may be associated with generation of oxygen free radicals.

Key words: Fermentation Astragalus Polysaccharides (FAPS), hepatic fibrosis, rat, generation, radicals, mechanism

INTRODUCTION

Hepatic fibrosis is a type of pathological repair response occurring in conjunction with liver injury and characterized by an abnormal proliferation of collagenous fiber within the liver tissue, the denaturation and necrosis of hepatocytes and damage to hepatic structure. Hepatic

fibrosis results in an aberration of liver function and hampers prognosis of liver disease. It is an imperative stage by which chronic liver diseases develop into cirrhosis (Shu *et al.*, 2007; Aboutwerat *et al.*, 2003; Shimizu, 2003). Hepatic fibroses may be caused by parasitic infection (tapeworm (Ding *et al.*, 2008), nematode (Xu *et al.*, 2011) or toxin (aflatoxin (Wang and Groopman,

Corresponding Author: Zhiqiang Yang, Chinese Academy of Agricultural Sciences,
Institute of Lanzhou Animal Science and Veterinary Pharmaceutics, 335# Jiangouyan Street,
Qilihe District, 730050 Lanzhou City, Gansu Province, P.R. China

1999) and these sources have imposed a considerable cost on animal husbandry in China. Prevention of hepatic fibrosis has been drawing interest from researchers in China and abroad but there is still for a lack of treatments for clinical applications.

However, traditional Chinese medicine can not only act against hepatic fibrosis but also speed up an animal's recovery from chronic liver diseases by encouraging the regeneration of hepatocytes (Ao *et al.*, 2004). Astragal is extracted from the dry roots of the leguminous plants *Astragalus membraanceus* (Fisch.) Bge. var. *mongholicus* (Bge.) Hsiao and *Astragalus membranaceus* (Fisch.) Bge. It is a major medicine present in many traditional Chinese medicine prescriptions (such as Yiganing Keli, Liganlong Keli and Yinqiganfu Keli (CPC, 2010) for liver diseases. The effective components include triterpenoid saponins, flavonoids compounds and astragalus polysaccharides (CPC, 2010; Zou *et al.*, 2002) and many researchers have showed that astragalus polysaccharides were effective against hepatic fibrosis (Zou *et al.*, 2002; Zhang *et al.*, 2003; Li *et al.*, 2007). However, its application has been severely restricted by poor extraction efficiency, through water extraction and alcohol precipitation and the resulting waste of materials. With studies of Chinese medicine preparation on-going, progress has been made in medicine preparation by means of fermentation in place of traditional methods (Wang *et al.*, 2008). Through degradation by microorganism, effective components and active substances in the drug can be extracted. As a consequence, medicine cost can be reduced due to stronger drug potency and lower necessary dosage (Wang *et al.*, 2008). Researchers biologically fermented astragals using *Streptococcus alactolyticus* and elevated the yield of *Astragalus polysaccharides* from 1.8-3.8% and its overall content from 33.53-70.88%. Since, little research has been carried out on the mechanism by which FAPS antagonizes hepatic fibrosis, here we sought to explore the issue via constructing an experimental model of liver injury by use of CCl₄ and examining the effects of FAPS on the weight of the animals, their biochemical indicators of serum and liver and histopathological changes to the organ. This study provides useful experimental data for the development of FAPS as a medicine capable of treating liver injuries in the future.

MATERIALS AND METHODS

Astragals were identified from *Astragalus membranaceus* (Fisch.) Bge received from the Veterinary Medicine and Feed Monitor in Gansu province. Colchicine was purchased from Wako Pure Chemical Industries, Ltd. Japan. The radio immune assay test kit of Hyaluronic Acid (HA), Laminin (LN), IV type of Collagen

(CIV) and ammonia terminal Procollagen β peptide (PCIII) was purchased from Beijing North Institute of Biological Technology. The test kit of Alanine Aminotransferase (ALT), Aspartate aminotransferase (AST) and Alkaline Phosphatase (ALP) was bought from Shenzhen Mindray Bio-Medical Electronics Co., Ltd. The test kit of Malondialdehyde (MDA), Glutathione Peroxidase (GSH-Px), Glutathione S-Transferase (GST), Glutathione (GSH), Total Antioxidant Capacity (T-AOC) and Hydroxyproline (Hyp) was from Nanjing Jiancheng Bioengineering Institute. The test kit for protein concentration using the Lowry method was from Beijing Solarbio Science and Technology Co., Ltd. CCl₄ was provided by Tianjin Zhiyuan Chemical Agent Co., Ltd. and was diluted 1:1 with peanut oil. The FGM9 strain of *Streptococcus alactolyticus* was prepared by the Animal Husbandry and Veterinary Medicine Research Institute, Chinese Academy of Agricultural Sciences in Lanzhou, Gansu province. Gifu Anaerobic Medium (GAM) culture medium was made by Qingdao Hope Bio-Technology Co., Ltd. Absolute ethyl alcohol and glacial acetic acid were Analytical Reagent (AR) and were purchased from Tianjin Tianxin Fine Chemicals Development Center.

Apparatuses: The microbial fermentation tank was made by Shanghai Gaoji Bio-Engineering Co., Ltd. The Allegra X-15R centrifuge was made by Beckman in the USA. The BS-420 automatic clinical chemistry analyzer was made by Shenzhen Mindray Bio-Medical Electronics Co., Ltd. The DPC- γ C-12 immunoradiometric counter was produced by Tianjin Depu Bio-medical Electronics Co., Ltd. The SpectraMax M2[®] microplate reader was made by Molecular Devices, USA. The Leica automatic biopsy system was manufactured by Leica, Germany and the Olympus X71 microscopic imaging system was made by Olympus, USA. ZHWY-2102C Incubator shaker was made by Shanghai Zhicheng Analysis Instrument Co., Ltd.

Extraction of FAPS: *Streptococcus alactolyticus* in the proportion of 2% was inoculated into GAM media (pH = 7) that contained 8% astragals solution. After a 72 h anaerobic fermentation in a 37°C thermotank, the fermented solution was then freeze dried. The dried powder (4 kg) of fermented astragals was extracted respectively with 40 and 20 L 80% ethanol and then underwent a 2 h reflux extraction at 78°C. After filtration, the residue was extracted, respectively with 40, 20 and 20 L water and boiled for 1.5 h at 80°C followed by another filtration. Thereafter, the three filtrates were combined and condensed to 1:1 (the ratio was weight of fermented astragals freeze-dried powder to the volume of filtrate). Deproteinization was done using the Sevag method

(Staub, 1965). Briefly, a 4:1 mixture of chloroform and normal butanol was added to the filtrate, the mixture was 80 r min⁻¹ of shaking for 30 min and the mixture was centrifuged for 5 min at 3000 r min⁻¹ and the liquid supernatant was removed and reserved. This procedure was repeated three times. Following deproteinization, the combined supernatants were subjected to a 24 h flow-water dialysis and a 24 h distilled water dialysis. Then add ethyl alcohol to 4× the volume of the resulting dialyzed filtrate, the mixture was stirred and deposited for 12 h and then centrifuged by 3000 r min⁻¹ for 5 min. The precipitate was washed with absolute ethyl alcohol, acetone and diethyl ether with the same volume with concentrated filtrates and freeze dried. The yield of FPS was 160 g totally.

Grouping of experimental animals: The Experimental Animal Center located in the Department of Medicine, Lanzhou University provided us with intact male Sprague-Dawley (SD) rats, certification No. SCXK (Gan) 2005-0007. A 7 days observation confirmed that the feeding environment could come up to GB 14922.2-2001 requirements.

Sixty sanitary male rats were randomly divided into six groups, ten in each group. The groups included a normal control group and a model group, a group administered a low dose of FAPS (FAPS_L) (50 mg/(kg/day)), one administered with a mid dose (FAPS_M) (100 mg/(kg/day)), one administered with a high dose (FAPS_H) (150 mg/(kg/day)) and one administered with Colchicine (Col) (0.2 mg/(kg/day)) (Zou *et al.*, 2002). At the same time, the rats were injected hypodermically with 2 mL kg⁻¹ 50% CCl₄ sterilized peanut oil solution, twice a week for 8 weeks. The exception was for the normal control group which was injected solely with a corresponding amount of peanut oil. From the first injection of CCl₄ on, animals from each of the drug groups were also intragastrically administered FAPS and according to group assignments, once a day for 8 weeks. The model group and the normal control group were intragastrically administered normal saline solution of corresponding amounts. Animals were weighed once a week.

Measurement of text indicators: After 8 weeks, the experiment concluded, deprivation of food but not water for 16 h and then measured the body weight. Blood was collected from the femoral artery of each rat and centrifuged (15 min at 2000 rpm min⁻¹). Then sera preserved at -80°C for the determination and measurement of ALT, AST, ALP, HA, LN, C_x, PC_β, GSH-Px and GST. All the animals were sacrificed by cervical dislocation;

part of the liver tissue was fetched rapidly and placed in liquid nitrogen to be used for the detection of MDA, GSH, T-AOC, Hyp and protein. The left lobe of liver was isolated and fixed in 10% neutral formalin solution for the preparation of routine paraffin slides. H and E and masson staining were performed for histological and pathological examinations of treated rats (Zhuoming, 1998).

Statistic data process: SPSS Software (Version 17.0) (SPSS, 2009) was utilized for the statistic analysis. Measurement data were expressed in the form of mean±standard deviation ($\bar{x} \pm s$). Comparisons among groups were conducted by means of ANOVA. Difference is statistically significant when $p < 0.05$.

RESULTS

Effects of FAPS on rats' body weight: By the end of the experiment, the control rats had a body weight significantly greater than the model group ($p < 0.01$) as did the FAPS_L, FAPS_M and FAPS_H groups ($p < 0.05$). The model rats, weighting 306 g on average before treatment had increased weights after being treated with FAPS (50, 100, 150 mg kg⁻¹) or Col (0.2 mg kg⁻¹). All treated rats had lower weights than the control. However, the difference between the FAPS_H group and the control group and the difference between the FAPS_H group and the model group were not significant ($p > 0.05$) (Table 1).

Effects of FAPS on serum ALT, AST and ALP of rats with hepatic fibrosis: In contrast with the control group and the normal group, the model group rats had significantly elevated serum ALT, AST and ALP which were remarkably reduced by FAPS (50, 100 and 150 mg kg⁻¹) or Col (0.2 mg kg⁻¹) treatments, especially by the high-dosage FAPS treatment ($p < 0.05$). This indicates that FAPS could protect rats against chronic liver damage (Table 2).

Effects of FAPS on the contents of PCIII, C_x, LN and HA in rat serum and the content of Hyp in hepatic tissue: Table 3 shows that in comparison with the normal control,

Table 1: Variation of rat body weight before and after the experiment (g)

Groups	Dosage (mg/(kg/day))	n	Before experiment (g)	After experiment (g)
Control	-	10	217±21	385±31 ^a
Model	-	10	215±19	306±19 ^a
FAPS _L	50.0	10	215±24	329±24 ^a
FAPS _M	100.0	10	217±16	336±20 ^a
FAPS _H	150.0	10	216±16	342±36
Col	0.2	10	214±12	331±16 ^a

^a $p < 0.05$ vs the control group, ^{*} $p < 0.01$ vs the control group, [#] $p < 0.01$ vs. the model group. FAPS_L was low dose of FAPS by 50 mg/(kg/day), FAPS_M was mid dose of FAPS by 100 mg/(kg/day), FAPS_H was high dose of FAPS by 150 mg/(kg/day), Col was colchicine by 0.2 mg/(kg/day)

Table 2: Effects of FAPS on serum Alanine Aminotransferase (ALT), Aspartate aminotransferase (AST) and Alkaline Phosphatase (ALP) of rats induced with hepatic fibrosis by CCl₄ ($\bar{X} \pm S, n = 10$)

Groups	Dosage (mg/(kg/day))	n	ALT (nmol S ⁻¹ L ⁻¹)	ALP (μ mol S ⁻¹ L ⁻¹)	AST (nmol S ⁻¹ L ⁻¹)
Control	-	10	60.75 \pm 9.3800 [#]	103.67 \pm 22.79 [#]	205.50 \pm 29.180 [#]
Model	-	10	613.88 \pm 145.88 ^Δ	269.30 \pm 82.92 [*]	698.40 \pm 119.54 ^Δ
FAPS _L	50.0	10	532.83 \pm 120.02 ^Δ	257.17 \pm 57.97 [*]	636.67 \pm 182.80 ^Δ
FAPS _M	100.0	10	470.71 \pm 126.79 ^Δ	225.83 \pm 38.70 [*]	597.50 \pm 127.68 [#]
FAPS _H	150.0	10	371.80 \pm 73.71 ^{Δ#}	180.40 \pm 62.12 [#]	494.40 \pm 114.34 [#]
Col	0.2	10	502.75 \pm 167.95 ^Δ	341.17 \pm 88.18 [*]	478.83 \pm 113.91 [#]

Table 3: Effects of FAPS on the concentrations of ammonia terminal Procollagen β peptide (PC β), IV type of Collagen (CIV), Laminin (LN), Hyaluronic Acid (HA) in serum and the concentration of Hyp in hepatic homogenate in rats induced with hepatic fibrosis ($\bar{X} \pm S, n = 10$)

Groups	Dosage (mg/(kg/day))	n	PC β (ng L ⁻¹)	C χ (ng mL ⁻¹)	LN (ng mL ⁻¹)	HA (ng mL ⁻¹)	Hyp (μ g mg ⁻¹ prot)
Control	-	10	16.65 \pm 3.20 [#]	12.56 \pm 0.96 [#]	28.03 \pm 3.87 [#]	192.80 \pm 28.33 [#]	0.07 \pm 0.01 [#]
Model	-	10	33.04 \pm 6.41 [*]	26.49 \pm 4.39 [*]	54.11 \pm 13.33 [*]	389.70 \pm 61.40 [*]	0.41 \pm 0.02 ^Δ
FAPS _L	50.0	10	30.79 \pm 3.88 [*]	23.83 \pm 2.35 [*]	50.09 \pm 4.39 [*]	350.82 \pm 78.27 [*]	0.31 \pm 0.01 ^Δ
FAPS _M	100.0	10	28.30 \pm 3.38 [*]	20.47 \pm 2.25 [*]	46.47 \pm 2.25 [*]	335.23 \pm 54.00 [*]	0.22 \pm 0.01 [*]
FAPS _H	150.0	10	26.06 \pm 3.28 [*]	19.10 \pm 3.86	42.10 \pm 3.86 [*]	308.81 \pm 44.60 [*]	0.12 \pm 0.02 ^Δ
Col	0.2	10	27.96 \pm 5.52 [*]	23.94 \pm 3.33 [*]	45.83 \pm 2.35 [*]	252.33 \pm 33.46 [#]	0.17 \pm 0.01 ^Δ

Table 4: Effects of Total Antioxidant Capacity (T-AOC), Glutathione (GSH), Malondialdehyde (MDA) and protein contents in hepatic tissues of rats induced with hepatic fibrosis ($\bar{X} \pm S, n = 10$)

Groups	Dosage (mg/(kg/day))	n	T-AOC (U mg ⁻¹ prot)	GSH (μ mol g ⁻¹ prot)	MDA (nmol mg ⁻¹ prot)	Protein (μ g μ L ⁻¹)
Control	-	10	0.23 \pm 0.02 [#]	1.55 \pm 0.29 [#]	0.39 \pm 0.05	11.84 \pm 0.96 [#]
Model	-	10	0.03 \pm 0.01 [*]	3.50 \pm 1.04 [*]	0.90 \pm 0.21 [*]	9.92 \pm 1.10 ^Δ
FAPS _L	50.0	10	0.05 \pm 0.01 [*]	3.35 \pm 0.55 [*]	0.86 \pm 0.25 [*]	10.21 \pm 1.00 ^Δ
FAPS _M	100.0	10	0.14 \pm 0.03 [#]	3.25 \pm 0.37 [*]	0.83 \pm 0.32 [*]	11.01 \pm 1.24
FAPS _H	150.0	10	0.15 \pm 0.002 [#]	3.04 \pm 0.57 [*]	0.80 \pm 0.37 [*]	11.47 \pm 1.47 [#]
Col	0.2	10	0.07 \pm 0.01 [*]	3.05 \pm 0.40 [*]	0.88 \pm 0.23 [*]	10.09 \pm 1.13 ^Δ

Table 5: Effects of Fermentation Astragalus Polysaccharides (FAPS) on activities of Glutathione Peroxidase (GSH-Px) and Glutathione S-Transferase (GST) in serum in rats induced with hepatic fibrosis ($\bar{X} \pm S, n = 10$)

Groups	Dosage (mg/(kg/day))	n	GST (U mL ⁻¹ serum)	GSH-Px (U)	MDA (nmol mL ⁻¹)
Control	-	10	67.65 \pm 16.31 [#]	2899.18 \pm 280.87 [#]	1.21 \pm 0.15 [#]
Model	-	10	49.55 \pm 8.080 ^Δ	2212.09 \pm 298.37 ^Δ	3.85 \pm 0.60 [*]
FAPS _L	50.0	10	51.99 \pm 10.39 [*]	2380.84 \pm 361.26 [*]	3.80 \pm 0.41 [*]
FAPS _M	100.0	10	56.87 \pm 15.10 [*]	2530.99 \pm 209.66 [*]	3.45 \pm 0.37 [*]
FAPS _H	150.0	10	64.28 \pm 19.45	2648.07 \pm 199.66 [#]	3.12 \pm 0.55 [*]
Col	0.2	10	60.3 \pm 19.910	2487.16 \pm 339.60 [*]	3.29 \pm 0.74 [*]

p<0.05 vs. the control, ^Δp<0.01 vs. the control, [#]p<0.01 vs. the model, ^{}p<0.05 vs. FAPS_H. FAPS_L was low dose of FAPS by 50 mg/(kg/day), FAPS_M was mid dose of FAPS by 100 mg/(kg/day), FAPS_H was high dose of FAPS by 150 mg/(kg/day), Col was colchicine by 0.2 mg/(kg/day)

PC β , C χ , LN, HA and Hyp in model rats were all significantly higher (p<0.01). After FAPS (50, 100 and 150 mg kg⁻¹) or Col (0.2 mg kg⁻¹) treatments, model rats had significantly reduced levels of PC β , C χ , LN in the serum and of HA in hepatic tissue. Differences in CIV activity between the FAPS_H group and the control group were not significant (p>0.05). FAPS (50, 100 and 150 mg kg⁻¹) and Col (0.2 mg kg⁻¹) treatments could produce a significant reduction in Hyp in the liver homogenate in model rats, particularly in contrast with the model group before treatment (p<0.05).

The results of the five indicators of liver fibrosis stated above suggest that both FAPS and APS could inhibit hepatic fibrosis to a certain extent and the inhibition strengthened along with dosage augmentation along the concentration gradient.

Effects of FAPS on T-AOC, GSH, MDA and protein content in hepatic tissues of rats: Results in Table 4 shows that compared with the normal control, model rats had significantly decreased concentrations of T-AOC and protein (p<0.01) but significantly increased concentrations of MDA (p<0.05) and GSH (p<0.01). FAPS (150 mg kg⁻¹) treatment applied on model rats substantially reduced MDA content but increased T-AOC and protein contents (p<0.01). FAPS (50, 100 and 150 mg kg⁻¹) and Col (0.2 mg kg⁻¹) treatments could both increase GSH but not significantly (p>0.05).

Effect of FAPS on the activities of GSH-Px and GST in serum: As shown in Table 5, model rats had a decline of GSH-Px and GST activities (p<0.01) but an increase of MDA content (p<0.01), both as compared with the normal

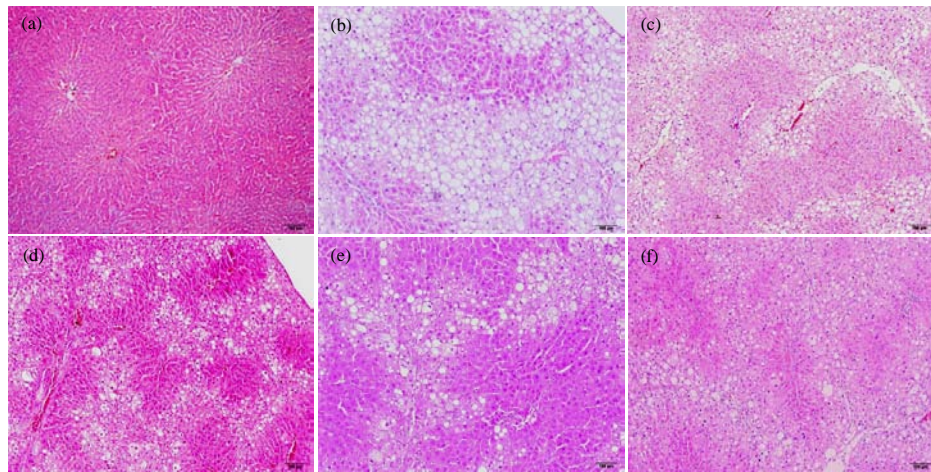


Fig. 1: HE staining of liver biopsy (HE \times 100); a) control; b) model; c) FAPS_L (50 mg kg⁻¹); d) FAPS_M (100 mg kg⁻¹); e) FAPS_H (150 mg kg⁻¹); f) Col (0.2 mg kg⁻¹). FAPS_L was low dose of FAPS by 50 mg/(kg/day), FAPS_M was mid dose of FAPS by 100 mg/(kg/day), FAPS_H was high dose of FAPS by 150 mg/(kg/day), Col was colchicine by 0.2 mg/(kg/day)

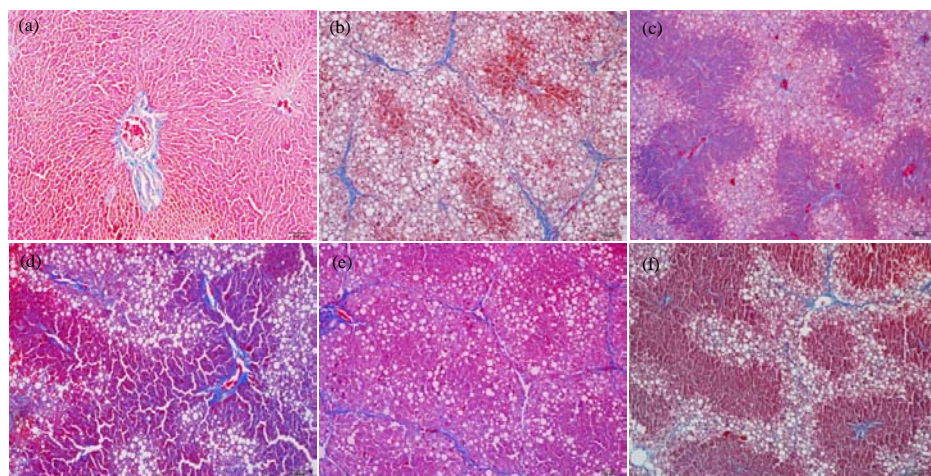


Fig. 2: Masson staining of liver biopsy (Masson \times 100); a) control; b) model; c) FAPS_L was low dose of FAPS by 50 mg/(kg/day); d) FAPS_M was mid dose of FAPS by 100 mg/(kg/day); e) FAPS_H was high dose of FAPS by 150 mg/(kg/day); f) Col was colchicine by 0.2 mg/(kg/day)

control. FAPS_H (150 mg kg⁻¹) treatment reduced MDA in model rats (not significantly) but did significantly increase GSH-Px and GST activities ($p < 0.05$).

Effects of FAPS on liver histology and pathology in rats induced with hepatic fibrosis: According to the H and E staining results shown in Fig. 1 for the normal group, hepatic cells were evenly radiating outward from the central vein without collagen fiber hyperplasia and the hepatic lobule was structurally complete. For the model group, hepatic cell cords became disordered, fibrous

connective tissue accreted and the number of inflammatory cells and dead cells increased in the portal area. In addition, the accreted collagen fibers formed streak fibrous septa, thickened fiber partitions appeared in hepatic portal bundle area and pseudolobules could be found. FAPS (50, 100, 150 mg kg⁻¹) and APS (250 mg kg⁻¹) treatments applied to model rats improved hepatic fibrosis in different degrees with inflammatory cells found only within fibrous septa. Masson staining results (Fig. 2) showed that in the case of normal rats, the hepatic lobule was structurally complete, hepatic cells

were in even arrangement and no significant collagen fiber hyperplasia was in place, except for the little observed around blood vessels in the portal area. In the case of model rats however, collagen fibers increased remarkably, extending from the portal area and inflammatory or dead area, forming fibrous septa of different thickness over the portal area and blood vessels by either cutting through or surrounding hepatic lobules.

Also, pseudolobules were clearly observed. FAPS (50, 100 and 150 mg kg⁻¹) and APS (250 mg kg⁻¹) treatments lessened hepatic fibrosis to different extents and made things better with fat vacuoles seen only within fibrous septa and some blue fibers running around blood vessels.

DISCUSSION

Hepatic fibrosis is a pathophysiological process with high incidence and high mortality. It can be induced by hepatitis viruses, alcohol addiction, schistosomiasis infection, autoimmune diseases, drugs and other factors (Shu *et al.*, 2007; Aboutwerat *et al.*, 2003; Shimizu, 2003). Hepatic fibrosis results from an imbalance between the synthesis and the degradation of the Extracellular Matrix (ECM) which resulting in an excessive deposition of it in the intercellular substance (Loguercio and Federico, 2003; Hung *et al.*, 2005). MDA (Malondialdehyde) can prompt an organism to produce a large amount of interstitial collagen as well as other ECM components which first deposit in hepatic clearances and ultimately give rise to overall hepatic fibrosis (Martin-Aragon *et al.*, 2001). CCl₄ is a potent hepatotropic poison that causes damage by peroxidation (Boll *et al.*, 2001). The specific mechanism goes this way: on one hand after the metabolism facilitated by the monooxygenase system on which the liver microsomal cytochrome P450 is dependent, the C-Cl bonds in CCl₄ undergo hemolytic cleavage and consequently result in chloroform free radicals (•CCl₃) and chlorine free radicals (•Cl). These free radicals attack phospholipid molecules on liver cell membranes and result in lipid peroxidation. On the other hand, •CCl₃ can bind immediately with molecular oxygen and form •CCl₃O₂ which is more capable of causing lipid peroxidation and even cell mortality (Spiteller, 2003). These free radicals also attack unsaturated lipid content on cell membrane through covalent binding with macromolecules within hepatic cells and in this way, induce lipid peroxidation and damages to hepatic cells which consequently develop into liver injury and damage the structure and function of cell membranes (Maezono *et al.*, 1996; Yoshikawa *et al.*,

2002). In addition, products of the lipid peroxidation caused by •CCl₃ can induce an inflammatory response (Albano, 2002) activate Kupffer cells and Hepatic Stellate Cells (HSC) and as a result, prompt hepatic fibrosis (Xu *et al.*, 2003a). Furthermore, CCl₄ can inhibit the pump activity of Ca₂⁺ on the cell membrane. As a result, a large amount of Ca²⁺ flows inward and deposits in cells (Ye, 1997) so much so that structure and function of mitochondria are damaged which in turn causes the activation of phospholipase and thus the degradation of membrane phospholipids, the damage of lysosome membrane and then the release of proteolytic enzymes. Consequently, xanthine dehydrogenase is turned into xanthine oxidase giving rise to a large number of oxygen radicals and thus aggravating liver injury. When hepatic cells are injured, ALT, AST and ALP-components of the cytoplasm liquid are released so that the activities of ALT, AST and ALP in serum are elevated, indicating degrees of the injury (Kew, 2000). An abnormal rise of ALT signifies cell apoptosis and higher levels of ALP indicate cholestasis (Pablo *et al.*, 2005). In this study, activities of ALT, AST and ALP in model rats induced with hepatic fibrosis by CCl₄, all increased significantly (p<0.01). But both FAPS (50, 100 and 150 mg kg⁻¹) and APS (250 mg kg⁻¹) treatments to these rats reduced ALT, ASP and ALP levels, especially the FAPS_H treatment (p<0.01). This all suggests that through its protection of hepatic cell membranes, FAPS can assist in recovery or prevent liver from injury imposed by hepatic fibrosis.

It has been demonstrated by a large amount of clinical data which HA, LN, PCIII and CIV levels are in positive correlation with the inflammatory activity and fibrosis of hepatic tissue (Shi *et al.*, 2008; Liang and Zheng, 2002). As a peptide located at the amino terminal and removed by relevant enzymes before the formation of tropocollagen by procollagen type III, PCIII is a serum indicator of hepatic fibrosis. Its rise signifies the occurrence of the fibrosis. Also, it has been reported that the mRNA of procollagen type III decreases throughout the process of hepatic fibrosis induced by CCl₄ in rats (Ding *et al.*, 2005; Liu *et al.*, 2006). HA is macromolecule glucosamine polysaccharose synthesized by interstitial cells. It is distributed in various connective tissues. Liver endothelial cells is the primary location where HA in serum is removed. In the case of chronic liver diseases, because of the injury the organ is subject to the liver, its endothelial cells' ability to take in and decompose HA is damaged and thus the level of HA will increase. Therefore, HA is an index that can report on liver endothelial cells' function and hepatic fibrosis. The application value held by HA in the diagnosis of hepatic

fibrosis has been confirmed by multiple experimental studies (Xu *et al.*, 2003b). LN plays a role in hepatic fibrosis by connecting macromolecular components in the matrix, participating in the formation of basilemma and the capillarization of hepatic sinusoid. Normally, the level of LN in human serum is relatively low but during hepatic fibrosis it will rise considerably (Zheng *et al.*, 2006). CIV is a major component of the basilar membrane. It can effectively reflect the variation of the basilar membrane. Because it emerges at the first sign of hepatic fibrosis, it can be suitably used for the early diagnosis of the disease. Moreover, as the disease progresses, CIV levels will gradually increase (Attallah *et al.*, 2007). Hyp is a pathognomonic amino acid in collagen. It is indicative of the content of collagen protein and the degree of hepatic fibrosis (Shi *et al.*, 2008). The Hydroxyproline (Hyp) in the hepatic tissues has content as great as 13.4% in collagen protein while elastin contains little of it. Moreover, it does not exist in other proteins at all. At the time of hepatic fibrosis, collagen fiber will increase and as such so will Hyp. Thus, the content of Hyp measured in liver tissue can be converted into the content of collagen protein in the liver which then reflects the degree of fibrosis (Laurin *et al.*, 1996; Kim *et al.*, 2003). In this study, FAPS (50, 100 and 150 mg kg⁻¹) and APS (250 mg kg⁻¹) treatments decreased HA, LN, CIV, PCIII levels and Hyp content in the treated rats. The Hyp reductions observed with FAPS or APS treatments were all significant ($p < 0.01$). On the other hand, decreases of CIV, LN and HA in the treated groups were not significant when compared with the model group. Yet as dosages increased, the variation between the treated group and the model group became more and more evident. The results together imply that FAPS and APS treatments can produce a certain antagonism to CCl₄ induced hepatic fibrosis.

T-AOC refers to the general status of an organism's antioxidant defense system which includes an enzymatic system and a non-enzymatic system. The former system includes SOD, GSH-Px, CAT, GST and so on while the latter system consists of vitamins, amino acids and metalloproteins such as vitamin E, vitamin C, carotene, cysteine, tryptophan, glucose, transferrin and lactoferrin protein (Kaplowitz, 2002). Antioxidant defense is performed primarily in three approaches: the first is to remove free radicals and active oxygen so as to avoid lipid peroxidation; the second is to decompose hydrogen peroxide materials by cutting off the peroxidation chain and the third is to get rid of catalytic metal ions. The experimental results show that T-AOC in model rats decreased significantly in contrast to the normal group ($p < 0.01$), indicating a weakening of antioxidant defense. Nevertheless, FAPS_H and FAPS_M treatments increased T-AOC levels ($p < 0.01$).

Histopathological examinations (HE staining, Masson staining) performed for the experiment confirmed the protective effects FAPS and APS on rats with CCl₄ induced hepatic fibrosis. The process of hepatic fibrosis involves changes of ECM components and their contents and activation of matrix protein cells. Lipid peroxidation and its metabolic products are necessary for the inducement of expression of collagen genes in fat-storing cells which after being activated, synthesize mainly Collagen I and III. These are interstitial collagens whose contents can determine the degree of cirrhosis. Oxidative Stress (OS) is present in many kinds of pathogenic processes of liver damage. As long as pathogenic causes have not been removed, they can continuously act on the liver and affect hepatic fibrosis and even liver cirrhosis (Ogeturk *et al.*, 2008; Torok, 2008; Disario *et al.*, 2007). Under normal physiological conditions, Reactive Oxygen Species (ROS) is too low to cause any pathological changes (Gebhardt, 2002; Parola and Robino, 2001). However, under pathologic conditions, ROS is produced faster than it can be removed. Thus, this leads to the deposition of active oxygen and then oxidative stress. In addition, ROS can act as an important intracellular messenger to activate signal transduction pathways and thus indirectly result in damages to cells and tissues (Poli, 2000). It was previously proposed that ROS mediated hepatic fibrosis progressed in the following manner: more ROS is produced than removed, peroxidation damages are caused to inflammatory cells such as hepatic cells, Kupffer cells and neutrophils and finally ROS as well as other secretory products, further activate Hepatic Stellate Cell (HSC). Recently however, it has been argued that in addition to the mechanism, ROS, superoxide anion, MDA, aldehyde and arachidonic acid, an oxidized low density lipoprotein can all stimulate and proliferate HSC. Active oxygen molecules which in the serum of model animals induced with hepatic fibrosis will increase and so will hydroxy-deoxy guanosine, MDA and relevant products. They are mainly distributed over piecemeal necrosis and around the portal vein and consequently cause significant changes in serum oxidative stress indicators, i.e., MDA, SOD and GSH-Px (Refik *et al.*, 2004). In this study, researchers examined the concentration of MDA and GDH-Px in model rats and found these rats had a concentration of MDA much higher than the control rats ($p < 0.05$) suggesting oxidative stress occurred in the model rats. On the other hand, we found the GSH-Px concentration in the antioxidant defense system decreased significantly ($p < 0.01$) in the model rats. This indicated a weakening of

the antioxidant defense system. FAPSH treatment reduced the MDA and increased the GSH-Px activity. Thus, it is clear that lipid peroxidation and its metabolic products play an important role in mediating hepatic fibrosis. Included in current treatment protocols for hepatic fibrosis is antioxidant treatment, so antioxidants have a likely role in the mechanism by which FAPSH antagonizes hepatic fibrosis.

CONCLUSION

By histopathological examination, researchers also found that preventative treatment of model rats with FAPS could effectively inhibit and lessen hepatic fibrosis and these positive effects increased along with the applied dosages. All the results shown here suggest FAPS can protect hepatic cells, inhibit HSC activation and prevent CCl₄ induced hepatic fibrosis in rats.

ACKNOWLEDGEMENTS

This research was supported by the Study on Mechanism of Astragalus Polysaccharides Transformation Induced by *Lactobacillus* FGM9 *in vitro* (No.31072162), by the Introduction and Application of Mastitis Diagnosis and Control in Dairy Cow (2010-C7), by the Project of National Dairy Industry and Technology System (CARS-37).

REFERENCES

- Aboutwerat, A., P.W. Pemberton, A. Smith, P.C. Burrows and R.F.T. McMahon, S.K. Jain and T.W. Warnes, 2003. Oxidant stress is a significant feature of primary biliary cirrhosis. *Biochim. Biophys. Acta Mol. Basis Dis.*, 1637: 142-150.
- Albano, E., 2002. Free radical mechanisms in immune reactions associated with alcoholic liver disease. *Free Radic. Biol. Med.*, 32: 110-114.
- Ao, Q., K.M. Mak, C. Ren and C.S. Lieber, 2004. Leptin stimulate tissue inhibitor of metalloproteinase-1 in human hepatic stellate cells: Respective roles of the JAK/STAT and JAK-mediated H₂O₂-dependant MAPK pathways. *J. Biol. Chem.*, 279: 4292-4304.
- Attallah, A.M., T.E. Mosa, M.M. Omran, M.M. Abo-Zeid, I. El-Dosoky and Y.M. Shaker, 2007. Immunodetection of collagen types I, II, III and IV for differentiation of liver fibrosis stages in patients with chronic HCV. *J. Immunoassay Immunochem.*, 28: 155-168.
- Boll, M., L.W. Weber, E. Becker and A. Stampfl, 2001. Mechanism of carbon tetrachloride-induced hepatotoxicity: Hepatocellular damage by reactive carbon tetrachloride metabolites. *Z Naturforsch C*, 56: 649-659.
- CPC, 2010. Chinese Pharmacopoeia. Vol. 1, Medical Science and Technology Press, Beijing, China, pp: 283, 403, 761, 870.
- Ding, X.D., H.Q. Wang, Q. Wu, X.L. Wang and Y. Huang, 2008. Effect of astragalosides on liver fibrosis in mice with schistosomiasis japonica. *Shijie Huaren Xiaohua Zazhi*, 16: 125-131.
- Ding, X.J., S.B. Li, S.Z. Li, H.S. Liu and B. Liu, 2005. A quantitative study of the relationship between levels of liver fibrosis markers in sera and fibrosis stages of liver tissues of patients with chronic hepatic diseases. *Chinese J. Herpetol.*, 13: 911-914.
- Disario, A., C. Candelaresi, A. Omenetti and A. Benedetti, 2007. Vitamin E in chronic liver diseases and liver fibrosis. *Vitamins hormones*, 76: 551-573.
- Gebhardt, R., 2002. Oxidative stress, plant-derived antioxidants and liver fibrosis. *Planta Medica.*, 68: 289-296.
- Hung, K.S., T.H. Lee, W.Y. Chou, C.L. Wu and C.L. Cho, *et al.*, 2005. Interleukin-10 gene therapy reverses thioacetamide-induced liver fibrosis in mice. *Biochem. Biophys. Res. Commun.*, 336: 324-331.
- Kaplowitz, N., 2002. Biochemical and cellular mechanisms of toxic liver injury. *Semin. Liver Dis.*, 22: 137-144.
- Kew, M.C., 2000. Serum aminotransferase concentration as evidence of hepatocellular damage. *Lancet*, 355: 591-592.
- Kim, J.I., T. Tsujino, Y. Fujioka, K. Saito and M. Yokoyama, 2003. Bezafibrate improves hypertension and insulin sensitivity in humans. *Hypertens Res.*, 26: 307-313.
- Laurin, J., K.D. Lindor, J.S. Crippin, A. Gossard and G.J. Gores *et al.*, 1996. Ursodeoxycholic acid or clofibrate in the treatment of non-alcoholic steatohepatitis: A pilot study. *Hepatology*, 23: 1464-1467.
- Li, S.P., X.Y. Xu, Z. Sun and Z. Chen, 2007. Astragalus polysaccharides and astragalosides regulate cytokine secretion in LX-2 cell line. *J. Zhejiang Univ. Med. Sci.*, 36: 543-548.
- Liang, X.H. and H. Zheng, 2002. Value of simultaneous determination of serum hyaluronic acid, collagen type IV and the laminin level in diagnosing liver fibrosis. *Bull. Hunan Med. Univ.*, 27: 67-68.
- Liu, J., J.Y. Wang and Y. Lu, 2006. Serum fibrosis markers in diagnosing liver fibrosis. *Chin. J. Internal Med.*, 45: 475-477.

- Loguercio, C. and A. Federico, 2003. Oxidative stress in viral and alcoholic hepatitis. *Free Radical Biol. Med.*, 34: 1-10.
- Maezono, K., K. Kajiwaru and K. Mawatari, 1996. In protects liver from injury caused by F-galactosamine and CCl4. *Hepatology*, 1: 185-191.
- Martin-Aragon, S., B.D. Heras and M.I.S. Reus, 2001. Pharmacological modification of endogenous antioxidant ursolic acid on carbon tetrachloride-induced liver damage enzymes rats and primary cultures of rat hepatocytes. *Toxicol. Pathol.*, 53: 199-206.
- Ogeturk, M., I. Kus, H. Pekmez, H. Yekeler, S. Sahin and M. Silmaz, 2008. Inhibition of carbon tetrachloride-mediated apoptosis and oxidative stress by melatonin in xperimental liver fibrosis. *Toxicol. Ind. Health*, 24: 201-208.
- Pablo, M., M.G. Mario and C.M. Del, 2005. Resolution of liver fibrosis in chronic CCl4 administration in the rat after discontinuation of treatment: Effect of silymarin, silibinin, colchicine and trimethylcolchicinic acid. *Basic Clin. Pharmacol. Toxicol.*, 96: 375-380.
- Parola, M. and G. Robino, 2001. Oxidative stress-related molecules and liver fibrosis. *J. Hepatol.*, 35: 297-306.
- Poli, G., 2000. Pathogenesis of liver fi brosis: Role of oxidative stress. *Mol. Aspects Med.*, 21: 49-98.
- Refik, M.M., B. Comert, K. Oncu, S.A. Vural and C. Akay *et al.*, 2004. The effect of taurine treatment on oxidative stress in experimental liver fibrosis. *Hepatol. Res.*, 28: 207-215.
- SPSS, 2009. For Windows, Rel. 17.0, 2009. Chicago, SPSS Inc., Chicago, IL.
- Shi, H.B., J.F. Fu and C.L. Wang, 2008. Clinical value of hepatic fibrosis parameters and serum ferritin in obese children with nonalcoholic fatty liver disease. *J. Zhejiang Univ.*, 37: 245-249.
- Shimizu, I., 2003. Impact of estrogens on the progression of liver disease. *Liver Int.*, 23: 63-69.
- Shu, J.C., H. WU, X.J. Pi, Y.J. He and X. LV *et al.*, 2007. Curcumin inhibits lipid peroxidation and the expression of TGF- β 1 and PDGF in the liver of rats with hepatic fibrosis. *Chin. J. Pathophysiol.*, 23: 2405-2409.
- Spiteller, G., 2003. Are lipid peroxidation processes induced by changes in the cell wall structure and how are these processes connected with diseases? *Med. Hypotheses*, 60: 69-83.
- Staub, A.M., 1965. Removal of protein-sevag method: Methods in carbohydrate. *Chemistry*, 5: 5-6.
- Torok, N.J., 2008. Recent advances in the pathogenesis and diagnosis of liver fibrosis. *J. Gastroenterol.*, 43: 315-321.
- Wang, J.S. and J.D. Groopman, 1999. DNA damage by mycotoxins. *Mutat. Res.*, 424: 167-181.
- Wang, X.Z, Z.Q. Yang and J.X. Li, 2008. Study on the interaction between the coarse polysaccharide in fermentation complex of Astragalus and the probiotics isolated from chicken intestine. *J. Gansu Agric. Univ.*, 45: 25-28.
- Xu, H.G., J.P. Fang and S.L. Huang, 2003a. Diagnostic values of serum levels of HA, PCIII, CIV and LN to the liver fibrosis in children with beta-thalassemia major. *Zhonghua Er Ke Za Zhi.*, 41: 603-606.
- Xu, J., Y. Fu and A. Chen, 2003b. Activation of peroxisome proliferator-activated receptor- γ contributes to the inhibitory effects of curcumin on rat hepatic stellate cell growth. *Am. J. Physiol. Gastrointest. Liver Physiol.*, 285: 20-30.
- Xu, X.Q., Y. Ning, P. Li, Z.H. Shen and L. Lou, 2011. Pathological analysis of hepatic fibrosis in pigs infected with *Taenia solium*. *J. Pathogen Biol.*, 6: 344-345.
- Ye, F.Y., 1997. National Clinical Laboratory Procedures. 2nd Edn., Southeast University Press, USA., pp: 206-216.
- Yoshikawa, M., K. Ninomiya, H. Shimoda, N. Nishida and H. Matsuda, 2002. Hepatoprotective and antioxidative properties of Salacia reticulate: Preventive effects of phenolic constituents on CCl4-induced liver injury in mice. *Biol. Pharm. Bull.*, 25: 72-76.
- Zhang, X.X., Y. Yang and M.Z. Chen, 2003. Effect of total polysaccharide of Astragalus on proliferation and collagen production of HSC-T6 cells. *Chinese J. Clin. Pharmacol. Therapeutics*, 06: 645-647.
- Zheng, J.F., L.J. Liang, C.X. Wu, J.S. Chen and Z.S. Zhang, 2006. Transplantation of fetal liver epithelial progenitor cells ameliorates experimental liver fibrosis in mice. *World J. Gastroenterol.*, 12: 7292-7298.
- Zhuoming, U., 1998. Practice of Histological Techniques. 2nd Edn., People's Health Publishing House, Beijing, pp: 8-70.
- Zou, L.Y., T. Wu and L. Cui, 2002. Liver cirrhosis induced bone loss in mice and the prevention effect of astragalus polysaccharides. *Chinese J. Integrated Traditional Western Med. Liver Dis.*, 02: 95-98.