

Extracorporeal Shock Wave Therapy Improves the Impaired Neovascularization in Diabetic Wound Healing via Altering the Expression of Angiopoietin-1 and Angiopoietin-2

¹Xiaoyu Yan, ¹Guang Yang, ²Xiangguo Cheng, ¹Cheng Liang, ¹Yimin Chai,
¹Congfeng Luo and ¹Bingfang Zeng

¹Department of Orthopedic Surgery, Shanghai Sixth People's Hospital,
Shanghai Jiao Tong University, ²Shanghai Limb Microsurgery Institution,
Yishan Road 600, Xuhui District, 200233 Shanghai, P.R. China

Abstract: The present research is to observe the effect of Extracorporeal Shock Wave Therapy (ESWT) on neovascularisation and expression of Ang-1, Ang-2 and VEGF in promoting excisional wound healing in diabetic rat model. Excisional wounds were made in STZ-induced diabetic rats and randomly divided into treatment, diabetic control and normal control groups. Wound in treatment group was treated by ESWT with 0.11 mJ/mm², 1.5 Hz and 500 pulses 1 day post-wounding. In diabetic and normal control groups, wound received no ESWT. Wound closing rate and healing time were calculated. Granulation tissue, neovascularization and expression of Ang-1, Ang-2 and VEGF in wound tissue from different groups were compared. The results showed that healing of diabetic wound was poor and expressions of angiopoietin-1, angiopoietin-2 and VEGF were altered as compared with normal wound. After ESWT however, microvessels and granulation tissue were increased and the expressions of VEGF and Ang-1 were increased while Ang-2 expression was decreased, respectively. In conclusion, abnormal expression of Ang-1, Ang-2 and VEGF may contribute to poor neovascularization and impaired healing in the diabetic wound and topical ESWT application can improve diabetic wound healing by enhancing neovascularisation and altering the expression of Ang-1, Ang-2 and VEGF. ESWT may represent a feasible method for improving the impaired healing of diabetic wound.

Key words: Diabetes, wound healing, neovascularisation, angiogenesis, extracorporeal shock wave therapy, angiopoietins

INTRODUCTION

Poor healing of diabetic wound remains a major complication of diabetes and may result in morbidity, amputation of lower limb or even death (Cavanagh *et al.*, 2005). Treatment options include aggressive debridement, treatment of infection, hyperbaric oxygen, negative pressure wound therapy and topically applied biologically derived molecules. However, potential side effects and cost effectiveness are significant factors associated with these treatments. Diabetic wound healing still pose a formidable challenge in clinical practice (Boulton *et al.*, 2005; Snyder, 2005) and it was extremely urgent to understand its pathogenesis and develop safer and more effective treatment methods.

Extracorporeal Shock Wave Therapy (ESWT) recently has been shown to induce neovascularization and modulation of proangiogenic growth factor expression in ischemic tissues. It has been used to treat critical myocardial and limb ischemia (Ito *et al.*, 2011;

Zimpfer *et al.*, 2009) (Oi *et al.*, 2008) and ischemic skin flaps (Keil *et al.*, 2011; Meirer *et al.*, 2007; Yan *et al.*, 2008). Researchers have also demonstrated that the vascular effect of ESWT on ischemic skin flap was mediated through enhanced expression of nitric oxide, nitric oxide synthase and Vascular Endothelial Growth Factor (VEGF) (Yan *et al.*, 2008). Hence, ESWT was recently used in treatment of acute and chronic wound (Schaden *et al.*, 2007; Wolff *et al.*, 2011) but its impact on diabetic wound healing remains controversial. The earlier study (Yang *et al.*, 2011) demonstrated that ESWT could increase collagen content and improve healing of incisional wound in diabetic rats. However, the mechanism through which it improves diabetic wound healing has not been fully elucidated (Qureshi *et al.*, 2011).

Wound healing crucially relies on new blood vessels formation in the wound bed (Neal, 2001; Tonnesen *et al.*, 2000) which participate in granulation tissue formation

and provide nutrition and oxygen to growing tissues (Amadeu *et al.*, 2003). In diabetic wound, neovascularization has been shown to be significantly impaired resulting in decreased time of closure (Beckman *et al.*, 2002; Chao and Cheing, 2009). Augmentation of impaired neovascularization plays an important role in improving delayed wound healing.

Neovascularisation is regulated by multiple angiogenic factors (Risau, 1997). VEGF is the most important growth factor in angiogenesis (Harry and Paleolog, 2003). It promotes endothelial cells' proliferation and migration. Angiopoietins (Angs) are known to research in concert with VEGF in vascular growth, development and maintenance as well as in the regulation of microvascular permeability (Holash *et al.*, 1999). Although, ESWT may be an effective angiogenic strategy for a variety of ischemic diseases (Ito *et al.*, 2009), the impact of ESWT on angiopoietins expression still remains unknown and whether ESWT can promote the neovascularisation via altering the expression of Ang-1, Ang-2 and VEGF in diabetic wound is unclear.

In the present study, therefore, the effect of ESWT on neovascularisation and wound healing was observed in full-thickness excisional wound model of Streptozotocin (STZ) induced diabetic rat and the expressions of Ang-1, Ang-2 and VEGF in wound treated with and without ESWT were also analyzed.

MATERIALS AND METHODS

Experimental animals and establishment of the diabetes model: This study was approved by the Animal Research Committee of Shanghai Jiao Tong University School of Medicine. Male Sprague-Dawley rats with body weight of 180-200 g were randomly divided into three groups (n = 48 per group):

- ESWT group, diabetic wound was created and received one session of ESWT on day 1 post-wounding
- Diabetic control group, diabetic wound was created but received no ESWT
- Normal control group, excisional wound in normal rat was created but received no ESWT

After arrival, rats were housed two per cage on a 12:12 h light-dark schedule and habituated to the laboratory environment for 1 week prior to use. They were given regular standard rat chow and water *ad libitum* throughout the experiment. Diabetes was induced by injection of Streptozotocin (STZ) as described by (Ozkaya *et al.*, 2007). Rats were fasted for 12 h before a

single intraperitoneal injection of STZ (60 mg kg⁻¹; Sigma Co., USA) dissolved in citrate buffer (0.1 mol L⁻¹; pH 4.5). Rats in normal control group were injected with an equivalent volume of citrate buffer. Diabetes was defined as a blood glucose level of >300 mg dL⁻¹ at 3 days after STZ injection. Blood glucose levels were monitored using a one Touch ultra glucometer (Johnson and Johnson Co., USA) twice a week.

Production of full-thickness excisional wound: Excisional wound model was produced in these rats at 2 months after the onset of STZ. All rats were anesthetized with intraperitoneal injection of ketamine (80 mg kg⁻¹). Back barbering and conventional disinfection were carried out. The skin flap was excised to create a single full-thickness, circular 18 mm diameter (254 mm²) excisional wound area. Incisions were made under sterile conditions and the entire flap was undermined below the level of dorsal fascia. Wounds were kept open throughout the entire experiment without dressing.

Extracorporeal shock wave treatment: Before ESWT was applied, a sterile ultrasound transmission gel (Pharmaceutical Innovations Inc., USA) was applied directly to the wound and wound margin as conductive medium between wound and ESW apparatus (Orthospec, Medispec Ltd., Israel). According to the results of the pilot study, 500 impulses of ESWT (flux density level: 0.11 mJ/mm²; 3 Hz) were applied on the wound and wound margin in ESWT group. In normal and diabetic control groups, wound was also smeared with transmission gel but no ESWT was administered.

Assessment of wound healing: Photography was carried out for wound on day 1, 3, 7 and 14 post-wounding. Image Tool 3.0 Software was used to calculate wound areas. Percentage wound closure for day X was expressed using the equation:

$$\text{Percentage wound closure rate} = \left[\frac{\text{Original area} - \text{non-healing area}}{\text{Original area}} \right] \times 100\%$$

Tissue collection: On day 3, 7 and 14 post-wounding, the rats were sacrificed using an overdose of ketamine. The entire wound and its 2 cm margin tissue was harvested and divided into two halves along the longitudinal midline. One half was fixed in 10% buffered formalin and embedded in paraffin for histopathological examination by HE staining and immunohistochemical staining of CD31. The other half was kept at -80°C for subsequent detection of VEGF, Ang-1 and Ang-2.

Histological evaluation of wound: Skin specimens were cut into 5 μ m thick sections and stained with Hematoxylin-Eosin (H&E). Evaluation of all sections was performed by an experienced pathologist without knowledge of the previous treatment. For each specimen, three separated sections were randomly selected for histological evaluation. Neovascularization, granulation tissue and epithelialization were evaluated semi-quantitatively using accepted wound scoring protocols published previously (Abramov *et al.*, 2007). Wound healing scores were assigned a value between 0 and 4 as follows: 0 = none; 1 = rare or minimal; 2 = moderate; 3 = abundant and 4 = severe or marked.

Micro Vessels Density (MVD): Skin specimens were cut into 5 μ m thick sections and stained with immunohistochemical staining of CD31. Endothelial cell number was observed and microvessels density ($\times 400$ magnification) was assessed in 5 fields for each specimen by a blinded pathologist.

Determination of VEGF, Ang-1 and Ang-2 protein content in wound by ELISA: The protein content of VEGF, Ang-1 and Ang-2 in wounds was determined by ELISA. Briefly, tissues were homogenized in 1.0 mL of PBS containing complete protease inhibitor cocktail (Boehringer Mannheim). Homogenates were centrifuged to remove debris and were filtered through a 1.2 μ m pore syringe filter. Total protein content of Ang-1, Ang-2 and VEGF in homogenized wound samples was measured with ELISA kit (R&D Systems, Minneapolis, MN) according to the manufacturer's protocol. Concentration was expressed as pictograms per milligram of total protein in the sample.

Quantification of VEGF, Ang-1 and Ang-2 mRNAs by real-time PCR: Total RNA from wound samples was isolated with a commercial kit (Trizol Reagent, Invitrogen, USA) according to the manufacturer's protocol and reverse-transcribed to cDNA with M-MLV (D2640A, Takara) following vendor's instructions. Takara SYBR Premix Ex Taq (DRR041A, Takara) amplifications were performed. β -actin mRNA from the same tissue lysate was used as an internal control. The probes and primers for the PCR amplification of the target genes were designed using Primer Express 1.5 Software (Applied Biosystems). The Ang-1 forward and reverse primer sequences were 5'-CTGATGGACTGGGAAGGGAACC-3' and 5'-CACAGGCATCAAACCAACCAACC-3', the Ang-2 forward and reverse primer sequences were 5'-3' 5'-CAACACCGGGAAGATGG-3' and 5'-CTCGCCGGACAG

GTAGAAGT-3', the VEGF forward and reverse primer sequences were 5'-ACCCATGGCAGAAGAAGGAGACAA-3' and 5'-ACTCCAGGCTTTCATCATTGCAGC-3' whereas the β -actin (a house keeping gene) gene's forward and reverse primer sequences were 5'-CTGGCTGGCCGGGACCTGACA-3' and 5'-ATTGCCGATAGTGATGACCTG-3'. Each PCR experiment was repeated three times. The real-time PCR signals (CT) were analyzed using ABI Prism 7300 SDS Software. The relative expression level of the gene of interest was computed with respect to the mRNA expression level of the internal standard β -actin.

Statistical analysis: Experimental data were expressed as the mean \pm Standard Deviation (SD). All statistical analyses were performed using SPSS 17.0 (SPSS Inc., USA). Comparisons between different groups were analyzed by one-way Analysis of Variance (ANOVA) and followed by Student Newman Keuls test. $p < 0.05$ was considered statistically significant.

RESULTS

Closure rate and healing time of wound: Wound closure rate in diabetic rats was much lower at different time points and the average healing time was much longer compared with normal wound ($p < 0.05$) (Table 1, Fig. 1), although wound area of diabetic rats reduced on day 14 and 21. This suggested that wound healing in diabetic rats was obviously delayed. In comparison, closure rate in ESWT group significantly increased more than those in diabetic control group did ($p < 0.05$) (Table 1, Fig. 1) at the same time point, although it was lower than that in normal control group. The average healing time was reduced significantly as compared with diabetic control group ($p < 0.05$) (Table 1). It suggested that ESWT application significantly promoted wound healing of diabetic rats.

Histological analysis: Wound healing scores of the three groups were shown in Table 2. On day 7 and 14, post-wounding, wound in diabetic control group had a

Table 1: The average closure rate of wound at different time point and wound healing time in three groups ($\bar{x} \pm s$)

Groups	Percentage				Healing time (day)
	3 days	7 days	14 days	21 days	
NC	13.42 \pm 4.37	55.05 \pm 7.70	89.05 \pm 4.17	1 \pm 0.00	16.87 \pm 1.96
DM	1.45 \pm 2.06 ^a	13.47 \pm 3.01 ^a	41.13 \pm 5.48 ^a	61.92 \pm 6.25 ^a	29.33 \pm 2.83 ^a
ESWT	4.18 \pm 2.27 ^c	30.68 \pm 4.47 ^{b,c}	64.4 \pm 5.590 ^{b,c}	82.84 \pm 5.83 ^{b,c}	22.83 \pm 3.12 ^b

NC: Normal Control group; DM: Diabetic Control group; ESWT: ESWT group. ^a $p < 0.05$, compared with normal control group; ^b $p < 0.05$, compared with diabetic control group; ^c $p < 0.05$, compared with normal control group

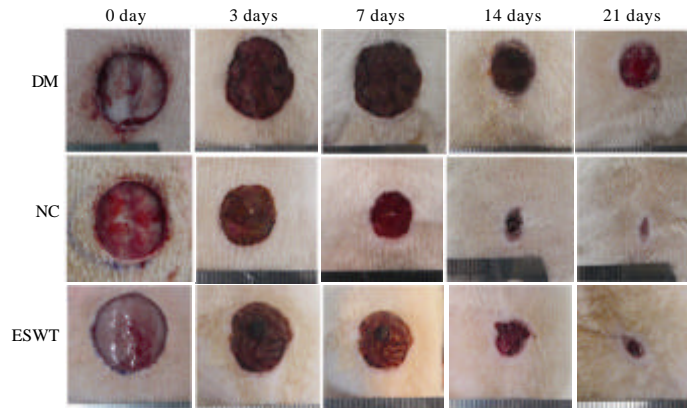


Fig. 1: Representative photographs of wound closure over time. There was a significant acceleration of wound healing in ESWT group and delayed healing in diabetic wound

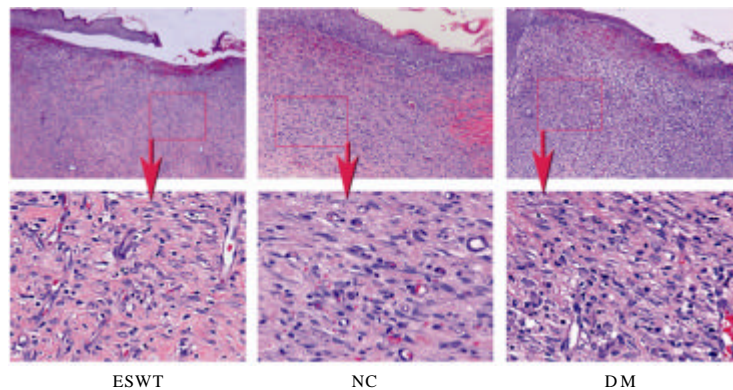


Fig. 2: Histologic photomicrographs of representative HE stained sections of wounds on days 7 post-wounding. Left: ESWT group, a relatively well-vascularized granulation tissue and moderate epithelialization. Middle: normal control group, granulation tissue with more capillaries and better epithelialization. Right: diabetic control group, granulation tissue with sparse capillaries and poor epithelialization

Table 2: The average wound healing scores of the three groups at days 3, 7 and 14 post-wounding, respectively ($\bar{x} \pm s$)

Groups	Granulation	Neovascularization	Epithelialization
3 days			
NC	1.83±0.41	1.50±0.54	1.47±0.47
DM	0.60±0.28 ^a	0.87±0.32 ^a	0.66±0.31 ^a
ESWT	1.02±0.39	1.23±0.51	1.03±0.46
7 days			
NC	2.46±0.54	2.48±0.52	2.50±0.55
DM	1.02±0.36 ^a	1.17±0.41 ^a	1.36±0.44 ^a
ESWT	1.84±0.57 ^b	1.90±0.54 ^b	2.06±0.58 ^b
14 days			
NC	3.43±0.36	3.13±0.28	3.88±0.10
DM	2.16±0.33 ^a	2.06±0.32 ^a	2.33±0.39 ^a
ESWT	3.17±0.36 ^b	3.08±0.31 ^b	3.31±0.14 ^b

^a $p < 0.05$, compared with normal control group; ^b $p < 0.05$, compared with diabetic control group

few of capillaries and immature granulation tissue and epithelialization was less as compared with that in normal wound. In ESWT group, however, markedly

increased neovascularization, granulation tissue and epithelialization were shown as compared with those in diabetic control group (Fig. 2).

Neovascularization of wound: HE stained sections (Fig. 3) revealed a decreased number of blood vessels within the granulation tissue in diabetic mice while sufficient blood vessels within the granulation tissue and wound edge was found in ESWT group as compared to diabetic control.

To quantify neovascularization in granulation tissue, CD31 immunohistochemical analysis was performed on wound sections on day 3, 7 and 14, respectively. MVD (Table 3) in wound of diabetic rats was significantly lower than that in normal rats ($p < 0.05$) while significant increase in blood vessel density was observed in ESWT group when compared with that in diabetic control group

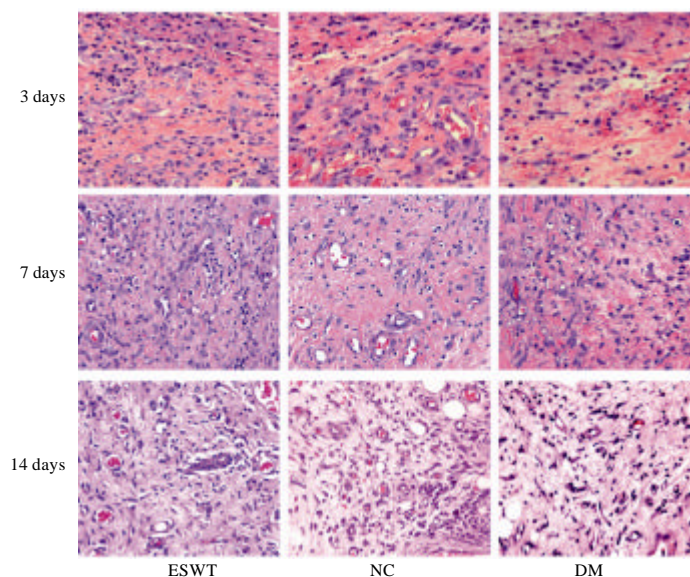


Fig. 3: HE stained sections revealed neovascularization in three groups at 3, 7 and 14 days post-wounding

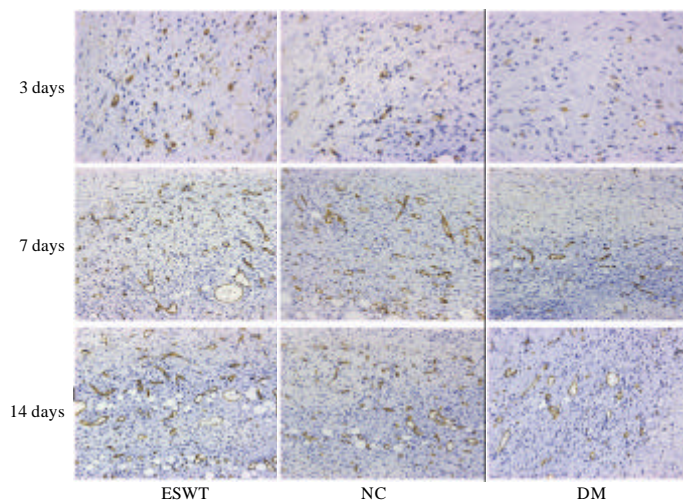


Fig. 4: Microvessel density of the wound was assessed by CD31 immunohistochemistry at 3, 7 and 14 days post-wounding in three groups

Table 3: The mean MVD in three groups at days 3, 7 and 14 post-wounding, respectively ($\bar{X} \pm S$)

Groups	3 days	7 days	14 days
NC	24.25±5.47	51.69±9.24	64.25±10.47
DM	13.53±3.29 ^a	27.72±5.71 ^a	35.29±6.160 ^a
ESWT	22.02±5.78 ^b	47.27±7.52 ^b	58.48±9.550 ^b

^a $p < 0.05$, compared with normal control group; ^b $p < 0.05$, compared with diabetic control group

($p < 0.05$) (Fig. 4, Table 3). In addition, dramatic decrease in endothelial cell number was observed in diabetic wound compared with normal wound as assessed by CD31 staining analysis whereas increase in endothelial cell numbers was observed after ESWT.

Protein content of VEGF, Ang-1 and Ang-2 in wound tissue: Protein content measurement of VEGF, Ang-1 and Ang-2 in three groups was illustrated in Fig. 5.

VEGF protein level was significantly lower in diabetic control group than in normal control group at 3, 7 and 14 days. Although, it was increased after operation, it began to decrease at 7 days post-wounding. In contrast, protein of VEGF in ESWT group was markedly enhanced on day 3, 7 and 14 and sustained at high level for a longer time than in diabetic control group.

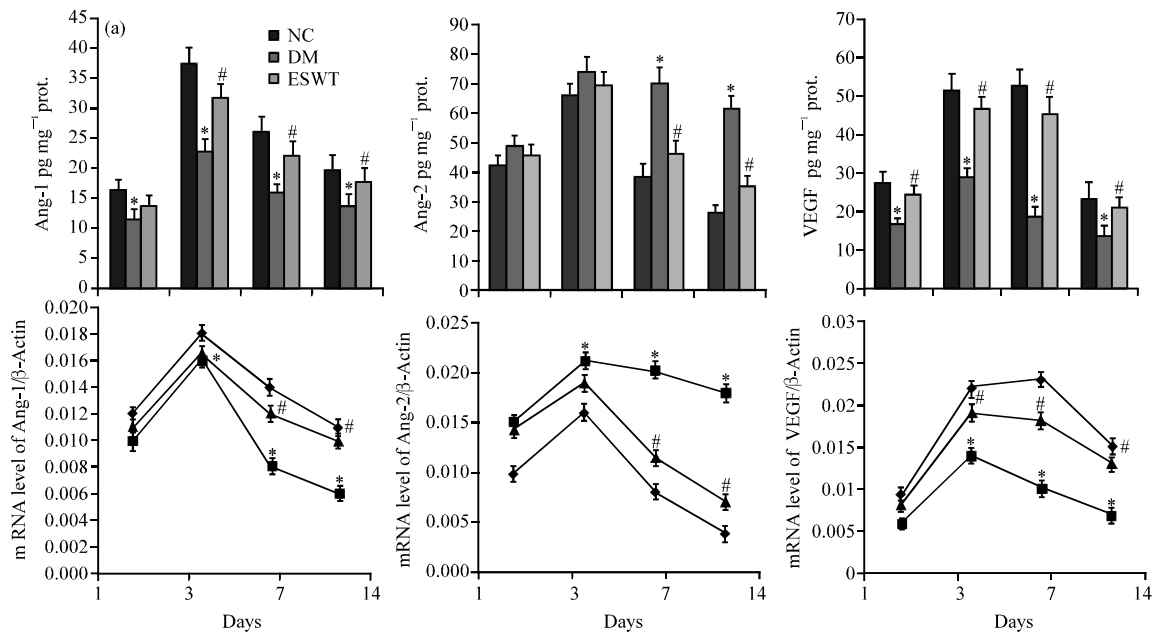


Fig. 5: Protein content and relative mRNA expression of VEGF, Ang-1 and Ang-2 in three groups at different time. * $p < 0.05$, compared with normal control group; # $p < 0.05$, compared with diabetic control group

Ang-1 protein content reached to peak at 3 day and gradually decreased on day 7 and 14 in normal wound. It was reduced in diabetic wound on day 3, 7 and 14 post-wounding. In ESWT group, Ang-1 protein level was moderately increased when compared with that in diabetic group.

Ang-2 protein content in diabetic control group was increased on day 3 and still maintained at significantly increased level at 7 and 14 days whereas it was decreased significantly in normal wound tissue at 7 and 14 days. In ESWT group, Ang-2 was decreased significantly at different time points as compared with diabetic control group, especially at 7 and 14 days post-wounding ($p < 0.05$). Baseline Ang-2/Ang-1 ratio was significantly higher in diabetic wound (4.2~4.5:1) as compared with that in normal wound (2.6:1 at 1 day, 1.7:1 at 3 days, 1.5:1 at 7 days and 1.3:1 at 14 days) ($p < 0.05$). In ESWT group, Ang-2/Ang-1 ratio decreased significantly (3.3:1 at 1 day, 2.2:1 at 3 days, 2.1:1 at 7 days and 1.9:1 at 14 days) ($p < 0.05$).

VEGF, Ang-1 and Ang-2 mRNA expression: The level of VEGF mRNA in diabetic rats was significantly lower than that of normal rats at each time point post-wounding and was shown a marked decline on day 7. ESWT significantly ameliorated this expression decrease and downward trend as shown in Fig. 5.

Ang-1 mRNA expression in normal wound was at high level on day 3 after wounding and then dropped

down gradually. The expression tendency of Ang-1 mRNA in diabetic wound was similar with that in normal wound but the expression level was relatively lower. In ESWT group, however, its expression was elevated and almost arrived at normal level (Fig. 5).

Ang-2 mRNA was also at high level on day 3 post-wounding and then decreased gradually. However, it was still sustained high expression in diabetic rats at 7 and 14 days post-wounding. In ESWT group, its expression was decreased significantly on day 7 and 14 post-wounding as compared with that in diabetic group (Fig. 5).

DISCUSSION

The main findings of this study are as follows. ESWT significantly improved neovascularisation and granulation tissue formation which were impaired in diabetic wound. The expression characteristics of VEGF, Ang-1 and Ang-2 were altered in diabetic wound. But after ESWT, the expressions of VEGF and Ang-1 were increased while Ang-2 expression was decreased. These results indicated that ESWT could alter the pathological state of diabetic wound via reversing the expression of angiogenic growth factors and as a result, improve neovascularisation and ultimately promote the wound healing.

In recent years, ESWT was used to treat diabetic wound experimentally and clinically (Kuo *et al.*, 2009; Schaden *et al.*, 2007; Wang *et al.*, 2011). However, its

therapeutic effect on wound healing remains controversial and its mechanism is still unclear. The results showed that ESWT could significantly decrease the wound size in diabetic rat at 14 day post-wounding although, it could not increase the wound healing rate to the normal level. Moreover, the duration of the wound-healing process was significantly reduced in the ESWT group as compared with the diabetic control group. This demonstrated that ESWT has a positive effect on the wound-healing process.

Wound healing depends on formation of new blood vessels (Brem and Tomic-Canic, 2007). In diabetic wound in the present study, only a few of capillaries and immature granulation tissue were found in the diabetic wound on days 7 and 14. By contrast, sufficient microvessels and granulation tissue were shown in the normal wound-healing process. It implied that new blood vessel formation was impaired in the diabetic wound and thus inhibited wound healing. In the ESWT group, however, the microvessel density within the margin of the wound began to increase at 3 day post-wounding and was elevated at every time point after ESWT. Simultaneously, increased granulation tissue formation was observed in the wound especially at 7 and 14 days post-wounding. Researchers also noted that re-epithelialization was much better in ESWT group as compared with that in diabetic control group at 14 days post-wounding, although it was still less than the normal level. Researchers believe that the increased neogenetic capillaries improve the microcirculation of diabetic wound and provide necessary oxygen and affluent nutrients for cell proliferation and tissue repair and thus improve wound healing.

In the process of wound healing, angiopoietins play critical roles in regulating the events of neovascularisation, including endothelial proliferation, migration and capillary tube-like formation. To explore the potential mechanism that ESWT altered the capability of neovascularization in diabetic wound, analysis of the expression of VEGF, Ang-1 and Ang-2 were performed. The present study showed that the expressions of VEGF, angiopoietin-1 and angiopoietin-2 were altered in diabetic wound but after ESWT, ELISA and real-time PCR demonstrated up-regulated the protein and mRNA levels of Ang-2 in diabetic rats compared with control rats on day 7, 14 and 21 while the protein and mRNA levels of Ang-1 and VEGF were decreased.

VEGF is one of the most well studied growth factors involved in wound healing (Bao *et al.*, 2009). It has been shown to promote vasculogenesis and angiogenesis (Bao *et al.*, 2009). Angiopoietins were identified as important partners of VEGF and play an important role in

physiological vessel growth and in pathological angiogenesis (Li *et al.*, 2003). Ang-1 inhibits Endothelial Cell (EC) apoptosis and stimulates *in vivo* vascular remodeling, vascular enlargement and wound healing (Brindle *et al.*, 2006). Also, it has been shown to restore poorly remodeled and leaky vessels (Uemura *et al.*, 2002) and to regulate both the number and diameter of developing vessels (Jeansson *et al.*, 2011). As natural antagonist of Ang-1, Ang-2 can inhibit Ang-1 induced Tie-2 phosphorylation and thereby promote vascular remodeling (Feraud *et al.*, 2003). It was demonstrated that Ang-2 was highly induced at sites of active angiogenesis which suggested a role in destabilizing existing vessels, leading to a more plastic state (Maisonpierre *et al.*, 1997). The increased production of Ang-2 may block Ang-1 for the function of the stabilization of vascular system, resulting in disrupted blood vessel formation in diabetic wound. The balance between Ang-2 and Ang-1 changes the fate of newly formed blood vessels in wound repair. When the balance was disturbed, new blood vessels would be kept in an unstable state (Fiedler *et al.*, 2003). Hence, the decreased expression of VEGF and Ang-1 and continuously increased expression of Ang-2 may contribute to the poor neovascularisation in diabetic wound.

As a potential angiogenic strategy, ESWT could up-regulate the expression of VEGF and decrease the Ang-2/Ang-1 ratio which was increased in the diabetic wound. At the same time, the impaired neovascularisation and granulation tissue in diabetic wound were observed to be improved significantly after ESWT. Considering the roles of VEGF, Ang-2 and Ang-1 described, researchers believe that ESWT has potential role in decreasing the abnormal Ang-2/Ang-1 ratio to a relatively normal level in diabetic wound thus changing the fate of newly formed blood vessels and improving neovascularization and wound healing.

Furthermore, it was reported that angiopoietin-2 displayed VEGF-dependent modulation of capillary structure and endothelial cell survival (Augustin *et al.*, 2009; Lobov *et al.*, 2002). In the presence of endogenous VEGF, Ang-2 stimulates sprouting of new blood vessels. By contrast, it promotes endothelial cell death and vessel regression if the activity of endogenous VEGF is inhibited. In this study, the over-expression of Ang-2 in the presence of markedly reduced VEGF in diabetic wound was associated with a dramatic decrease in endothelial cell numbers compared with normal wound as assessed by analysis of the endothelium-specific markers CD31. After ESWT application however, angiopoietin-2 expression was reduced to a relatively normal level in diabetic wound and the lower expression of VEGF was increased.

Simultaneously, the number of endothelial cells and microvessels was increased significantly. Therefore, researchers presumed that the altered expression of VEGF, Ang-1 and Ang-2 acted in concert to enhance neovascularization induced by ESWT in diabetic wound.

CONCLUSION

The results of this study suggest that abnormal expression of Ang-1, Ang-2 and VEGF may contribute to poor neovascularization and impaired healing in the diabetic wound and topical ESWT application improves diabetic wound healing by improving neovascularisation and altering the expression of Ang-1, Ang-2 and VEGF. ESWT may represent a feasible method for improving the impaired healing of diabetic wound.

ACKNOWLEDGEMENTS

This project was financially supported by Shanghai Rising-Star Program (A type) (10QA1405400) and National Natural Science Foundation of China (30901565). Researchers thank Dr. Qizhi He (Department of Pathology, Shanghai First Women's and Children's Hospital affiliated to Fudan University) for his assistance in evaluation of the histology sections. Xiaoyu Yan and Guang Yang contributed equally to this study.

REFERENCES

- Abramov, Y., B. Golden, M. Sullivan, S.M. Botros and J.J. Miller, 2007. Histologic characterization of vaginal vs. abdominal surgical wound healing in a rabbit model. *Wound Repair Regen*, 15: 80-86.
- Amadeu, T., A. Braune, C. Mandarin-de-Lacerda, L.C. Porto and A. Desmouliere, 2003. Vascularization pattern in hypertrophic scars and keloids: A stereological analysis. *Res. Pract.*, 199: 469-473.
- Augustin, H.G., G.Y. Koh, G. Thurston and K. Alitalo, 2009. Control of vascular morphogenesis and homeostasis through the angiopoietin-Tie system. *Nat. Rev. Mol. Cell Biol.*, 10: 165-177.
- Bao, P., A. Kodra, M. Tomic-Canic, M.S. Golinko and H.P. Ehrlich, 2009. The role of vascular endothelial growth factor in wound healing. *J. Surg. Res.*, 153: 347-358.
- Beckman, J.A., M.A. Creager and P. Libby, 2002. Diabetes and atherosclerosis: Epidemiology, pathophysiology and management. *JAMA*, 287: 2570-2581.
- Boulton, J.M.P., L. Vileikyte, G. Ragnarson-Tennvall and J. Apelqvist, 2005. The global burden of diabetic foot disease. *Lancet*, 366: 1719-1724.
- Brem, H. and M. Tomic-Canic, 2007. Cellular and molecular basis of wound healing in diabetes. *J. Clin. Invest.*, 117: 1219-1222.
- Brindle, N.P., P. Saharinen and K. Alitalo, 2006. Signaling and functions of angiopoietin-1 in vascular protection. *Circ. Res.*, 98: 1014-1023.
- Cavanagh, P.R., B.A. Lipsky, A.W. Bradbury and G. Botek, 2005. Treatment for diabetic foot ulcers. *Lancet*, 366: 1725-1735.
- Chao, C.Y. and G.L. Cheing, 2009. Microvascular dysfunction in diabetic foot disease and ulceration. *Diabetes Metab. Res. Rev.*, 25: 604-614.
- Feraud, O., C. Mallet and I. Vilgrain, 2003. Expressional regulation of the angiopoietin-1 and -2 and the endothelial-specific receptor tyrosine kinase Tie2 in adrenal atrophy: A study of adrenocorticotropin-induced repair. *Endocrinology*, 144: 4607-4615.
- Fiedler, U., T. Krissl, S. Koidl, C. Weiss and T. Koblizek, 2003. Angiopoietin-1 and angiopoietin-2 share the same binding domains in the Tie-2 receptor involving the first Ig-like loop and the epidermal growth factor-like repeats. *J. Biol. Chem.*, 278: 1721-1727.
- Harry, L.E. and E.M. Paleolog, 2003. From the cradle to the clinic: VEGF in developmental, physiological and pathological angiogenesis. *Birth Defects Res. C Embryo Today*, 69: 363-374.
- Holash, J., P.C. Maisonpierre, D. Compton, P. Boland and C.R. Alexander, 1999. Vessel cooption, regression and growth in tumors mediated by angiopoietins and VEGF. *Science*, 284: 1994-1998.
- Ito, K., Y. Fukumoto and H. Shimokawa, 2009. Extracorporeal shock wave therapy as a new and non-invasive angiogenic strategy. *Tohoku J. Exp. Med.*, 219: 1-9.
- Ito, K., Y. Fukumoto and H. Shimokawa, 2011. Extracorporeal shock wave therapy for ischemic cardiovascular disorders. *Am. J. Cardiovasc. Drugs*, 11: 295-302.
- Jeansson, M., A. Gawlik, G. Anderson, C. Li and D. Kerjaschki, 2011. Angiopoietin-1 is essential in mouse vasculature during development and in response to injury. *J. Clin. Invest.*, 121: 2278-2289.
- Keil, H., W. Mueller, C. Herold-Mende, M.M. Gebhard and G. Germann, 2011. Preoperative shock wave treatment enhances ischemic tissue survival, blood flow and angiogenesis in a rat skin flap model. *Int. J. Surg.*, 9: 292-296.
- Kuo, Y.R., C.T. Wang, F.S. Wang, Y.C. Chiang and C.J. Wang, 2009. Extracorporeal shock-wave therapy enhanced wound healing via increasing topical blood perfusion and tissue regeneration in a rat model of STZ-induced diabetes. *Wound Repair Regen*, 17: 522-530.

- Li, J., Y.P. Zhang and R.S. Kirsner, 2003. Angiogenesis in wound repair: Angiogenic growth factors and the extracellular matrix. *Microsc. Res. Tech.*, 60: 107-114.
- Lobov, I.B., P.C. Brooks and R.A. Lang, 2002. Angiopoietin-2 displays VEGF-dependent modulation of capillary structure and endothelial cell survival *in vivo*. *Proc. Natl. Acad. Sci. USA.*, 99: 11205-11210.
- Maisonpierre, P.C., C. Suri, P.F. Jones, S. Bartunkova and S.J. Wiegand, 1997. Angiopoietin-2, a natural antagonist for Tie2 that disrupts *in vivo* angiogenesis. *Science*, 277: 55-60.
- Meirer, R., A. Brunner, M. Deibl, M. Oehlbauer, H. Piza-Katzer and F.S. Kamelger, 2007. Shock wave therapy reduces necrotic flap zones and induces VEGF expression in animal epigastric skin flap model. *J. Reconstr Microsurg*, 23: 231-236.
- Neal, M.S., 2001. Angiogenesis: Is it the key to controlling the healing process?. *J. Wound Care*, 10: 281-287.
- Oi, K., Y. Fukumoto, K. Ito, T. Uwatoku, K. Abe and T. Hizume, 2008. Extracorporeal shock wave therapy ameliorates hindlimb ischemia in rabbits. *Tohoku J. Exp. Med.*, 214: 151-158.
- Ozkaya, Y.G., A. Agar, G. Hacıoglu and P. Yargicoglu, 2007. Exercise improves visual deficits tested by visual evoked potentials in streptozotocin-induced diabetic rats. *Tohoku J. Exp. Med.*, 213: 313-321.
- Qureshi, A.A., K.M. Ross, R. Ogawa and D.P. Orgill, 2011. Shock wave therapy in wound healing. *Plast Reconstr Surg*, 128: 721e-727e.
- Risau, W., 1997. Mechanisms of angiogenesis. *Nature*, 386: 671-674.
- Schaden, W., R. Thiele, C. Kolpl, M. Pusch, A. Nissan and C.E. Attinger, 2007. Shock wave therapy for acute and chronic soft tissue wounds: A feasibility study. *J. Surg Res.*, 143: 1-12.
- Snyder, R.J., 2005. Treatment of nonhealing ulcers with allografts. *Clin. Dermatol.*, 23: 388-395.
- Tonnesen, M.G., X. Feng and R.A. Clark, 2000. Angiogenesis in wound healing. *J. Investig. Dermatol. Symp. Proc.*, 5: 40-46.
- Uemura, A., M. Ogawa, M. Hirashima, T. Fujiwara and S. Koyama, 2002. Recombinant angiopoietin-1 restores higher-order architecture of growing blood vessels in mice in the absence of mural cells. *J. Clin. Invest.*, 110: 1619-1628.
- Wang, C.J., R.W. Wu and Y.J. Yang, 2011. Treatment of diabetic foot ulcers: A comparative study of extracorporeal shockwave therapy and hyperbaric oxygen therapy. *Diabetes Res. Clin. Pract.*, 92: 187-193.
- Wolff, K.S., A. Wibmer, M. Pusch, A.M. Prusa and M. Pretterklieber, 2011. The influence of comorbidities and etiologies on the success of extracorporeal shock wave therapy for chronic soft tissue wounds: Midterm results. *Ultrasound Med. Biol.*, 37: 1111-1119.
- Yan, X., B. Zeng, Y. Chai, C. Luo and X. Li, 2008. Improvement of blood flow, expression of nitric oxide and vascular endothelial growth factor by low-energy shockwave therapy in random-pattern skin flap model. *Ann. Plast. Surg*, 61: 646-653.
- Yang, G., C. Luo, X. Yan, L. Cheng and Y. Chai, 2011. Extracorporeal shock wave treatment improves incisional wound healing in diabetic rats. *Tohoku J. Exp. Med.*, 225: 285-292.
- Zimpfer, D., S. Aharinejad, J. Holfeld, A. Thomas and J. Dumfarth, 2009. Direct epicardial shock wave therapy improves ventricular function and induces angiogenesis in ischemic heartfailure. *J. Thorac. Cardiovasc. Surg*, 137: 963-970.