

## GUCY2D Gene Mutation in a Family with Leber Congenital Amaurosis

<sup>1</sup>Wu Li, <sup>2</sup>Li Pengcheng and <sup>1</sup>Xing Yiqiao

<sup>1</sup>Department of Ophthalmology, Renmin Hospital of Wuhan University,  
99 Ziyang Lu Wuchang District, Wuchang, China

<sup>2</sup>Department of Ophthalmology, Union Hospital, Tongji Medical College,  
Huazhong University of Science and Technology, Wuhan, Hubein, China

**Abstract:** To detect and analyze *GUCY2D* gene mutations in a family with Leber Congenital Amaurosis (LCA) in China. Researchers collected peripheral blood samples from affected family members in three generations. Genomic DNA was extracted and all 20 exons of the *GUCY2D* gene were amplified using the DNA of the proband as the template. The ABI 3100 automated sequencer was used for sequencing. The sequencing results revealed one Single Nucleotide Polymorphism (SNP): c.154G.T (p.A52S) on exon 2 of the *GUCY2D* gene. The encoded amino acid changed from alanine to serine. All affected family members carried this SNP.

**Key words:** Leber congenital amaurosis, *GUCY2D* gene, disorder, physical signs, amino acid, template

### INTRODUCTION

As early as 1896, Theodor Leber described Leber Congenital Amaurosis (LCA) as a type of retinitis pigmentosa. This disease is the most severe of inherited retinal diseases has the earliest onset and is the leading cause of congenital bilateral blindness in children (accounting for 10-20%). It has diverse clinical manifestations and genetic heterogeneity. It is generally inherited in an autosomal recessive manner.

Recently developed molecular biology techniques show that at least 15 genes related to the disease onset can explain about 65% of clinical cases (Vallespin *et al.*, 2007). *GUCY2D* is one of the most common pathogenic genes, found in approximately 20% of cases (Hanein *et al.*, 2004). Recently, a family with LCA were confirmed in the hospital in which *GUCY2D* gene mutation analysis were conducted. Researchers herein reported the results as follows.

### MATERIALS AND METHODS

**Clinical data:** A family with LCA was identified in Renmin Hospital of Wuhan University in August, 2011. The three-generation family included a total of 16% whose ages ranged 9-65 years. There were 3 male patients with 6 eyes affected (Fig. 1). The proband, III:12 was born in Wuhan, Hubei province. In August, 2011, the patient sought medical help at the hospital due to bilateral poor vision since, childhood complicated by night blindness for 18 years and blindness for 5 years. Ophthalmic

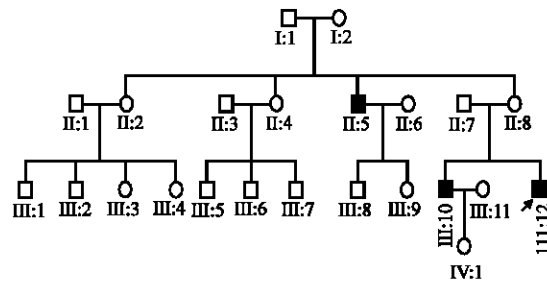


Fig. 1: Pedigree of a family with LCA. Autosomal recessive transmission of the disease is evident. Black symbols represent affected members. The arrow signals the proband

examination revealed an uncorrected visual acuity of hand motion at 20 cm in both eyes; visual acuity could not be corrected. The bilateral corneas were transparent and the iris texture was normal. The bilateral lenses were transparent. Fundus examination found clear optic disc boundaries with a A:V = 2:3 and no abnormalities such as proliferation of retinal pigment epithelial cells.

Goldmann applanation tonometry was used to measure the Intraocular Pressure (IOP) which was 16 mmHg in both eyes (1 mmHg = 0.133 kPa). Bilateral nystagmus was present and no oculo-digital phenomenon was found. Electroretinography (ERG) was extinguished (Fig. 2). The diagnosis of bilateral Leber congenital amaurosis was made. Family members reported no family history of consanguineous marriage. The patient's mother had a normal pregnancy and took no medication during

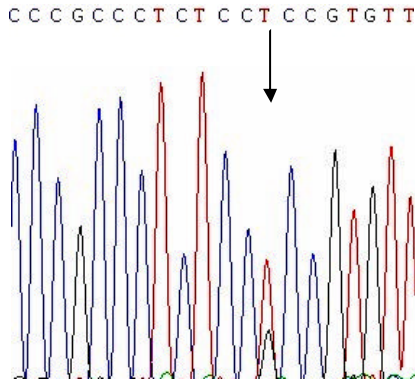


Fig. 2: Partial nucleotide sequence of *GUCY2D*. A: The sequence in an affected subject shows a heterozygous G>T transversion (indicated by the arrow). The SNP results in a change from alanine to serine

pregnancy. All patients were born at full-term. The study was approved by the hospital Institutional Review Board.

**DNA extraction:** After written informed consent was obtained from the members of this family, 10 mL of peripheral venous blood was drawn from each family member (n = 21). The anticoagulant ethylenediamine tetraacetic acid was added and genomic DNA was extracted using the Wizard genomic DNA Purification kit (Promega, Madison, WI). The operation followed the kit instructions.

**Primer design and Polymerase Chain Reaction (PCR):** It is known that the pathogenic gene *GUCY2D* has 20 exons. All exon primers were designed as previously described (Li *et al.*, 2011). The DNA of proband III2 was used as the template and all exons of the *GUCY2D* gene were amplified. The PCR fluid (10  $\mu$ L) contained template DNA of the proband (10 ng), 10 $\times$ buffer (1  $\mu$ L), MgCl<sub>2</sub> (2.5 mmol), triphosphate deoxyribose nucleoside (200  $\mu$ mol), upstream and downstream primers (5 pmol each) and Takara Taq polymerase (0.5 U). PCR conditions were as follows. Initial denaturation was carried out at 94°C for 5 min followed by 30 cycles of denaturation at 94°C for 30 sec, annealing at 62°C for 30 sec and extension at 72°C for 45 sec. The final extension was carried out at 72°C for 10 min.

**Gene sequencing analysis:** PCR amplification products were analyzed using 2% agarose gel electrophoresis and recycled and purified using the Minigel Recycling kit (Shanghai Huashun Bio-Engineering Co., Ltd. Shanghai, China). The purified products were examined and the BigDye 3.1 (Applied Biosystems, Foster City, CA)

sequencing kit was used for the dideoxy chain termination sequencing reaction. Sequencing analysis was carried out on the ABI 3100 Genetic Analyzer using the DNA Sequencing Analysis Version 5.2 Software (Applied Biosystems, Foster City, CA) to collect the sequence data. direct sequencing.

## RESULTS AND DISCUSSION

**Family investigation:** The clinical diagnosis of the family was Leber congenital amaurosis. All members affected by the disease experienced poor vision and night blindness since childhood. Nystagmus was present in all affected family members and no marked fundus abnormalities were observed. In this three-generation family, 3 members were affected by the disease. Analysis of the pedigree indicated autosomal recessive inheritance.

**Sequencing of the exons of the *GUCY2D* gene:** All exons of the *GUCY2D* gene from proband III2 were sequenced. A G to T SNP locus at the 154th base of the cDNA was found. The SNP was on exon 2 of the *GUCY2D* gene. This mutation led to a change of the 52nd amino acid codon from GCC to TCC and the encoded protein changed from alanine to serine.

The sequencing results for all 16 members in the family showed that all 3 affected members carried this SNP as well as one healthy member. This SNP, c.154G.T may be involved in the pathogenesis of LCA in the family (Fig. 3). The most notable clinical manifestations of LCA are severe binocular vision abnormalities inherited in an autosomal recessive manner including nystagmus and a variety of fundus changes. The fundus can be completely normal have a retinitis pigmentosa-like pigment change or show a severely declined cone rod reaction on the ERG extinguished ERG may also be present. Night blindness was observed in 77% of patients (Lewis, 1988). Other features include a high degree of refractive error and oculo-digital phenomena.

Progressive exacerbation of night blindness results in gradually reduced visual field in patients eventually affecting the macula and leading to blindness. The disease greatly restricts patients ability to function. LCA should be differentiated from retinitis pigmentosa and USHER syndrome, diseases with completely different pathogenic genes. Correct clinical diagnosis is very important in order to guide genetic diagnosis. Differentiation requires careful recording of the medical history and family history along with ERG examination. The patients in this family suffered from simple LCA. All had poor vision since childhood. With increasing age, vision decreased slowly, accompanied by night blindness and nystagmus.




Fig. 3: Full-field ERG of the both eyes showing that all responses were non-recordable

The diagnosis was definite. According to the research, *GUCY2D* gene mutations are the most common cause of LCA (Hanein *et al.*, 2004). The *GUCY2D* gene is located on 17p13.1 has 20 exons and encodes the protein retinal Guanylate Cyclase 1 (GC1). GC1 consists of 3312 amino acids and is located on the photoreceptor outer segment disk membrane (Koch *et al.*, 2002). Its function is to restore the level of the second signaling pathway molecule, cGMP in cells after light stimulus. In the dark environment, the level of cGMP is steady keeping cGMP-gated sodium channels open and allowing partial depolarization of the cells by allowing an inward influx of current. Light exposure leads to cGMP hydrolysis and channel closure, facilitating a sharp decline in intracellular  $Ca^{2+}$  and hyperpolarization of the cells. When the calcium concentration is low, GC1 activity is increased and the synthesis of cGMP is increased resulting in the reopening of the channels and restoration of the dark state. GC1 mutations result in an inability to synthesize cGMP and persistent closure of cGMP-gated channels, a state equivalent to long-term light exposure. The ultimate result is rod and cone cell degeneration (Larhammar *et al.*, 2009; Hunt *et al.*, 2010).

The pathogenic genotype of LCA has a certain relationship with its phenotype. Patients with a mutation in the coding sequence of the *GUCY2D* gene often present with poor vision since childhood (visual acuity is

often between light sense and 0.02). Their visual acuity often declines slowly with increasing age and combined high myopia is common. The posterior pole of the fundus is basically normal with no depigmentation or proliferation. Some patients suffer from congenital cataracts (Galvin *et al.*, 2005). In the Chinese population, the mutation loci of the gene are exons 2, 11 and 12 and >65 types of mutations are known to exist including several SNPs.

Sometimes, mutations of other genes are also found (Li *et al.*, 2011). Based on the clinical manifestations of the present family, researchers speculate that the pathogenic gene was *GUCY2D* and therefore conducted sequencing analysis for the 20 exons of the *GUCY2D* gene. However, no mutation was detected in the family and only a SNP locus, c.154G.T was found. This common SNP leads to an amino acid substitution from alanine to tryptophan. The results suggest that this family may also have combined changes in other genes (Li *et al.*, 2011) and elucidation of the pathogenesis awaits further study.

## CONCLUSION

Clinical manifestations of LCA are diverse and a clinical diagnosis relies on medical history, physical signs and other details. The SNP of the *GUCY2D* gene may be involved in disease onset of this inherited disorder making it a potential clinical marker as well as a target for basic research.

## ACKNOWLEDGEMENT

Researchers appreciated all of the family involved in this study.

## REFERENCES

- Galvin, J.A., G.A. Fishman, E.M. Stone and R.K. Koenekeop, 2005. Evaluation of genotype-phenotype associations in leber congenital amaurosis. *Retina*, 25: 919-929.
- Hanein, S., I. Perrault, S. Gerber, G. Tanguy and F. Barbet *et al.*, 2004. Leber congenital amaurosis: Comprehensive survey of the genetic heterogeneity, refinement of the clinical definition and genotype-phenotype correlations as a strategy for molecular diagnosis. *Hum. Mutat.*, 23: 306-317.
- Hunt, D.M., P. Buch and M. Michaelides, 2010. Guanylate cyclases and associated activator proteins in retinal disease. *Mol. Cell. Biochem.*, 334: 157-168.
- Koch, K.W., T. Duda and R.K. Sharma, 2002. Photoreceptor specific guanylate cyclases in vertebrate phototransduction. *Mol. Cell. Biochem.*, 230: 97-106.

- Larhammar, D., K. Nordstrom and T.A. Larsson, 2009. Evolution of vertebrate rod and cone phototransduction genes. *Philos. Trans. Soc. Lond. Biol. Sci.*, 364: 2867-2880.
- Lewis, R.A., 1988. Juvenile Hereditary Macular Dystrophies. In: *Retinal Dystrophies and Degenerations*, Newsome, D.A. (Ed.). Raven Press, New York, USA., ISBN-13:9780881671865, pp: 115-134.
- Li, L., X. Xiao, S. Li, X. Jia and P. Wang *et al.*, 2011. Detection of variants in 15 genes in 87 unrelated Chinese patients with *Leber congenital amaurosis*. *PLoS One*, Vol. 6.
- Vallespin, E., D. Cantalapiedra, R. Riveiro-Alvarez, R. Wilke and J. Aguirre-Lamban *et al.*, 2007. Mutation screening of 299 Spanish families with retinal dystrophies by *Leber congenital amaurosis* genotyping microarray. *Invest. Ophthalmol. Vis. Sci.*, 48: 5653-5661.