

Nephrotoxicity of Acetamiprid on Male Mice and the Rescue Role of Vitamin E

Jiao-Jiao Zhang, Yi Wang, Hai-Yang Xiang, Jia-Hua, Zhang and Xian-Zhong Wang
Chongqing Key Laboratory of Forage and Herbivore, College of Animal Science and Technology,
Southwest University, 400716 Chongqing, China

Abstract: Acetamiprid has a wide range of effect on physiological functions in mammals. The objective of this study was to examine the effect of acetamiprid on kidney of male mice and to study the ameliorative role of antioxidant on the nephrotoxicity of acetamiprid. Fifty adult Kunmin male mice (25-30 g) were divided into five groups (n = 10 per group): controls, blanks, acetamiprid alone, acetamiprid and vitamin E and E alone. All groups were treated for 35 days. The results showed that acetamiprid significantly increased the activity of urea, Cr and the concentration of P and decreased the concentrations of UA and Ca. The mice treated with acetamiprid had damaged renal corpuscles and tubules based on the histological structure of kidney. Furthermore, the acetamiprid residue in kidneys was lower than that in livers which suggests that renal function may be affected through the indirect action of acetamiprid metabolites. Vitamin E significantly ameliorated the effects of acetamiprid. Researchers conclude that acetamiprid could damage kidney which may be induced by the oxidative stress of acetamiprid metabolites. As an antioxidant, vitamin E can reduce the nephrotoxicity of acetamiprid.

Key words: Acetamiprid, nephrotoxicity, vitamin E, oxidative stress, tubules, kidney

INTRODUCTION

Acetamiprid is a synthetic chlorinated nicotimine pesticide against insects that have gained resistance to ganophosphate, carbamate and synthetic pyrethroid (Shengyun *et al.*, 2005). Acetamiprid mainly affect the nervous system of insects through the excessive activation of acetylcholine receptor (Tan *et al.*, 2007). Some studies have showed that acetamiprid has acute or chronic impairments on human and animals. Humans suffered from headaches, dizziness, nausea, vomiting and other symptoms after the inhalation of acetamiprid (Chen *et al.*, 2007). The long-term intake of high doses of acetamiprid can lead to breast cancer in adult mouse and rib malformations in fetal mice (Green *et al.*, 2005a, b). The previous experiment showed that acetamiprid damaged male reproductive function through inducing oxidative stress in the testes of mouse (Zhang *et al.*, 2011). To the knowledge, there is no data with regards to whether acetamiprid influences kidney. However, acetamiprid can alter the activity of antioxidative enzymes and its metabolites can be regarded as agonists of nicotine and induced Nitric Oxide Synthase (iNOS) in mice (Ford and Casida, 2006). The present study was thus designed to examine the nephrotoxicity of acetamiprid and assess the ameliorative role of vitamin E.

MATERIALS AND METHODS

Acetamiprid(E)-N-[(6-chloro-3-pyridinyl)methyl]-N'-cyano-N-methylethananimidamide, C₁₀H₁₁ClN₄) (>97% pure) was obtained from Shanghai Yongyuan Chem., Ltd. (Shanghai, China). Vitamin E (natural soft capsule, 250 mg/tablet) was purchased from yangshengtang Ltd. All of the other reagents used in the study were of analytical grade and were obtained from Beijing Ding Guo Chang Sheng Biotech., Co., Ltd.

Animals and experimental design: Kunmin male mice weighing 25-30 g were provided by the Chongqing Academy of Chinese Materials Medica. All animal treatment procedures were consistent with the previous method (Zhang *et al.*, 2011), approved by the Animal Care Committee of Southwest University.

In this experiment, the dose of acetamiprid was 30 mg kg⁻¹ body weight. The groups were as follows: control, blank (peanut oil), 30 mg kg⁻¹ acetamiprid, 30 mg kg⁻¹ acetamiprid + 20 mg kg⁻¹ vitamin E and 20 mg kg⁻¹ vitamin E. Both acetamiprid and vitamin E were dissolved in 0.1 mL peanut oil and delivered orally every day for 35 days. At 36 days after the start of treatment, all mice were anesthetized with halothane and killed by aseptically severing the neck vessels.

Hematological biochemical analysis: Blood samples were taken from the eye sockets of mice under anesthesia using a 1 mL syringe before they were sacrificed (Wang *et al.*, 2009). Blood samples were centrifuged at 5,000 rpm for 4 min and the serum samples were stored at 4°C for hematological biochemical analysis. The activities of urea, Uric Acid (UA), Creatinine (Cr) and the concentrations of Calcium (Ca), Phosphor (P) were detected according to the method described by Manna *et al.* (2004) using an Automatic Chemistry Analyzer (Olympus AU400).

Histological structure of the kidney: Samples of kidney were immersion-fixed in Bouin's solution for histopathology and embedded in paraffin. Serial sections (5 µm thick) were cut and stained with Hematoxylin and Eosin (H&E) according to the previous method (Zhang *et al.*, 2011).

Total residues of acetamiprid in kidneys: Kidneys tissues (0.2 g) were ultrasonically extracted according to the previous method (Zhang *et al.*, 2011) and samples were detected by LC-MS/MS (Liquid Chromatography Tandem Mass Spectrometry).

Statistical analysis: All data are reported as means±Standard Error of the Mean (SEM). Statistical analyses were performed using SPSS (Version 16.0; SPSS Inc., Chicago, IL, USA). Data were analyzed by one-way

ANOVA and the Fisher's Least Significant Difference (LSD) Method to determine treatment differences. A probability of $p < 0.05$ was considered to be statistically significant.

RESULTS AND DISCUSSION

Effect of acetamiprid on histological structure of the kidneys: In the control group, the structure of glomuses was clear, capsular spaces were small, the boundaries of the visceral layer and parietal layer of renal capsule were clear, the structure of epithelial cells in proximal convoluted tubules and distal convoluted tubules was normal (Fig. 1a). In the acetamiprid group, the glomuses were atrophied and disintegrated, capsular spaces got widened obviously, the visceral layer and parietal layer of renal capsule were destroyed and some of them were disappeared, the epithelial cells in proximal convoluted tubules and distal convoluted tubules were swollen and some epithelial cells had vacuolization, the structure of epithelial cells was unclear, there were some cell fragments in the tubules (Fig. 1c).

In the acetamiprid with vitamin E group, the atrophy degree of glomuses was decreased and the capsular spaces were smaller in comparison to the acetamiprid only group, the boundaries of visceral layer and parietal layer of renal capsule were clear, the epithelial cells in proximal convoluted tubules and distal convoluted tubules were slightly swollen, cell fragments were visible in some

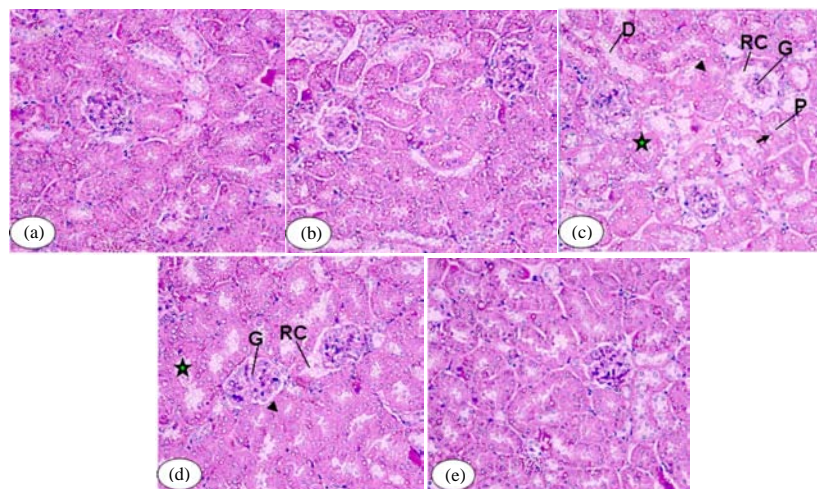


Fig. 1: Effect of acetamiprid on the histological structure of the kidneys ($\times 200$). Mice were given acetamiprid for 35 days and the histological structure of the kidney was then examined with the use of hematoxylin and eosin staining. Photomicrographs show the kidneys of mice from each treatment group: a) control; b) blank (peanut oil); c) acetamiprid; d) acetamiprid + vitamin E; e) Vitamin E. G: Glomuses; RC: Renal Capsule; P: Proximal convoluted tubules; D: Distal convoluted tubules. Arrows show vacuolization epithelial cells, triangles show swollen epithelial cells, pentagon stars show tissue fragments in the tubules

tubules (Fig. 1d). Compared to the controls, peanut oil and vitamin E had no obvious effect on the structure of kidney (Fig. 1b and e).

Effect of acetamiprid on hematological biochemical indicators of kidney: Compared to the controls, acetamiprid increased the activity of urea and Creatinine (Cr) by 111.11 and 25.28%, respectively and decreased the activity of Uric Acid (UA) by 33.02% ($p < 0.05$ for all). Vitamin E weakened the effect of acetamiprid, the concentrations of urea and Cr were lower in the acetamiprid group that received vitamin E than in the acetamiprid only group which were decreased by 38.76 and 11.47%, respectively. Vitamin E increased the concentration of UA by 29.57%. Compared to the controls, peanut oil and vitamin E had no effect on the activity of urea, UA and Cr ($p > 0.05$ for all; Table 1).

Effect of acetamiprid on ion concentrations in the blood: Compared to the controls, acetamiprid increased the concentration of Phosphor (P) and decreased the concentration of Calcium (Ca) ($p < 0.05$ for both). Vitamin E ameliorated the effect of acetamiprid, the concentration of P were lower in the acetamiprid group that received vitamin E than in the acetamiprid only group and the concentration of Ca was increased in comparison to the acetamiprid only group ($p > 0.05$ for both). Peanut oil and vitamin E had no effect on the concentrations of P and Ca ($p > 0.05$ for both; Fig. 2).

Acetamiprid residue in the kidneys: Acetamiprid could not be detected in the kidney of the control, blank and vitamin E groups. Compared to the controls, the amount of acetamiprid residue in the kidney was increased in the acetamiprid only group which was 112.48 ng g⁻¹ ($p < 0.05$). Vitamin E reduced the concentration of acetamiprid residue in comparison to the acetamiprid only group which was decreased by 48.02% ($p < 0.05$; Fig. 3). The concentration of acetamiprid residue was indicated by grey area while the blank area showed no residue, the expected retention time was at 3.30 min, the relative intensity was compared to the kidney of chicken (Fig. 4). In this study, acetamiprid significantly increased the activity of urea, Cr and the concentration of P and

decreased the concentrations of UA and Ca. Acetamiprid damaged the structures of renal corpuscles and tubules, seriously affected renal function. In addition, the concentration of acetamiprid residue in kidneys was lower than that in livers which inferred that kidney might be affected through the indirect action of acetamiprid metabolites. Furthermore, the antioxidant, vitamin E, ameliorated the deleterious effects of acetamiprid on kidney which indicated that acetamiprid might damage the kidney through the oxidative stress of metabolites and vitamin E could reduce the nephrotoxicity of acetamiprid. Acetamiprid mainly affect the nervous system of insects through the excessive activation of

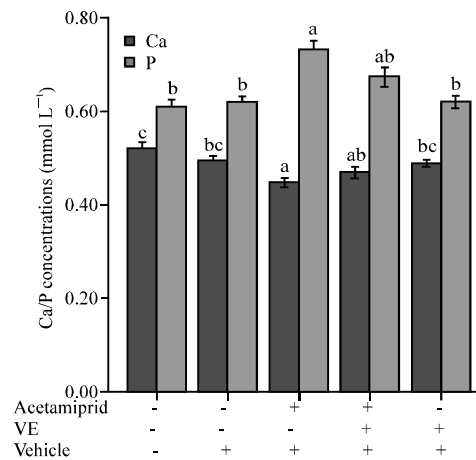


Fig. 2: Effect of acetamiprid on the concentrations of phosphor and calcium in the blood (n = 10/group). Columns with different letters were significantly different among the different groups ($p < 0.05$)

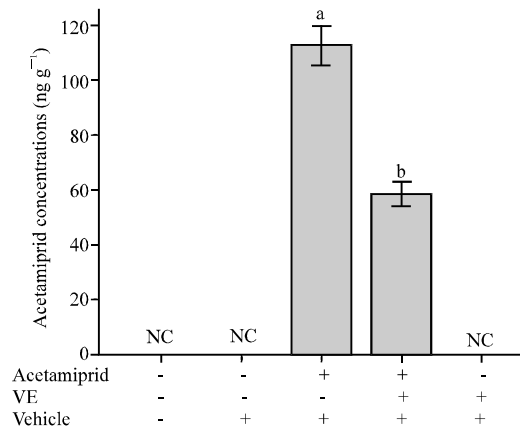


Fig. 3: Acetamiprid residue in mice kidneys (n = 10/group). Columns with different letters were significantly different among different groups ($p < 0.05$)

Table 1: Effect of acetamiprid on hematological biochemical indicators of kidney (\pm SEM) in mice (n = 10/group)

Treatment groups	Urea mmol L ⁻¹	UA μ mol L ⁻¹	Cr μ mol L ⁻¹
Control	1.06 \pm 0.11 ^c	135.30 \pm 5.42 ^b	7.48 \pm 0.59 ^b
Blank (peanut oil)	1.20 \pm 0.20 ^{bc}	139.24 \pm 3.13 ^b	8.06 \pm 0.56 ^b
Acetamiprid	2.14 \pm 0.33 ^a	91.72 \pm 2.54 ^a	9.46 \pm 0.65 ^a
Acetamiprid + Vitamin E	1.46 \pm 0.32 ^b	116.12 \pm 6.01 ^{ab}	8.50 \pm 0.57 ^{ab}
Vitamin E	1.16 \pm 0.24 ^{bc}	122.66 \pm 4.88 ^b	7.74 \pm 0.59 ^b

Within a column, different letter represents significant difference ($p < 0.05$)

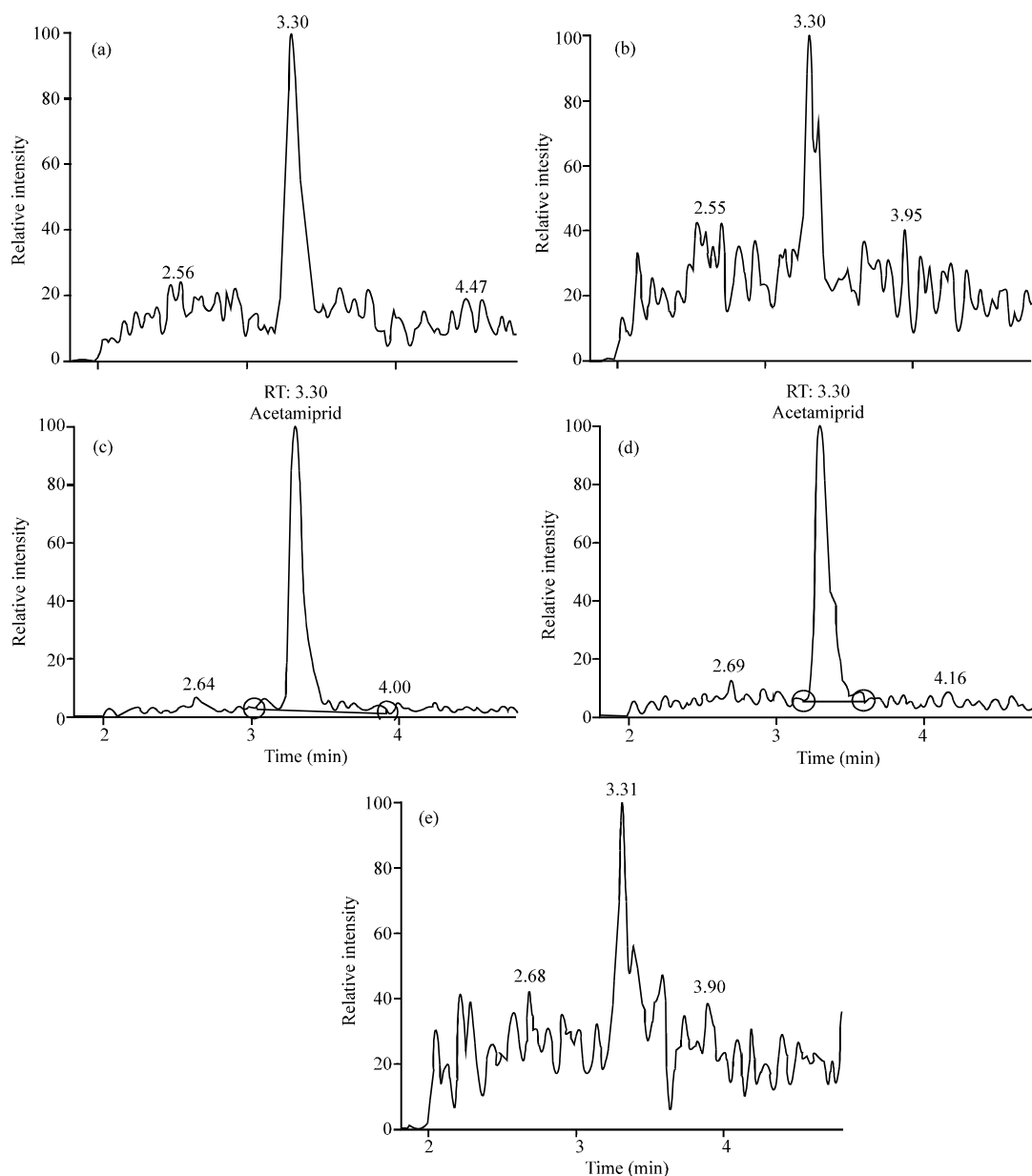


Fig. 4: Chromatograms of acetamiprid residue in kidneys by LC-MS/MS. Abscissa shows retention time, ordinate shows relative intensity. Grey area shows acetamiprid residue in the kidney, blank area shows no residue

acetylcholine receptor (Tan *et al.*, 2007). In addition to neurotoxicity, plasma cholesterol was significantly reduced and liver toxicity and gastrointestinal irritation has been shown in mice and mammals, respectively (Green *et al.*, 2005a, b; Shadnia and Moghaddam, 2008). The previous experiment showed that acetamiprid damaged male reproductive function through inducing oxidative stress in the testes of mouse (Zhang *et al.*, 2011). To the knowledge, there is a paucity of reports with regards to whether acetamiprid affects on kidney. This

novel study found that acetamiprid damaged the structure of kidney and affected the biochemical indicators of kidney which indicated that acetamiprid did affect the renal function.

Urea and Cr are the indicators of renal function (Yang *et al.*, 2011). Urea synthesis in the liver is the major final product of nitrogenous compounds metabolism in mammals. Creatinine forms from creatine phosphate in muscle through a spontaneous and irreversible way. Once renal function was impaired, the normal excretion of urea

and creatinine were hampered by increasing the levels of urea and creatinine in serum. In addition, Calcium and Phosphorus are also indicators of renal function (Raposo *et al.*, 2012). Some studies have shown that the impairment of kidney can reduce the active Vitamin D [$1, 25 (\text{OH})_2\text{D}_3$], inhibit the activity of 1α -hydroxylase and the secretion of parathormone (Perwad and Portale, 2011; Arabi *et al.*, 2012; Zhu *et al.*, 2012) resulting in the concentration of serum calcium decreased and phosphorus increased. This study found that acetamiprid increased the concentrations of urea, Cr and P while the concentration of Ca was decreased which inferred that acetamiprid could damage the renal function.

Uric acid can not only play a preventive anti-oxidation function through combination with iron and copper ions but also remove singlet oxygen and hydroxyl radicals directly. Recent studies have found that Uric Acid (UA) was the highest content of antioxidants in the body and the content of UA in serum is an important parameter which represents the anti-oxidation capacity in body (Pasalic *et al.*, 2012). This study found that acetamiprid decreased the activity of UA. Reduction of the levels of uric acid could lead to the relative increase of ROS which would inevitably lead to an increase in the amount of NO synthesis (Robinson *et al.*, 2011). NO was involved in regulating renal hemodynamics and inhibition of NO enabled the glomerular afferent arteriolar constrict, Renal Plasma Flow (RPF) and Glomerular Filtration Rate (GFR) decline (Tomizawa and Cassida, 2005). Some studies found that NO could directly affect on vascular smooth muscle to reduce vascular tone and inhibit Tubuloglomerular Feedback (TGF) (Dzurik and Spustova, 2001). Acetamiprid injected *in vivo* could form eight metabolites which were regarded as agonists of nicotine and induced Nitric Oxide Synthase (iNOS) in mice (Ford and Casida, 2006). In this study, acetamiprid also damaged the structure of renal corpuscles and tubules consistent with the previous results which inferred that NO could be involved in acetamiprid-induced impairment of kidney in mice. The fact that vitamin E weakened the deleterious effects of acetamiprid on kidney provided new evidence that acetamiprid might damage kidney by inducing ROS.

In order to provide evidence on whether the effects of acetamiprid on renal function are direct or indirect, researchers assessed the acetamiprid residue in the kidney. The results showed that the concentration of acetamiprid in kidneys was lower than that in livers and the previous experiment has found that acetamiprid increased the levels of AST, ALT and ALP (Zhang *et al.*, 2011) which gave further evidence that the detrimental effects of acetamiprid on the kidney were mediated by its metabolites.

CONCLUSION

In this study, acetamiprid has deleterious effects on kidney, potentially through the oxidative stress of its metabolites and vitamin E could reduce the nephrotoxicity of acetamiprid. Thus, acetamiprid should be used in a restricted and careful manner to protect mammalian renal capabilities.

ACKNOWLEDGEMENTS

Researchers thank Miss Kai-Ge Ma, Mr Wen-Hao Li and Miss Meng-Xue Li for their kind assistance with the experiment. This study was supported by grants from the Natural Science Foundation Project of CQ CSTC, 2010BB1138 and the Graduate Science and Technology Innovation Fund of Southwest University (ky2011005).

REFERENCES

- Arabi, A., R. Baddoura, R. El-Rassi and G. Fuleihan, 2012. PTH level but not $25(\text{OH})$ vitamin D level predicts bone loss rates in the elderly. *Osteoporosis Int.*, 23: 971-980.
- Chen, L.M., H.S. Liu, N. Chen and S.M. Du, 2007. The determination of acetam iprid residues om serum by gas chromatography. *Chin. J. Ind. Hyg. Occup. Dis.*, 25: 191-192.
- Dzurik, R. and V. Spustova, 2001. Nitric oxide and the kidneys. *Vnitr lek*, 47: 101-105.
- Ford, K.A. and J.E. Casida, 2006. Unique and common metabolites of thiamethoxam, clothianidin and dinotefuran in mice. *Chem. Res. Toxicol.*, 19: 1549-1556.
- Green, T., A. Toghil, R. Lee, F. Waechter and E. Weber *et al.*, 2005a. Thiamethoxam induced mouse liver tumors and their relevance to humans. Part 2: Species differences in response. *Toxicol. Sci.*, 86: 48-55.
- Green, T., A. Toghil, R. Lee, F. Waechter, E. Weber and J. Noakes, 2005b. Thiamethoxam induced mouse liver tumors and their relevance to humans. Part 1: Mode of action studies in the mouse. *Toxicol. Sci.*, 86: 36-47.
- Manna, S., D. Bhattacharyya, T.K. Mandal and S. Das, 2004. Repeated dose toxicity of alfa-cypermethrin in rats. *J. Vet. Sci.*, 5: 241-245.
- Pasalic, D., N. Marinkovic and L. Feher-Turkovic, 2012. Uric acid as one of the important factors in multifactorial disorders-facts and controversies. *Biochem. Med.*, 22: 63-75.
- Perwad, F. and A.A. Portale, 2011. Vitamin D metabolism in the kidney: Regulation by phosphorus and fibroblast growth factor 23. *Mol. Cell. Endocrinol.*, 347: 17-24.

- Raposo, J.F., A. Pires, H. Yokota and H.G. Ferreira, 2012. A methematical model of calcium and phosphorus metabolism in two forms of hyperparathyroidism. *Endocrine*, 41: 309-319.
- Robinson, M.A., J.E. Baumgardner and C.M. Otto, 2011. Oxygen-dependent regulation of nitric oxide production by inducible nitric oxide synthase. *Free Radic. Boil. Med.*, 51: 1952-1965.
- Shadnia, S. and H.H. Moghaddam, 2008. Fatal intoxication with imidacloprid insecticide. *Am. J. Emerg. Med.*, 26: 631-634.
- Shengyun, S., L. Xiaoming, W. Renfeng and W. Yong, 2005. Efficacy of several insecticides on the control of *myzus persicae* and *lipaphis erysimi*. *Pestic. Sci. Adminastration*, 26: 12-12.
- Tan, J., J.J. Galligan and R.M. Hollingworth, 2007. Agonist actions of neonicotinoids on nicotinic acetylcholine receptors expressed by cockroach neurons. *Neurotoxicology*, 28: 829-842.
- Tomizawa, M. and J.E. Cassida, 2005. Neonicotinoid insecticide toxicology: Mechanisms of selective action. *Ann. Rev. Pharmacol. Toxi.*, 45: 247-268.
- Wang, X.Z., S.S. Liu, Y. Sun, J.Y. Wu, Y.L. Zhou and J.H. Zhang, 2009. Beta-cypermethrin impairs reproductive function in male mice by inducing oxidative stress. *Theriogenology*, 72: 599-611.
- Yang, F., L. Zhuo, S. Ananda, T. Sun, S. Li and L. Liu, 2011. Role of reactive oxygen species in triprolode-induced apoptosis of renal tubular cells and renal injury in rats. *J Huazhong univ. Sci. Technol.*, 31: 335-341.
- Zhang, J., Y. Wang, H.Y. Xiang, M.X. LI and W.H. LI, *et al.* 2011. Oxidative stress: Role in acetamiprid-induced impairment of the male mice reproductive system. *Agric. Sci. Chin.*, 10: 786-796.
- Zhu, Y., R. Zhou, R. Yang, Z. Zhang and Y. Bai *et al.*, 2012. Abnormal neurogenesis in the dentate gyrus of adult mice lacking 1,25-dihydroxy vitamin D(3)(1,25-(OH)(2)D(3)). *Hippocampus*, 22: 421-433.