

## A Case of Patent Ductus Arteriosus and Arthrogryposis in a Buffalo Calf

Saeed Ozmaie and Ahmad Asghari

Department of Clinical Science, Faculty of Veterinary University,  
Science and Research Branch, Islamic Azad University, Tehran, Iran

**Abstract:** Congenital anomalies are abnormalities of structure or function present at birth and account for a high percentage of calf mortality from just before to just after calving. The etiology of these defects was either genetic (recessive gene) or environmental which included nutritional deficiencies, endocrine disturbances, extremes of temperature during pregnancy, radiation, drugs, chemicals, toxic plants and infectious diseases. This report describes a case of patent ductus arteriosus and arthrogryposis in a 7 days old female buffalo calf. The main clinical signs consisted of exercise intolerance, dyspnea and tachycardia. The calf survived only for 48 h. Necropsy revealed a patent ductus arteriosus, measuring 1.3 cm in length and 0.6 cm in caliber was patent and the heart was enlarged and had a globous shape. In this case, a cause of death could not be determined. Any animal with a patent ductus arteriosus has the potential to develop heart failure but it may take months or years to become clinically significant. Without histological findings, a diagnosis of heart failure can not be made with certainty. Since the above conditions were inherited, the best control is by genetic planning, i.e., to avoid animals that carry these genes from breeding programs and by purchasing bulls/semen from reputable breeders produced by parents who did not carry undesirable genes.

**Key words:** PDA, arthrogryposis, calf, histological findings, diagnosis

---

### INTRODUCTION

**History and clinical observations:** A 7 days old female buffalo calf was submitted to the clinic with exercise intolerance, dyspnea and tachycardia. On admission, the calf's temperature was 40.7°C, pulse 106, respiratory rate 98 and mucous membranes were light cyanotic and moist. Clinical examination revealed that the joints of all the four limbs lacked normal angulation. The deformity was more marked in hind limbs. A continuous machinery murmur, grade V/VI and the intensity of the murmur increases with the onset of the second heart sound loudest over the left hemithorax near the cardiac base was auscultated and a strong thrill was palpated over the same area. About 2 days after submission the calf died (Roberts, 1971). During the operation, a PDA with a diameter of 0.6 and 1.3 cm in length was found, adjoining the descending aorta and the pulmonary artery. Bilateral calf Doppler ultrasound scans reveals high velocity jet in the pulmonary artery arising distally, from the descending aorta, suggesting a Patent Ductus Arteriosus (PDA) (Fig. 1) and a chest X-rays showed an enlarged heart (Fig. 2).

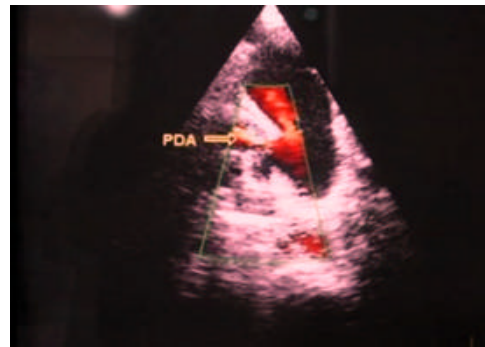


Fig. 1: Patent ductus arerious on colour doppler imaging




Fig. 2: The X-ray chest showed an enlarged heart

## RESULTS AND DISCUSSION

The frequency of congenital defects ranges from <1 to >3% within herds. Time and space are very important at molecular, cellular and tissue levels during development. At a molecular level, the times at which certain genes of individual cells are expressed are important in the production of the correct cell mass and cell products necessary for organ formation (Rousseaux and Wenger, 1985). Arthrogryposis is a congenital defect described as an extreme form of contracted tendons in which many joints are flexed or extended and is considered to be secondary to a primary neuromuscular malformation and was reported to occur in horses, cattle, sheep and pigs (Latshaw and Latshaw, 1987). The condition may involve two, three or all four limbs (Agerholm *et al.*, 2001).

Indicated genetic etiology for arthrogryposis, as the cases occurred following breeding especially between genetically related individuals. Viruses like akabane virus in cows (Kurogi *et al.*, 1977), cache valley virus in lambs (De la Concha-Bermejillo, 2003) and aino virus in neonatal calves (Tsuda *et al.*, 2004) were also attributed to be the cause of arthrogryposis.

Patent (or persistent) ductus arteriosus is a congenital defect whereby the normal fetal vascular channel between the pulmonary artery and the aorta fails to close. In utero, approximately 2/3 of fetal blood bypasses the pulmonary artery and is shunted by the ductus arteriosus directly to the aorta (Bank, 1977). In late gestation, the ductus arteriosus narrow sand with expansion of the lungs at the first breath postparturition, pulmonary resistance falls and systemic arterial pressure rises resulting in the reversal of blood flow within the duct until the duct begins to close (Reef, 2002). Although, the mechanisms are not yet completely understood initial closure of the duct is believed to be due to the reflex contraction of the muscular layer of the vessel, resulting in a stoppage of blood flow across the duct (functional closure). Gradually, the ductus arteriosus is replaced by a fibrous band called the ligamentum arteriosum (anatomic closure) (Ogilvie, 1998).

## CONCLUSION

The present report describes a case of PDA and arthrogryposis in a newborn calf. However, the etiology of the current case was not clearly demonstrated and it is considered that various genetic and environmental factors

might be related to the congenital anomalies in this calf. Since the above conditions were inherited, the best control is by genetic planning, i.e., to avoid animals that carry these genes from breeding programmes and by purchasing bulls/semen from reputable breeders produced by parents who did not carry undesirable genes (Glazier *et al.*, 1974).

## REFERENCES

- Agerholm, J.S., C. Bendixen, O. Andersen and J. Arnbjerg, 2001. Complex vertebral malformation in holstein calves. *J. Vet. Diagn. Invest.*, 13: 283-289.
- Bank, H., 1977. Congenital Malformations of the Heart and Great Vessels: Synopsis of Pathology, Embryology and Natural History. In: *Heart Disease: A Text Book of Cardiovascular Medicine*, Eugene, M.D.B. (Ed.). WB Saunders, Philadelphia, USA., pp: 151-155.
- De la Concha-Bermejillo, A., 2003. Cache valley virus is a cause of fetal malformation and pregnancy loss in sheep. *Small Ruminant Res.*, 49: 1-9.
- Glazier, D.B., B.T. Farrelly and J.F. Neylon, 1974. Patent ductus arteriosus in an eight-month-old foal. *Irish Vet. J.*, 28: 12-13.
- Kurogi, H., Y. Inaba, E. Takahashi, K. Sato and K. Satoda, 1977. Congenital abnormalities in newborn calves after inoculation of pregnant cows with akabane virus. *Infect. Immunity*, 17: 338-343.
- Latshaw, W.K. and J.L.K. Latshaw, 1987. *Veterinary Developmental Anatomy: A Clinically Oriented Approach*. B.C. Decker Publisher, Toronto, Canada, ISBN-13: 9780941158985, pp: 128-134.
- Ogilvie, T.H., 1998. *Large Animal Internal Medicine*. Wley-Blackwell Publishers, Malden, USA., ISBN-13: 9780683180336, pp: 247-248.
- Reef, V.B., 2002. Disease of the Cardiovascular System. In: *Large Animal Internal Medicine*, Smith, B.P. (Ed.). Mosby Inc., St Louis, USA., pp: 450-451.
- Roberts, S.J., 1971. *Veterinary Obstetrics and Genital Diseases*. 2nd Edn., CBS Publication and Distributors, New Delhi, India, pp: 496-506.
- Rousseaux, C.G. and B.S. Wenger, 1985. Are pesticides involved in arthrogryposis?. *Can. Vet. J.*, 26: 257-258.
- Tsuda, T., K. Yoshida, S. Ohashi, T. Yanase and M. Sueyoshi *et al.*, 2004. Arthrogryposis, hydranencephaly and cerebellar hypoplasia syndrome in neonatal calves resulting from intrauterine infection with aino virus. *Vet. Res.*, 35: 531-538.