

Response of *Channa striatus* Extract Against Monosodium Iodoacetate Induced Osteoarthritis in Rats

¹F.J. Al-Saffar, ¹S. Ganabadi and ²S. Fakuraz

¹Department of Preclinical Sciences, Faculty of Veterinary Medicine,
University Putra Malaysia, 43400 Serdang, Selangor, Malaysia

²Department of Human Anatomy, Faculty of Medicine and Health Sciences,
University Putra Malaysia, 43400 Serdang, Selangor, Malaysia

Abstract: The main aim of this study was to evaluate oral administration of *Channa striatus* extract on monosodium iodoacetate induced knee osteoarthritis changes in rat. About 40 rats were randomly assigned to four groups. Rats in the 1st and 2nd groups were treated with the extract in a same dose but with two different courses of therapy. Rats in the 3rd group were treated with celecoxib as a positive control where as the 4th group was treated with normal saline as a negative control. Evaluation of osteoarthritis changes was assessed with the aid of radiology, histopathology score and immunohistochemistry to explore immunoreactivity in the synovium. Assay of prostaglandins in the serum had been implemented to explore their role in osteoarthritis events and regulation. Gross and microscopic results revealed curative effects of the extract on the osteoarthritis accompanied with improved immunoreactivity of the synovium. Data showed significant hormonal changes in different treated groups, indicating their role in osteoarthritis. In conclusion, the extract showed inhibitory effect on joint degradation and its earlier therapeutic application reflects importance of earlier treatment on the disease progression. Immunoreactivity as well as serum prostaglandins concentrations could be used as good markers to evaluate osteoarthritis events in the affected joints.

Key words: Osteoarthritis, *Channa striatus*, rats, MIA, Haruan, prostaglandins

INTRODUCTION

Osteoarthritis is an age-related joint disease characterized by degradation of the articular cartilage associated with subchondral response and inflammation of the Synovial Membranes (SMs) which is usually associated with chronic pain (Pomonis *et al.*, 2005).

Factors produced by the synovium and chondrocytes, including: growth factors, aggrecanases matrix metalloproteinases and cytokines may predispose in its initiation and development (Moreland, 2003). Neuropeptides (NPs) also contributes to OA changes via their stimulation of synoviocytes to produce PGE₂, collagenase, gelatinase and oxygen free radicals and subsequently, participate in the pathogenesis of chronic inflammatory joint conditions (Inoue *et al.*, 2001). Neuropeptides such as Substance p (Sp), Calcitonin Gene Related Peptide (CGRP), Protein Gene Product (PGP) 9.5 and NPY have been investigated in inflamed joints in human and different animal species and their role and relationship was well stated to this degenerative joint disease (Mapp *et al.*, 1994; Brain and Cox, 2006). Osteoarthritis is a major health burden in human due to large number of people aged beyond 75 years is affected by this joint illness with significant morbidity and

disability (Hinton *et al.*, 2002; Dumond *et al.*, 2004). Non-Steroidal Anti-inflammatory Drugs (NSAIDs) are the most currently used anti-OA but they can cause gastrointestinal complications especially in long-term treatment (Femihough *et al.*, 2004). In veterinary field, OA leads to major economic losses in equine industry (Williams, 2007). It is commonly treated by intraarticular injection of hyaluronic acid but its favorable dose is still unproven yet. In dogs and cats, the most common NSAIDs used are etodolac, carprofen, ketoprofen, meloxicam and tepoxalin (Stephen *et al.*, 2005) but adverse effects rose in their long term use (Bove *et al.*, 2003; Duncan *et al.*, 2007). Therefore, natural products from plants, animals and minerals have been employed as the main sources of drugs to cure and prevent diseases for centuries (Janusz *et al.*, 2002; Pelletier *et al.*, 2005; Carmona *et al.*, 2007; Cahue *et al.*, 2007). Unfavorable side effects of the available interventions may be ameliorated by the use of animal extracts alternatives and *Channa striatus* (common name, Haruan) extract is one such candidate. *Channa Striatus* (CS) is a snakehead fish, widely consumed throughout the Asia Pacific region as a rich source of protein and for its alleged effect to heal injuries and ease post operative pain (Mat jais *et al.*, 1994). The extract has potent anti-inflammatory

and analgesic properties (Somchit *et al.*, 2004; Zakaria *et al.*, 2004) and this explains their use for centuries, aiming to reduce pain, inflammation and enhance wound healing (Zuraini *et al.*, 2006). This investigation was conducted to explore CS extract inhibitory effect on OA changes and progression in an induced knee OA in rats and the morphological, innervations and PGs changes associated with it.

MATERIALS AND METHODS

Preparation of animals: About 40, adult male Sprague Dawley rats, weighing between 275-400 g were used in this research. The rats were housed in a well air-conditioned animal room at 22°C (one rat per cage). The rats were given commercial pellet and tap water *ad libitum* and were left for 2 weeks for acclimation before used. This investigation was implemented according to the guideline for animal handling and care and approved by Animal Care and Use Committee (ACUC), Ref., UPM FPV/PS/3.2.1.551/ AUP-R44, Faculty of Veterinary Medicine, University Putra Malaysia.

Induction of OA and radiography: Rats of all groups were injected intra-articularly with 50 µL of MIA (Sigma, USA) diluted in saline at a 60 mg mL⁻¹ at day 0. Prior to inducing OA, all rats were anesthetized with intramuscular injection of a mixture of ketamine (50 mg mL⁻¹) and xylazine (20 mg mL⁻¹) at a ratio of 2:1, 1 mL kg⁻¹ body weight. (Hattori *et al.*, 2005). The injection of MIA was performed once through the patellar ligament using a 27 gauge, 0.5 inch needle (Bove *et al.*, 2003). Some rats were selected randomly for radiography of their knee joints under anesthesia to rule out any joint disease or changes at three different periods, i.e., before OA induction, post OA and post 4 weeks of treatment. Radiographies were implemented on the joints at both craniocaudal and mediolateral positions to monitor joint space impairment, misalignment and bones morphological changes (Arden and Nevitt, 2006).

Preparation of CS extract and protocol of treatments: The extract was prepared from the fish fillet according to the method described by Jais *et al.* (1997). Treatments started for all groups on day 16 post OA induction, except group HII which received an early treatment at day 2 post-induction. Treatments were given orally everyday for 4 weeks using feeding catheter as described:

- In Group HI, 10 mL kg⁻¹ of 20% CS extract diluted in normal saline (Jais *et al.*, 1997)
- In Group HII, 10 mL kg⁻¹ of 20% CS extract diluted in normal saline (day 2 post OA induction)

- In Group CEL, 30 mg kg⁻¹ celecoxib (Celebrex®), diluted in 5% carboxyl-methyl cellulose were given orally and served as positive control (Pomonis *et al.*, 2005)
- Group NS were treated with normal saline at a dosage of 10 mL kg⁻¹ body weight and served as negative control

Gross and microscopic evaluation of joints: Upon euthanasia with intraperitoneal injection of 500 mg kg⁻¹ sodium phenobarbital, joints were dissected and their femoral condyles and tibial plateau were examined for gross pathological changes and photographed using image stereo microscope analyzer (WD 54 Nikon, Japan). After that, they were fixed and processed using standard histological procedure. Serial sections of 6 µm thickness was prepared and stained with hematoxylin and eosin (H and E) for general morphology or with Safranin O fast green stain which is specific for matrix proteoglycan staining. Changes of articular cartilages and subchondral bones were scored according to the method by Kobayashi *et al.* (2003). Samples of SM were also stained with H and E and changes were scored according to the method by Kikuchi *et al.* (1998). Evaluation of OA changes had been implemented blindly by 2 of the team using image analyzer microscope (Olympus, BX 51) (Table 1).

Synovial membranes preparation: For Immunohisto Chemistry (IHC) study synovial membrane was fixed in Zamboni fluid for 6 h, subsequently washed in 0.1 M Phosphate Buffer Saline (PBS) (pH 7.4) then immersed in 15% sucrose for 2 days at 4°C. Then, they were snap frozen in isopentene cooled with liquid nitrogen and sectioned at 8 µm in a cryostat (Saxler *et al.*, 2007). The sections were incubated in the primary antisera: anti-PGP 9.5 (Ultraclone Cambridge Ltd. UK), anti-CGRP (Cambridge Research Biochemical, UK) and anti-NPY (Peninsula Laboratories, UK) for 24 h at 4°C. Sections were washed in PBS and then incubated for 1 h in the secondary antiserum (Gt XRB IgG Cy3) at room temperature (dilution 1:400). Sections were washed in PBS and then cover-slipped in fluorescence mounting medium. Densities of nerve fibers were expressed as nerve fibers 4 mm⁻².

Assay of prostaglandins: Blood was collected from all rats to estimate PGs concentrations at three different periods. Enzyme immunoassay kits for PGE₂ and PGF_{2α} detection (Assay design purchased from USA, Catalog # 900-001 and Catalog # 900-069, respectively) were used to perform hormones assay.

Table 1: Histopathology score of the articular surfaces, subchondral bones and synovial membranes of the rat's right knees in HI, HII, CEL and NS groups

Joint parts	Pathology scores of observations (means) per each group (N = 10)	Rat's groups			
		HI	HII	CEL	NS
Femur	Loss of tangential zone chondrocytes	1.5	1.0	1.4	3.0
	Loss of chondrocytes in transitional and radial zones	1.7	0.4	2.0	2.2
	Chondrocytes disorganization	1.3	0.4	1.2	2.3
	Cloning and hypertrophy	1.7	1.5	0.5	0.3
	Degeneration and or necrosis	1.5	1.0	3.0	2.6
	Surface irregularity and fibrillation	0.5	0.7	1.0	1.0
	Safranin O stain reduction	1.6	1.2	2.2	2.6
	Subchondral fibrosis and cyst formation	0.5	0.2	2.3	2.1
	Osteophyte formation	0.4	0.2	0.6	1.6
	Total averages score of femur±SEM	10.7±0.2	6.6±0.2	14.2±0.3	7.7±0.3
Tibia	Loss of tangential zone chondrocytes	1.5	1.0	1.9	3.0
	Loss of chondrocytes in transitional and radial zones	1.3	0.4	2.0	2.6
	Chondrocytes disorganization	1.0	0.4	2.5	2.8
	Cloning and hypertrophy	1.0	1.0	0.2	0.4
	Degeneration and or necrosis	1.8	1.2	2.7	2.8
	Surface irregularity and fibrillation	0.5	0.7	1.2	0.8
	Safranin O stain reduction	1.5	1.1	2.1	2.6
	Subchondral fibrosis and cyst formation	0.2	0.0	0.0	1.0
	Osteophyte formation	0.1	0.1	0.3	0.7
	Total averages score of tibia±SEM	8.9±0.2	5.9±0.3	12.9±0.3	16.7±0.4
Synovial membrane	Hyperplasia of intimal layer	1.8	0.3	1.5	1.5
	Hypertrophy of intimal layer	0.3	0.0	2.2	2.4
	Inflammatory cells infiltration in intimal layer	0.2	0.0	2.2	2.4
	Hypergranulation of subintimal layer	1.8	0.3	2.4	2.4
	Hypervascularization of subintimal layer	1.8	0.3	2.4	2.4
	Inflammatory cells infiltration in subintimal layer	0.3	0.0	2.5	2.5
	Total averages score of synovial membranes±SEM	6.2±0.3	0.9±0.06	13.2±0.1	13.6±0.2
	Sum of femoral, tibial and synovial membranes scores±SEM	25.8±0.2	13.4±0.1	40.3±0.2	48±0.2

Mean of the pathology score is measured for each observation observed in 10 rats of each group. Data analyzed with Kruskal-Wallis and confirmed with Mann-Whitney U test; significantly ($p < 0.01$) lower than those of NS group; **Insignificantly ($p > 0.05$) lower than those of NS group; †significantly ($p < 0.01$) lower than those of HI group

Statistical analysis: Statistical calculations were carried out with the SPSS 15.0 for Windows software package. Data was expressed as mean±SEM and analyzed with Kruskal-Wallis for histopathological score (as non parametric data) confirmed with Mann-Whitney U-test and one way ANOVA for neuropeptides densities and hormone concentrations in serum (as parametric data) confirmed with student test.

RESULTS

Gross observations: Right knee joints showed apparent swelling immediately after MIA injection but subsided gradually. However in the NS group, the diameter remains larger compared to the normal left joints. Joints were dissected and after skin removal, left joint's capsule appeared white and glistening whereas the right joints were faintly yellowish in both HI and HII groups, slightly thickened in the CEL group but greatly thickened in those of NS group. Femoral condyles and tibia plateau of the left joints exposed smooth and glistening articular cartilage surfaces whereas right knees of the HI group revealed minute necrotic spots at the trochlear ridges, femoral condyles and tibial plateaus. Gross observations in HII group were substantially alleviated. It revealed, mild cartilage abrasions at femoral condyle and tibial plateau. Knees of CEL group revealed mild osteophyte at trochlear

ridge, necrosis at trochlea and condyles of femur. Findings in NS group include osteophyte formation at the femoral trochlea and extensive necrosis at the articular cartilages of the trochlea and condyles of femur and in tibial plateau.

Radiography: Radiographs on day 0 prior to OA induction showed normal synovial mass, clear microfilm of synovial fluid and normal sub-patellar opacity; readily distinguish from the adjacent structures (Fig. 1A, B). Post OA induction, the right knees of randomly selected rats from HI, CEL and NS groups revealed OA changes such as decreased joint space, roughened articular surfaces and less remarkable sub-patellar opacity from the adjacent structures (Fig. 1C, D) whereas the 2nd group (HII) showed swelling of the surrounding structures without distinct sub-patellar opacity at post one day of OA induction (Fig. 1E). Radiographs post treatment period did not revealed progressed changes in the right joints of both HI and HII groups (Fig. 1F, G) while those of CEL group showed distinct synovial space impairment, rough and irregular articular surfaces and less distinct subpatellar opacity than the surrounding structures (Fig. 1H, II). Advanced changes occurred at joints of NS group, and some rats were showed femoral and tibial dystrophic changes with joint misalignment (Fig. 1J-L).

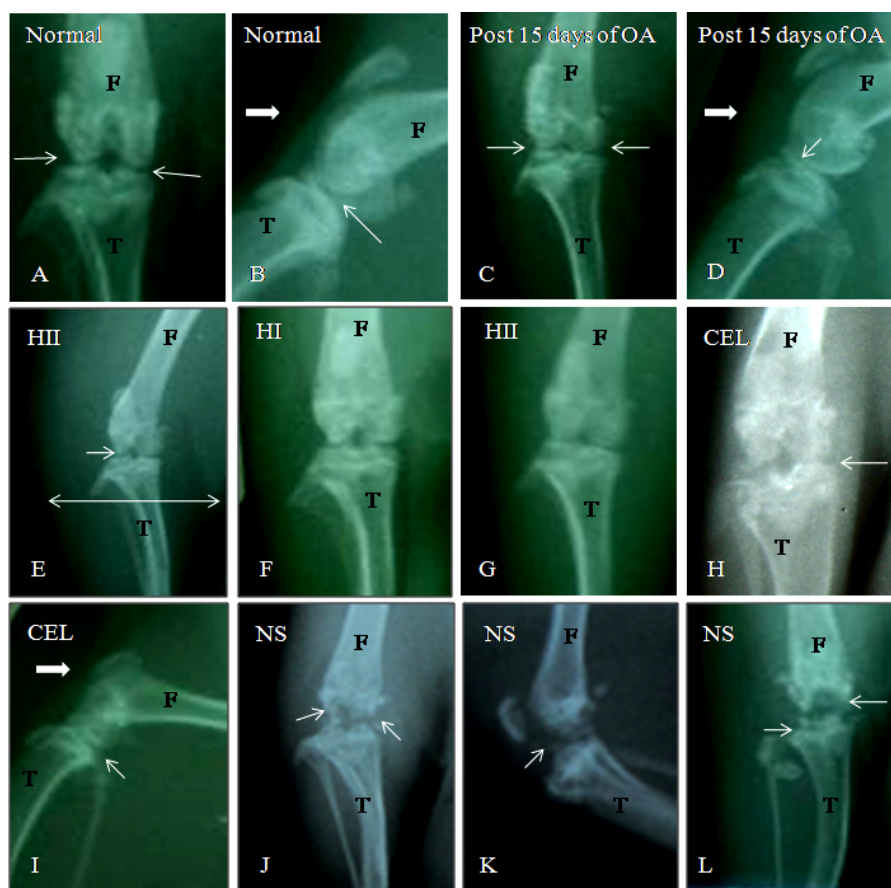


Fig. 1: Radiographs showing changes in Femoral (F) and tibial (T) parts of the knees. (A, B): Normal knees showed clear radiolucent joint space (arrows) and distinct sub-patellar opacity (thick arrow). (C, D): Knees post 15 days of OA showed decreased joint space, roughened articular surfaces (arrows) and less distinct sub-patellar opacity (thick arrow). (E): HII group post 2 days of OA showed swelling of the joint (doubled head arrow) with still prominent joint space (arrow). Post euthanasia, right knees of HI and HII revealed no progressed changes in femoral and tibial parts with somewhat clear joint space (F, G) whereas, changes progressed severely in CEL and NS groups: complete loss of joint space with distinct dystrophic changes (thin arrows), rough articular surfaces and indistinct subpatellar opacity (thick arrow) (H-L)

Microscopic observations: Articular cartilages and synovial membranes from the non-induced joints showed their normal structures. Microscopic changes found in the right knee joints and their SMs had been well described and scored (Table 1). Severe pathological changes observed at the NS group. Tangential zone of articular cartilages revealed severe loss of chondrocytes with slight surface irregularity and fibrillation. Chondrocytes depletion at the transitional and radial zones was quite severe with obvious cellular disorganization. Most of the remaining chondrocytes were underwent necrosis (Fig. 2A, B). Matrix break down was evident and well detected by the severe reduction in Safranin O fast green stain (Fig. 2C, D). Marked subchondral lesions detected, characterized with extensive replacement of bone marrow elements with fibrous tissue (Fig. 2E). Some joints

revealed cyst formation (Fig. 2C) whereas, several joints from this group exposed osteophytes (Fig. 2F, G). Synovial membranes exposed hyperplasia and for a lesser extent hypertrophy. Hypergranulation and hyper-vascularization of the subintimal layer accompanied with of infiltration of macrophage and lymphocytes (Fig. 2H, I). Celecoxib treated group exposed moderate to severe pathological changes (Fig. 3A, B). Apparent reduction in the Safranin O fast green stain observed in those articular cartilages suffered severe necrosis (Fig. 3C, D). Subchondral bone structures revealed replacement of bone marrows with fibrous tissue and cyst formation at femoral condyles in some rat's joints (Fig. 3E). More frequently osteophytes detected at femoral condyle than in the tibial plateau (Fig. 3F, G). Synovial membranes showed hyperplasia of the synovial lining with sign of

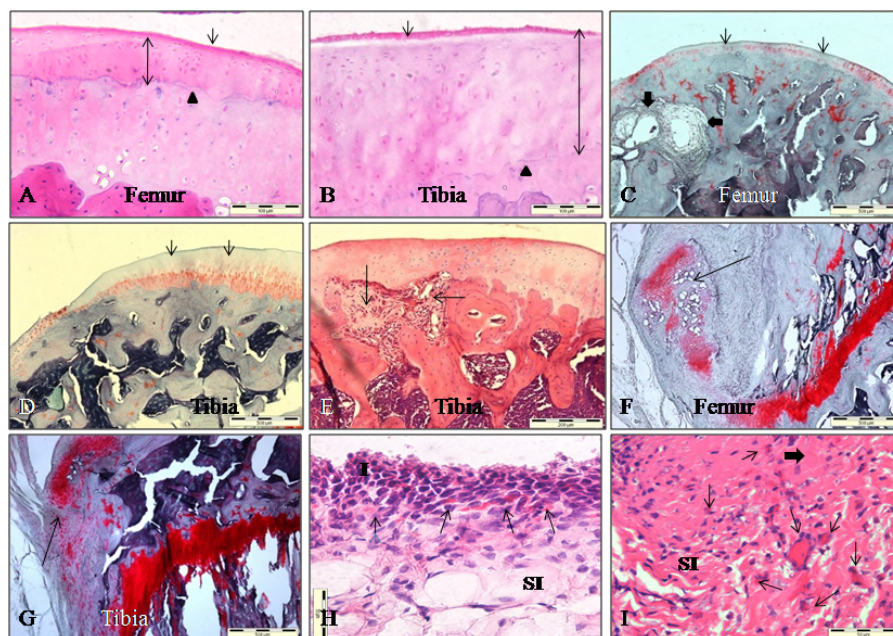


Fig. 2: Normal saline group. (A, B): Fibrillation and severe cellular in the tangential zone (arrow). Severe cellular loss and necrosis in transitional-radial zones (doubled head arrow) till the tidemark (triangle), H and E, x200. (C): Severe reduction in the Safranin stain at the femoral articular surface (thin arrows) with subchondral fibrosis and cyst formation (thick arrows), x40. (D): Severe reductions of Safranin stain at tibial articular cartilage, x40. (E): Subchondral fibrosis at the tibial plateau (arrows), H and E, x100. (F, G): Marginal osteophytes at femoral condyle and tibial plateau (arrows), Safranin stain, x40. (H, I): Synovial membranes showed hyperplasia of the intima (I), hypergranulation of subintima (thick arrow), increased number of blood vessels with inflammatory cells infiltration (thin arrows), H and E, x 400

hypertrophy. Hypergranulation and hypervascularization of the underlying subintimal layer with inflammatory cells infiltration at both intimal and subintimal layers with (Fig. 3H, I). Right knees of CS treated groups revealed significantly lower histopathological score in comparison with the NS group. Sections from HI joints stained with either H and E or Safranin O fast green stain revealed the following changes: Mild to moderate cellular loss and disorganization observed in tangential, transitional and radial zones of articular cartilages. Chondrocytes exist in the transitional zone underwent cloning and hypertrophy while those present in radial zone suffered mild to moderate necrosis. Matrices of both femoral condyle and tibial plateau showed mild to moderate reduction in Safranin O fast green stain. Subchondral structures underwent mild replacement of bone marrow elements with fibrous tissue. Few joints from this group showed mild osteophyte and cyst development. Synovial membranes showed moderate hyperplasia of their synovial lining. Underlying subintimal layer showed moderate granulation accompanied with mild inflammatory cells infiltration (Fig. 4A-F). Joints represent HII group outlined significantly lower changes than the other groups. It showed mild loss of chondrocytes and marked cellular cloning in the transitional-radial zones in the

femoral condyles and for a lesser extent at the tibial plateau. Cellular disorganization and necrosis were mild in the femoral condyle and tibial plateau. Safranin O fast green stained sections revealed mild reduction in their staining but some sections showed moderate reduction. Subchondral structures revealed mild bone marrow replacement with fibrous tissue and very mild osteophytes. Changes found in the SMs revealed mild hyperplasia. Underlying subintimal layer revealed very mild proliferation of collagen fibers with mild hypervascularization in the deeper part only without any sign of inflammatory cells infiltration (Fig. 4G-I).

Results of IHC study: Synovial membranes stained with antibodies against the following NPs PGP 9.5, CGRP and NPY from non induced joints revealed positive immunoreactions responses (Fig. 5A-C). Numerous immunoreactive nerve fibers of PGP 9.5 (general neuronal marker) and for a lesser extent CGRP (sensory) and NPY (sympathetic) were visualized around blood vessels or as free nerve fibers in the subintima. In general, the PGP 9.5 innervations in intima were sparse single fibers while it was abundant in the subintimal tissue. These fibers existed in an undulating course or rarely in a straight line and sometimes form an expanded varicose containing

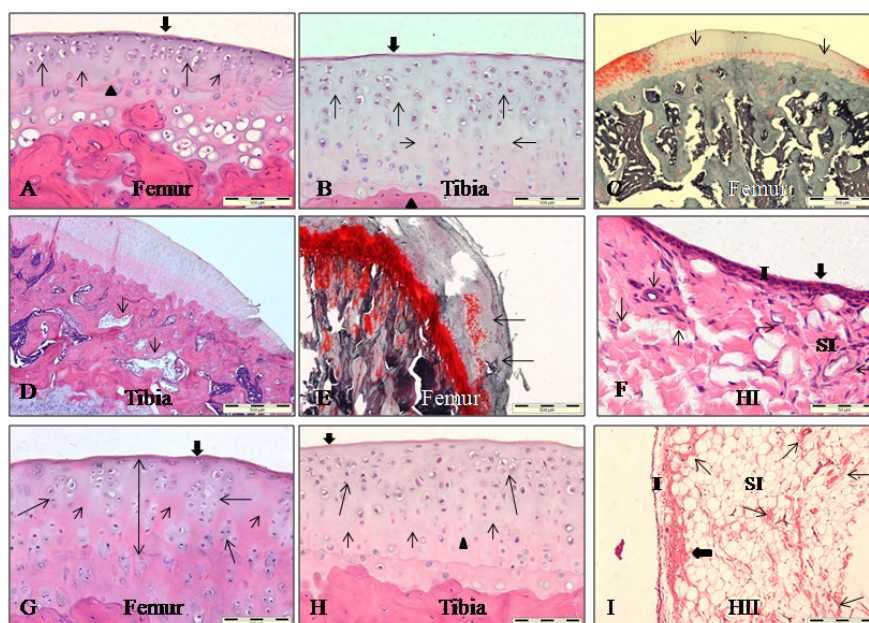


Fig. 3: Articular cartilages and synovial membranes of CEL group. (A, B): Fibrillation and cellular loss in the tangential zone (thick arrow), severe cellular loss in transitional (thin short arrow) and radial zones (thin long arrow), severe chondrocytes necrosis and disorganization, H and E, x200. (C, D): Moderate Safranin reduction in the articular cartilages (arrows), x40. (E): Bone marrow replaced with fibrous tissue and cyst development (long arrow) opposite to the severely affected articular cartilage (short arrow), H and E, x100. (F, G): Marginal osteophytes (arrow), H and E, x40 and Safranin stain, x40, respectively. (H, I): Synovial membranes showed hyperplasia of intima (I), hypergranulation (thick arrows) of subintima (SI), increased number of the blood vessels (thin arrows) with inflammatory cells infiltration, H and E, x200 and x400, respectively

Table 2: Density means of PGP 9.5, CGRP and NPY immunoreactive nerve fibers detected at the synovial membranes of the right knees for the treated groups (HI, HII, CEL and NS) and left normal non induced joint

Groups	PGP 9.5	CGRP	NPY
HI*	14.9±0.76	8.7±0.49	4.30±0.20
HII*¶	22.8±1.37	13.5±0.60	6.70±0.39
CEL†	5.2±0.59	2.9±0.25	1.60±0.26
NS	4.7±0.55	2.7±0.21	1.84±0.16
Normal left #	53.3±2.36	30.9±0.87	13.40±0.54

Density means of the nerve fibers were measured per each 4 mm² of the synovial membrane per each rat per each group. Data analyzed with one way ANOVA and confirmed with student test; *Significantly (p<0.01) different from NS group; †insignificantly (p>0.05) different from NS group; ¶ Significantly (p<0.01) different from HI group; # significantly (p<0.01) different from the other groups

nerve bundles through the normal fibro-fatty structure of the SMs. CGRP labeled nerve fibers were relatively numerous than those of NPY but both densities were distinctly lower in comparison with those of PGP 9.5 fibers. Total densities of PGP 9.5, CGRP and NPY nerve fibers were depleted significantly (p<0.01) in right SMs at both CEL and NS groups while they were improved significantly at orally CS treated groups in comparison with those of the left normal (Fig. 5D-I) (Table 2).

Prostaglandins assay: Results revealed different concentrations of Pgs at different periods and groups.

Table 3: Concentrations of Prostaglandins (PGs) in serum of rats at three different periods and different treated groups: NS (Normal Saline), CEL (Celecoxib), HI and HII (*Chama striatus* extract)

Periods	PGE ₂ pg mL ⁻¹	PGF _{2α} pg mL ⁻¹
First: Before OA induction		
	17359.06±2122.7	26300.38±350.2
Second: 15 days post OA induction		
	29036.92±2707.7*	29753.35±535.6*
Third: 4 weeks post treatment		
NS (negative control) group	34012.02±2451.6	29789.11±346.5
CEL (positive control) group	22845.05±750.4**	27841.36±581.2†
HI group	17823.21±468.5**	28524.153±467.76†
HII group	16666.9±757.7**	28253.135±868.9†

Hormones concentrations means were measured per each rat per each group; Data analyzed with one way ANOVA and confirmed with student test; *significant (p<0.001) elevation of PGE₂ and PGF_{2α} levels in comparison with those before OA induction; **significant (p<0.001) reduction of PGE₂ level in comparison with NS group; † insignificant (p<0.001) reduction of PGF_{2α} level in comparison with NS group

Normal concentration of PGE₂ was elevated significantly (p<0.01) post 15 days of OA induction. The concentration of this hormone inhibited significantly (p>0.01) after the treatment with celecoxib and CS extract but not with normal saline. The basal level of PGF_{2α} was found to be higher than PGE₂. Following OA induction for 15 days the level was found to be elevated compared to the basal level. The level of PGF_{2α} was found more or less similar to the level before the animals being treated. The changes in the level of PGF_{2α} was found to be insignificant (Table 3).

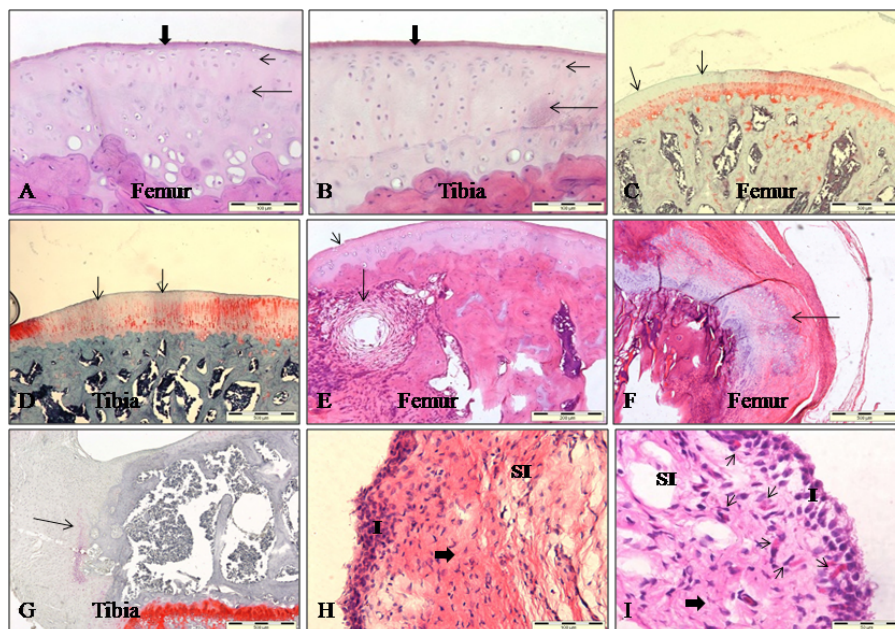


Fig. 4: Upper and middle panels represent HI group. (A, B): Mild cellular loss of tangential zone (thick arrow), chondrocytes cloning at transitional zones (long arrows), areas devoid of cellular components (short arrows) with cellular degeneration at radial zones (triangles), H and E, x200. (C): Moderate Safranin reduction of femoral condyle (arrows), x40. (D): Mild subchondral fibrosis and cyst development in the tibia (arrow), H and E, x40. (E): Osteophyte of femoral condyle (arrows), Safranin stain, x40. (F): Mild hyperplasia of the intima (I) (thick arrow), hypergranulation of subintima (SI) and mild increased in number of blood vessels (thin arrows), H and E, x400. Lower panel: (G-I): represent HII group. (G, H): showed mild cellular loss of the tangential zone (thick arrow), chondrocytes cloning (long arrows) of the transitional-radial zones in femur whereas, tibia showed cloning at transitional zone, necrosis at the radial zone (triangle) and areas devoid cellular components (short arrows), H and E, x200. (I): Synovial membranes showed 1-2 cells thick intima (I), fibro-fatty subintima (SI) with small area of granulation (thick arrow) and considerable number of blood vessels (arrows), H and E, x100

DISCUSSION

This study was conducted to evaluate the possible inhibitory effect of CS extract on OA joint. Selection of MIA was based on its metabolic inhibitory property which is well known to cause rapid onset of OA changes in the knee joints (Guzman *et al.*, 2003). It inhibits glyceraldehyde-3-phosphate dehydrogenase activity and therefore leads to inhibition of the glycolysis and subsequent death of the articular cartilage cells (Cournil *et al.*, 2001). Cellular loss and/or degeneration will lead to OA development because chondrocytes are responsible on the normal balanced mechanism between catabolic and anabolic enzymes (Fernihough *et al.*, 2004). Current investigation outlined that oral administration of CS extract reduced the global pathological score of the articular cartilages and SMs of the OA joints. The reduction of OA changes observed in HII group was significantly higher ($p < 0.01$) than HI group. The reason for this difference may be due to an earlier application of

CS extract in HII group. However, both CS treated groups showed significantly lower pathological scores than those treated with celecoxib or normal saline. There could be 2 possibilities of how *Channa striatus* extract reduces the OA changes:

First: It can enhance the proliferation and adding more collagen fibers into the matrix substance of the articular cartilage. This alleviation may at least decrease and suppress such constituent fibers from being destructed and subsequent matrix degradation. The extract contains high amount of ω -3 polyunsaturated fatty acids which is known to play a role in collagen fibers synthesis and precipitation at the affected regions (Mat jais *et al.*, 1998). It can strengthen the matrix through remodeling of collagen fibers via the synthesis of inter and intramolecular protein cross-linking (Jais *et al.*, 1997) and subsequently can minimize its degradation and subsequent inflammation.

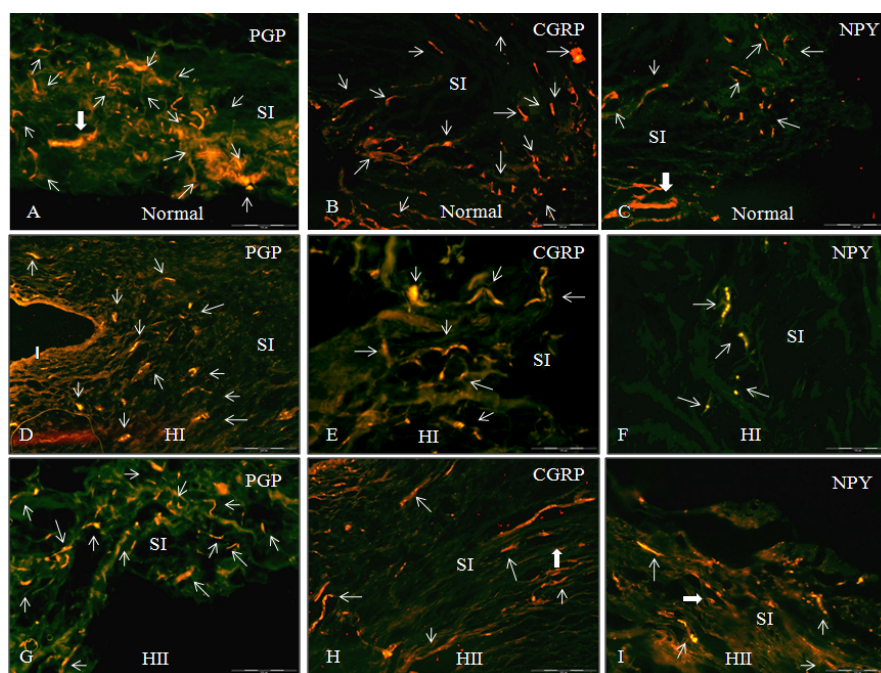


Fig. 5: Synovial membranes cryosections stained with Fluorescein Isothiocyanate (FITC). Upper panel: (A): Normal sections showed numerous PGP 9.5 immunoreactive nerve fibers distributed in subintima (SI) (thin arrows) and some of them expanded forming varicose (thick arrow), x200. (B, C): Normal sections showed numerous CGRP and NPY nerve fibers distributed in subintima (SI) (arrows), x100. Middle panel: (D-F): Cryosections represent HI group. (D): PGP 9.5 nerve fibers distributed all over the SI (thin arrows) x100. (E, F): Sparse numbers of both CGRP and NPY nerve fibers distributed in the SI (thin arrows) and some of them present nearby the blood vessels (thick arrows), x100 and x200, respectively. Lower panel: (G-I): Cryosections represent HII group. (G): PGP 9.5 nerve fibers distributed all over the SI (arrows), x200. (H, I): Small numbers of both CGRP and NPY nerve fibers distributed in the SI (thin arrows) and some of them present nearby the blood vessels (thick arrows), x200

Other property of the extract is its ability to enhance the production of some important substances for matrix healing such as glycosaminoglycans and hyaluronic acid (Baie and Sheikh, 2000). Improvements of matrix condition at CS treated groups were well exposed by the improved staining with Safranin O fast green stain.

Second: Inflammatory events at the osteoarthritis joints are mainly due to the fragmentation of the degrading articular cartilage into the synovium which subsequently triggers the inflammatory process by the production of prostaglandins and pro-inflammatory mediators such as IL-1 and TNF- α which in turn stimulates the generation of oxygen free radical species (Cahue *et al.*, 2007). These oxygen free reactive compounds can cause and enhance chondrocytes degeneration at the articular cartilage. Anti-inflammatory property of CS may inhibit some joint inflammatory events a part from that free radicals generation (Stephen *et al.*, 2005). Assay of serum PGs, revealed significant elevation of PGE₂ concentrations in

NS group while inhibited significantly in CS treated group and for a lesser extent in CEL group. Concentrations of this pro-inflammatory mediator increased at period of OA induction (Table 3) indicating its role in OA development and progression. In the NS group, articular cartilages and SMs revealed poor responses, correlated well with the significant elevation of PGE₂ concentrations at their sera.

In CEL group, the histopathology scores closely resembled to that exposed by NS group and statistical analysis showed no significant difference between their global lesions ($p > 0.05$).

Low outcome of celecoxib may be due to its low capacity to scavenge oxygen free radical so that exposed poor antioxidant activity (Bastos-Pereira *et al.*, 2010). Similarly, application of other NSAID's in other investigations revealed poor effects on the osteoarthritis articular cartilages (Choi *et al.*, 2002).

Current observations were in consistent with previous findings which were postulated that degradation of articular cartilage of the joint will give rise to

subchondral response manifested by fibrosis of the bone marrow elements, bone thickening and cyst formation (Guzman *et al.*, 2003). Both NS and CEL groups suffered severe, widespread necrosis of their articular cartilages accompanied with definite subchondral structural changes. Oppositely, subchondral responses in CS treated groups were mild and moderate in the joints of HII and HI groups, respectively. Findings of IHC exposed significant depletion ($p < 0.01$) of PGP 9.5, CGRP and NPY nerve fibers in both NS and CEL groups which was consistent with previous findings (Mapp *et al.*, 1994) whereas, distinctly improved in those treated with CS extract. The improvement of these immunoreactive nerve fibers was due to the facts mentioned above that CS extracts may discontinue degradation and inflammation in the joint structures including the SM. One such complication may be the stimulation of synoviocytes to produce PGE_2 , collagenase, gelatinase and oxygen free radicals. So, it is believed that they can participate in the pathogenesis of chronic inflammatory joint conditions (Inoue *et al.*, 2001).

CONCLUSION

Data of this research expressed that oral administration of CS extract for 4 weeks showed its curative effects on articular cartilages due to inhibitory action on OA degradation, indicating its plausible anti-inflammatory activity against OA changes. These changes were well correlated with those findings of IHC which exposed significant improvement of neuronal markers at the synovial membranes. We thought that PGE_2 but not $\text{PGF}_{2\alpha}$ play a role in the pathogenesis and the disease subsiding.

In addition to that results of earlier therapeutic application of this extract reflect importance of earlier treatment on the progression of this degenerative joint disease. Hence, improvement of the diagnostic tools will contribute in earlier and successful diagnosis of this disease and subsequently earlier treatment will slow down the high incidence of this troublesome illness in both human and different domestic animals.

ACKNOWLEDGEMENTS

The researcher wish to thank University Putra Malaysia as this study was supported by e-Science grant (Project No.: 02-01-04-SF0882) awarded by Ministry of Science, Technology and Innovation. The researcher also wishes to thank Haruan Research Group Center, Faculty of Medicine and Health Sciences, Universiti Putra Malaysia.

REFERENCES

- Arden, N. and M.C. Nevitt, 2006. Osteoarthritis: Epidemiology. *Best Practice Res. Clin. Rheumatol.*, 20: 3-25.
- Baie, S. and K.A. Sheikh, 2000. The wound healing properties of *Channa striatus*-cetrimide cream-tensile strength measurement. *J. Ethnopharmacol.*, 71: 93-100.
- Bastos-Pereira, A.L., D. Lugarini, A. Oliveira-Christoff, T.V. Avila and S. Teixeira *et al.*, 2010. Celecoxib prevents tumor growth in an animal model by a COX-2 independent mechanism. *Cancer Chemotherapy Pharmacol.*, 65: 267-276.
- Bove, S.E., S.L. Calcaterra, R.M. Brooker, C.M. Huber and R.E. Guzman *et al.*, 2003. Weight bearing as a measure of disease progression and efficacy of anti-inflammatory compounds in a model of monosodium iodoacetate-induced osteoarthritis. *Osteoarthritis Cartilage*, 11: 821-830.
- Brain, S.D. and H.M. Cox, 2006. Neuropeptides and their receptors: Innovative science providing novel therapeutic targets. *Br. J. Pharmacol.*, 147: S202-S211.
- Cahue, S., L. Sharma, D. Dunlop, M. Ionescu and J. Song *et al.*, 2007. The ratio of type II collagen breakdown to synthesis and its relationship with the progression of knee osteoarthritis. *Osteoarthritis Cartilage*, 15: 819-823.
- Carmona, J.U., D. Arguelles, F. Climent and M. Prades, 2007. Autologous platelet concentrates as a treatment of horses with osteoarthritis: A preliminary pilot clinical study. *J. Equine Vet. Sci.*, 27: 167-170.
- Choi, J.H., J.H. Choi, D.Y. Kim, J.H. Yoon and H.Y. Youn *et al.*, 2002. Effects of SKI 306X, a new herbal agent on proteoglycan degradation in cartilage explant culture and collagenase-induced rabbit osteoarthritis model. *Osteoarthritis Cartilage*, 10: 471-478.
- Cournil, C., B. Liagre, L. Grosin, C. Vol and A. Abid *et al.*, 2001. Overexpression and induction of heat shock protein (Hsp) 70 protects *in vitro* and *in vivo* from mono-iodoacetate (MIA)-induced chondrocytes death. *Arthritis Res.*, 3: 41-41.
- Dumond, H., N. Presle, P. Pottier, S. Pacquelet and B. Terlain *et al.*, 2004. Site specific changes in gene expression and cartilage metabolism during early experimental osteoarthritis. *Osteoarthritis Cartilage*, 12: 284-295.
- Duncan, B., X. Lascelles, M.H. Court, E.M. Hardie and S.A. Robertson, 2007. Non-steroidal anti-inflammatory drugs in cats. A review. *Vet. Anesthesia Analgesia*, 34: 228-250.
- Fernihough, J., C. Gentry, M. Malcangio, A. Fox and J. Rediske *et al.*, 2004. Pain related behavior in two models of osteoarthritis in the rat knee. *Pain*, 112: 83-93.

- Guzman, R.E., M.G. Evans, S. Bove, B. Morenko and K. Kilgore, 2003. Mono-iodoacetate-induced histologic changes in subchondral bone and articular cartilage of rat femoro-tibial joints: An animal model of osteoarthritis. *Toxicol. Pathol.*, 31: 619-624.
- Hattori, K., K. Ikeuchi, Y. Morita and Y. Takakura, 2005. Quantitative ultrasonic assessment for detecting microscopic cartilage damage in osteoarthritis. *Arthritis Res. Ther.*, 7: 38-46.
- Hinton, R., R.L. Moody, A.W. Davis and S.F. Thomas, 2002. Osteoarthritis: Diagnosis and therapeutic considerations. *Am. Family Physician*, 65: 841-848.
- Inoue, H., Y. Shimoyama, K. Hirabayashi, H. Kajigaya, S. Yamamoto, H. Oda and Y. Koshihara, 2001. Production of neuropeptide substance P by synovial fibroblasts from patients with rheumatoid arthritis and osteoarthritis. *Neuroscience Lett.*, 303: 149-152.
- Jais, A.M.M., Y.M. Dambisya and T.L. Lee, 1997. Antinociceptive activity of *Channa striatus* (Haruan) extract in mice. *J. Ethnopharmacol.*, 57: 125-130.
- Janusz, M.J., A.M. Bendele, K.K. Brown, Y.O. Taiwo, L. Hsieh and S.A. Heitmeyer, 2002. Induction of osteoarthritis in the rat by surgical tear of the meniscus: Inhibition of joint damage by a matrix metalloproteinase inhibitor. *Osteoarthritis Cartilage*, 10: 785-791.
- Kikuchi, T., T. Sakuta and T. Yamaguchi, 1998. Intraarticular injection of collagenase induces experimental osteoarthritis in mature rabbits. *Osteoarthritis Cartilage*, 6: 177-186.
- Kobayashi, K., R. Imaizumi, H. Sumichika, H. Tanaka, M. Goda, A. Fukunari and H. Komatsu, 2003. Sodium iodoacetate-induced experimental osteoarthritis and associated pain model in rats. *J. Vet. Med. Sci.*, 65: 1195-1199.
- Mapp, P.I., D.A. Walsh, N.E. Garrett, B.L. Kidd, S.C. Cruwys, J.M. Polak and D.R. Blake, 1994. Effect of three animal models of inflammation on nerve fibers in the synovium. *Ann. Rheumatic Dis.*, 53: 240-246.
- Mat Jais, A.M., M.F. Matori, P. Kittakoo and K. Suwanborirux, 1998. Fatty acid compositions in mucus and roe of Haruan, *Channa striatus*, for wound healing. *Genet. Pharmacol.*, 30: 561-563.
- Mat Jais, A.M., R. McCulloch and K. Croft, 1994. Fatty acid and amino acid composition in Haruan as a potential role in wound healing. *Gen. Pharmacol.*, 25: 947-950.
- Moreland, L.W., 2003. Intra-articular hyaluroan (hyaluronic acid) and hylans for the treatment of osteoarthritis: Mechanisms of action. *Arthritis Res. Ther.*, 5: 54-67.
- Pelletier, J.P., J.P. Caron, C. Evans, P.D. Robbins and H.I. Georgescu *et al.*, 2005. *In vivo* suppression of early experimental osteoarthritis by interleukin-1 receptor antagonist using gene therapy. *Arthritis Rheumatism*, 40: 1012-1019.
- Pomonis, J.D., J.M. Boulet, S.L. Gottshall, S. Phillips, R. Sellers, T. Bunton and K. Walker, 2005. Development and pharmacological characterization of a rat model of osteoarthritis pain. *Pain*, 114: 339-346.
- Saxler, G., F. Loer, M. Skumavc, J. Pfortner and U. Hanesch, 2007. Localization of SP- and CGRP-immunopositive nerve fibers in the hip joint of patients with painful osteoarthritis and of patients with painless failed total hip arthroplasties. *Eur. J. Pain*, 11: 67-74.
- Somchit, M.N., M.H. Solihah, D.A. Israf, Z. Ahmad, A.K. Arifah and A.M.M. Jais, 2004. Anti-inflammatory activity of *Channa striatus*, *Channa micropeltes* and *Channa lucius* extracts: Chronic inflammatory modulation. *J. Oriental Pharmacy Exp. Med.*, 4: 91-94.
- Stephen, L.C., M.C. Steven and L.C. James, 2005. Non-steroidal anti-inflammatory drugs: A Review. *J. Am. Anim. Hospital Assoc.*, 41: 298-309.
- Williams, V.S., 2007. Intraarticular hyaluronic acid supplementation in the horse: The role of molecular weight. *J. Equine Vet. Sci.*, 27: 298-303.
- Zakaria, Z.A., M.N. Somchit, M.R. Sulaiman and A.M. Mat Jais, 2004. Preliminary investigation on the antinociceptive properties of haruan (*Channa striatus*) fillet extracted with various solvent systems. *Pak. J. Biol. Sci.*, 7: 1706-1710.
- Zuraini, A., M.N. Somchit, M.H. Solihah, Y.M. Goh and A.K. Arifah *et al.*, 2006. Fatty acid and amino acid composition of three local Malaysian *Channa* spp. fish. *Food Chem.*, 97: 674-678.