

Evaluation of Wound Healing Activity of Silymarin (*Silybum marianum*) in Streptozotocin Induced Experimental Diabetes in Rats

¹Ali Aliabadi, ²Alireza Yousefi, ²Amirashkan Mahjoor and ³Maryam Farahmand

¹Department of Clinical Sciences, ²Department of Pathobiology,
School of Veterinary Medicine, ³Department of Biology, Islamic Azad University,
Kazeroun Branch, Kazeroun, Iran

Abstract: Milk thistle is native to the Mediterranean region. The plant's leaves and seeds have been used continuously since, at least Greco-Roman days for treating many ailments particularly those that affect the liver. Silymarin and silybin used so far mostly as hepatoprotectants were shown to have other interesting activities. These activities were demonstrated in a large variety of illnesses of different organs as e.g., prostate, lungs, CNS, kidneys, pancreas and others. Besides the cytoprotective activity of silybin mediated by its antioxidative and radical-scavenging properties also new activities based on the specific receptor interaction were discovered e.g., inhibition and modulation of drug transporters, P-glycoproteins, estrogenic receptors, nuclear receptors and some others. The objective of the study is to evaluate the diabetic wound healing activity of *Silybum marianum* using the excision wound model in a streptozotocin induced diabetic rats. The animals were weight matched and placed into seven groups (n = 10 group). Group I, normal control rats. Group II, normal scheme rats which were treated with simple ointment base. Groups III and IV, diabetic control and scheme. Groups V-VII, diabetic test rats which were treated with 5, 10 and 20% silymarin ointment. All animals were experimentally wounded on the posterior surface. The efficacy of treatment was evaluated based on wound area relative and histopathological characteristics. The silymarin ointment treated diabetic animals showed significant reduction in the wound area when compared with diabetic control and all other groups. Also, histological studies of the tissue obtained on day 7th and 15th from the treatment groups by silymarin ointment showed increased well organized bands of collagen, more fibroblasts and few inflammatory cells. There was no significant (p<0.05) difference between treatment groups. These findings demonstrate that 5, 10 and 20% ointment of silymarin effectively stimulates wound contraction as compared to control group and other groups and may be useful in treatment of diabetic wounds.

Key words: Wound healing, *Silybum marianum*, diabetic rats, drug, animals, treatment groups

INTRODUCTION

Diabetes mellitus is a metabolic disorder of the endocrine system. People suffering from diabetes are not able to produce or properly use insulin in the body so, they have a high level of blood glucose (Li *et al.*, 2004). The prevalence of diabetes is increasing worldwide and has been forecast to double in the next 20 years (McLennan *et al.*, 2006).

Variety of complications affecting the vascular system, kidney, retina, lens, peripheral nerves and skin are common and are extremely costly in terms of longevity and quality of life. This major increase in morbidity and mortality of diabetes is due to the development of both macro and micro-vascular complications including failure of the wound healing process. Diabetic wound is one of

the main complications in diabetes mellitus. Diabetic wounds are slow, non-healing wounds that can last for weeks despite adequate and appropriate care (Singer and Clark, 1999). Diabetes mellitus is a condition which is known to be associated with a variety of connective tissue abnormalities (Goodson and Hunt, 1977).

The collagen content of the skin is decreased as a result of reduced biosynthesis and/or accelerated degradation of newly synthesized collagen. These abnormalities contribute to the impaired wound healing observed in diabetes (Goodson and Hunt, 1977). Increased oxidative stress is a widely accepted participant in the development and progression of diabetes and its complications (Ceriello, 2000). Abnormally, high levels of free radicals and the simultaneous decline of antioxidant defense mechanisms can lead to damage of cellular

organelles and enzymes, increased lipid peroxidation and development of insulin resistance (Baynes and Thorpe, 1999). Wound care can be traced back to early civilizations and many of these treatments were based on the use of herbal remedies (Mantle *et al.*, 2001).

A review of the ethnobotanical studies carried out in Iran, reveal the use of variety of plant species by the inhabitants of the area, especially by those habiting the rural areas for wound healing purpose. *Silybum marianum* (L.) Gaertn. is a member of the Asteraceae family and its seed extract contains large numbers of chemical constituents including several flavonolignans collectively known as silymarin (Pepping, 1999). Silymarin is a polyphenolic flavonoid extracted from the milk thistle that has a strong antioxidant activity and exhibits cytoprotective, anti-inflammatory and anticarcinogenic effects (Zhao *et al.*, 2000). In addition to its free radical scavenging properties, silymarin increases antioxidant enzymes such as Superoxide Dismutase (SOD) and catalase and inhibits lipid peroxidation (Bosisio *et al.*, 1992).

Topical application of silymarin were used to treat number of skin disorders including erythema, edema, sunburncell formation, hyperplasia, immune suppression, DNA damage, photoaging, melanogenesis and skin cancers (Kren and Walterov, 2005). There is no previous report on diabetic wound healing activities of Silymarin in literature to the best of the knowledge and in this study, the researchers report for the first time, the efficacy of *Silybum marianum* in the treatment and management of diabetic wounds.

MATERIALS AND METHODS

Streptozotocin and Silymarin was obtained from Sigma-Aldrich Chemical Co. (Steinheim, Germany). Silymarin was prepared in Eucerin base as 5, 10 and 20% ointment.

Animals: Adult male Wistar rats (150 and 180 g) at the same age were used. The animals were housed in standard environmental conditions of temperature ($22\pm 3^{\circ}\text{C}$), humidity ($60\pm 5\%$) and a 12 h light/dark cycle. During experimental time, Wistar rats were given standard pellet diet (Pastor Institute, Iran) and water *ad libitum*. All the procedures were approved by the Medical Ethics Committee of Iran University of Medical Sciences.

Induction of experimental diabetes: The animals were fasted overnight and diabetes was induced by a single intraperitoneal injection of freshly prepared solution of Streptozotocin (55 mg kg^{-1} body weight) in 0.1 M cold

citrate buffer pH 4.5 (Rakieten *et al.*, 1963). The animals were allowed to drink 5% glucose solution overnight to overcome drug induced hypoglycaemia. The control rats were injected with citrate buffer alone. After a week's delay for the development of diabetes, the rats with moderate diabetes i.e., with glycosuria and hyperglycaemia (Blood glucose range above 250 mg dL^{-1}) were considered as diabetic and used for the drug treatment.

Experimental design: The animals were randomly placed into seven groups of ten rats each:

- Group I: Normal control rats which received no treatment
- Group II: Normal scheme rats which were treated with simple ointment base
- Group III: Diabetic control rats which received no treatment
- Group IV: Diabetic scheme rats which were treated with simple ointment base
- Group V: Diabetic test rats which were treated with 5% ointment of Silymarin
- Group VI: Diabetic test rats which were treated with 10% ointment of Silymarin
- Group VII: Diabetic test rats which were treated with 20% ointment of Silymarin

Excision wound creation: All the rats were anesthetized with ketamine hydrochloride (40 mg/kg/body weight) and shaved of the back with an electric clipper and prepared for aseptic surgery. The full thickness of 2×1 cm diameters with 0.2 cm depth of the excision wound was created on the back of the rats using toothed forceps, a surgical blade and pointed scissors.

The group V-VII animals were treated topically with the silymarin ointment a (100 mg kg^{-1} body weight) which was applied as a single layer thickness to the wound for 15 days. Groups II and IV were received eucerin as basic ointment topically for 15 days. Two other groups received no treatment.

Data analysis: During the wound healing period and at time intervals, the wound area was traced manually and photographed. The wound area was calculated using Scion Image Version 4.03 software. At day 7th and 15th of experiment, the wound area was removed and send to histology laboratory in 10% formalin.

Statistical analysis: Results, expressed as mean \pm SD. One-way analysis of variance was used to examine

differences in wound healing between the groups. Data was analyzed using the statistical package for SPSS and $p < 0.05$ was taken as the cut off level for significance.

RESULTS AND DISCUSSION

On days 5, 10 and 15th the wound area relative of diabetic extract ointment treated groups (V-VII) were found to be significant ($p < 0.05$) in comparison to all other groups. There was no significant difference between diabetic treatments groups however maximum treatment group showed better result grossly. Wound rate contraction was significantly better in group II compare to diabetic groups that received no treatment (Group III and IV).

No significant difference was observed between group I and II. By day 15th, wounds in diabetic animals treated with the experimental extracts had closed by 75% as compared with wounds treated with the basic ointment in diabetic group ($p < 0.05$) and the wound contraction result in group II was 51% of group III. The histological study of the healing tissue obtained from the diabetic animals of extracts treated (Fig. 1) showed good epithelization and the fast lay-down of collagen fibers when compared to diabetic controls (Group III and IV). By day 15th, collagen arrangement was better in group I and II compare to group III and VI. Impaired wound healing is the pivotal event responsible for most of the morbidity (and mortality) of diabet. Normal wound healing is

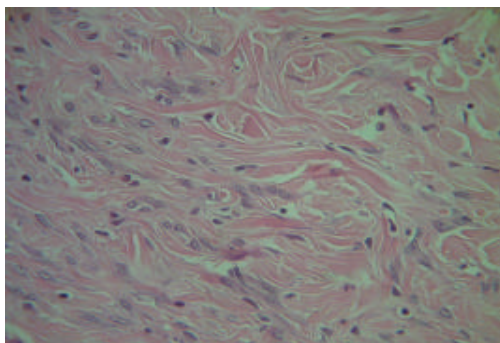


Fig. 1: Diabetic controls treated with basic ointment (day 15). Ulceration, acute inflammation, granulation tissue formation

characterised by an orderly series of cell and tissue responses that can be grouped into four major phases. The initial injury phase stimulates platelet aggregation and clot formation to attain haemostasis. The other phases include inflammatory phase, proliferation and during the 4th and final stage of wound healing, the granulation tissue is further remodelled to increase wound tensile strength (Jeffcoate *et al.*, 2004).

In wounds that occur in diabetes, a persistent inflammatory phase is commonly witnessed at histopathology, associated with a delay in the formation of mature granulation tissue and a parallel reduction in wound tensile strength (Wall *et al.*, 2002). Di Girolamo *et al.* (1993) postulated that defects in wound healing are caused by the hyperglycosylation of the locally synthesised cellular fibronectin. Hyperglycaemia affects the whole range of neutrophil functions including migration, chemotaxis, adherence and phagocytic and bactericidal activity (Wall *et al.*, 2003). Decreases in growth factors responsible for tissue repair such as Platelet Derived Growth Factor (PDGF) and Transforming Growth Factor-b (TGF-b) have also been documented in diabetic wounds (Huang *et al.*, 2002). Silymarin is a standardized extract obtained from the seeds of *S. marianum* containing approximately 70-80% of the silymarin flavonolignans and approximately 20-30% chemically undefined fraction, comprising mostly polymeric and oxidized polyphenolic compounds.

In the present study, the wound healing potential in diabetic animals for *Silybum marianum* was evident on the day 15th (Table 1 and Fig. 2), this potential was further confirmed in the histological evaluation (Table 2 and Fig. 3). Animals with induced diabetes in experimental groups had reduced inflammatory phase on day 7 compared with the wounds in control animals which show extensive inflammation on the day 7. Many lines of evidence support the idea that milk thistle and silymarin produce anti-inflammatory activity (Fig. 4). Silymarin had significant anti-inflammatory and antiarthritic activities in rats (Gupta *et al.*, 2000).

Orally administered silymarin reduced carrageenan-induced paw edema in rats and topically reduced ear mouse inflammation that had been induced the effects of the herb were comparable to indomethacin

Table 1: Diabetic wound healing activity of *Silybum marianum* in the streptozotocin induced rats (Wound area measurement, mm²)

Days	Group I	Group II	Group III	Group IV	Group V	Group VI	Group VII
1	195.50±2.60	190.10±2.23	189.80±4.01	190.7±2.52	190.10±5.30	198.9±6.60	199.80±3.70
5	137.32±2.00	130.20±1.80	148.35±3.20	145.5±2.31	82.30±1.99*	80.2±3.10*	78.80±1.87*
10	56.45±1.30	34.20±0.72**	60.50±2.70	61.55±1.9	24.23±1.70*	21.7±2.12*	20.62±1.81*
15	18.50±0.32	16.31±0.41**	33.00±0.40	32.8±0.52	8.10±0.34*	7.1±0.61*	7.60±0.21*

Values are mean±SD of 10 animals in each group * $p < 0.05$. Group I: Normal control; Group II: Normal positive control; Group III: Diabetic control; Group IV: Diabetic positive control; Group V: Diabetic experimental (Minimum); Group VI: Diabetic experimental (Intermediate); Group VII: Diabetic experimental (Maximum); *compare with groups I-IV; **compare with groups III and IV

Table 2: Effect of the treatments on the evolution of wounds in rats after 7 and 15 days of topical application

Factors	Days	Group I	Group II	Group III	Group IV	Group V	Group VI	Group VII
Inflammatory cells	7	++	++	+++	+++	+	+	+
	15	+	+	++	++	-	-	-
Re-epithelization	7	-	-	-	-	+	+	+
	15	+	+	-	-	+++	+++	+++
Collagen formation	7	-	-	-	-	+	+	+
	15	+	+	-	-	++	++	+++

+: Mild; ++: Moderate; +++: Extensive; n: Absent

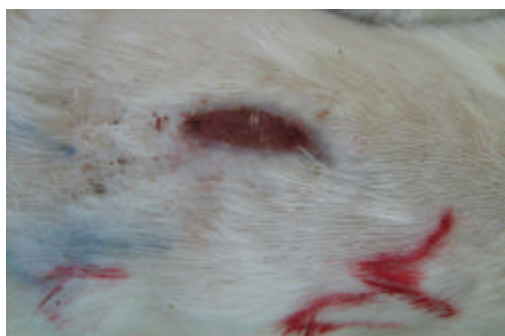


Fig. 2: Diabetic controls treated with basic ointment (day 15)

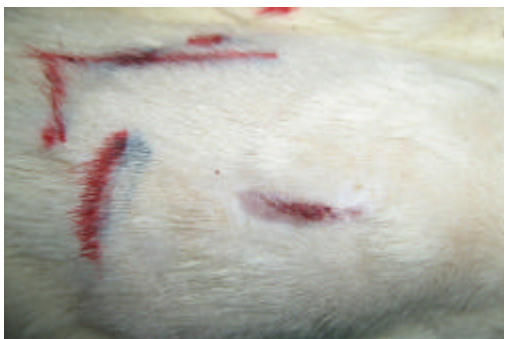

Fig. 3: Diabetic experimental treated with silymarin 20% (day 15)

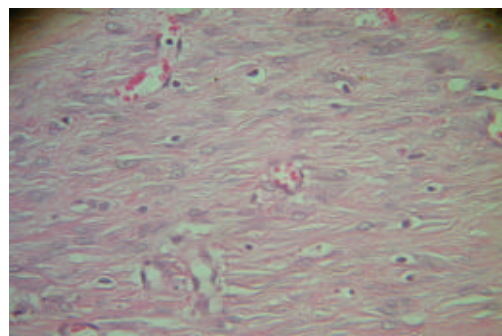


Fig. 4: Diabetic experimental treated with silymarin 20% (day 15). Spare inflammatory cells, collagen formation, re-epithelialization

(De La Puerta *et al.*, 1996). Transcription factor NF-kappa-B is a key regulator in inflammatory and immune reactions. *In vitro* silymarin suppresses NFkappa-B in a potent manner but does not affect TNF (Tumor Necrosis Factor)-alpha-induced NF-kappa-B activation (Saliou *et al.*, 1998). At doses achievable by oral supplementation, silybinin significantly inhibited leukotriene formation by Kupffer cells *in vitro* by inhibiting the 5-lipo-oxygenase pathway (Dehmlow *et al.*, 1996).

Other studies support the inhibitory effects of silymarin and its flavonolignan constituents inhibit lipoxygenase and prostaglandin synthetase *in vitro* (Fiebrich and Koch, 1979). Prolonged inflammation is associated with increased neutrophil infiltration and increased protease activity. Neutrophil instability in diabetic wounds, increase reactive oxygen species which

impair wound healing. Silymarin had a neuroprotective effect on microglial cell cultures and appears to inhibit nitric oxide production and *iNOS* gene activation (Kang *et al.*, 2002). An extract of milk thistle prolonged neurite survival (Kittur *et al.*, 2002). From another aspect, diabetes is usually accompanied by increased production of free radicals (Maritim *et al.*, 2003). Excessively high levels of free radicals cause damage to cellular proteins, membrane lipids and nucleic acids and eventually cell death. Silymarin is a polyphenolic flavonoid that has a strong antioxidant activity and exhibits cytoprotective effects. Another possible mechanism underlying the cytoprotective effect of silymarin could be to increase antioxidant enzymes such as SOD, Glutathione peroxidase (Gpx) and catalase as previously described by Soto *et al.* (2003).

In the present study, diabetic rats in experimental groups had reduced wound size as early as day 5th and till the end of the experiment compared with the other groups. The rodent models have an advantage over human studies in that factors such as the glycaemic control, wound size and infection status can be systematically controlled. However, unlike the situation in humans, rodent wounds heal partly by contraction rather than by granulation tissue formation and epithelialisation, limiting its applicability to the study of ulcers in diabetes. Milk thistle has a well-established role as a hepatoprotectant. It should also be considered as a renal protectant and shows strong potential as a component of

cancer treatment regimens and as an adjunct support to chemo and radiation therapy but the exact component of the Silymarin that is responsible for all. Its possible effects on diabetic wound healing however was not investigated. Further phytochemical studies are needed to isolate the active compound(s) responsible for this pharmacological activity.

CONCLUSION

The present study suggested that the topical administration of silymarin ointment plays a major role to stimulate wound contraction as compared to control group and other groups. However, it is not dose dependent at the concentration of 5, 10 and 20%. The present documented findings may suggest the use of *Silybum marianum* to treat and management of diabetic wounds.

ACKNOWLEDGEMENT

This study was supported by Islamic Azad University, Kazerun Branch.

REFERENCES

- Baynes, J.W. and S. Thorpe, 1999. Role of oxidative stress in diabetic complications: A new perspective on an old paradigm. *Diabetes*, 48: 1-9.
- Bosisio, E., C. Benelli and O. Pirola, 1992. Effect of the flavanolignans of *Silybum marianum* L. on lipid peroxidation in rat liver microsomes and freshly isolated hepatocytes. *Pharmacol. Res.*, 25: 147-154.
- Ceriello, A., 2000. Oxidative stress and glycemic regulation. *Metabolism*, 49: 27-29.
- De La Puerta, R., E. Martinez, L. Bravo and M.C. Ahumada, 1996. Effect of silymarin on different acute inflammation models and on leukocyte migration. *J. Pharm. Pharmacol.*, 48: 968-970.
- Dehmlow, C., J. Erhard and H. de Groot, 1996. Inhibition of Kupffer cell functions as an explanation for the hepatoprotective properties of silibinin. *Hepatology*, 23: 749-754.
- Di Girolamo, N., A. Underwood, P.J. McCluskey and D. Wakefield, 1993. Functional activity of plasma fibronectin in patients with diabetes mellitus. *Diabetes*, 42: 1606-1613.
- Fiebrich, F. and H. Koch, 1979. Silymarin, an inhibitor of prostaglandin synthetase. *Cell. Mol. Life Sci.*, 35: 1550-1552.
- Goodson, W.H. and T.K. Hunt, 1977. Studies of wound healing in experimental diabetes mellitus. *J. Surg. Res.*, 22: 221-227.
- Gupta, O.P., S. Sing, N. Bani, B.D. Malhotra, S.K. Gupta and B. Handa, 2000. Anti-Inflammatory and anti-arthritis activities of silymarin acting through inhibition of 5-lipoxygenase. *Phytomedicine*, 7: 21-24.
- Huang, J.S., Y.H. Wang, T.Y. Ling, S.S. Chuang, F.E. Johnson and S.S. Huang, 2002. Synthetic TGF- β antagonist accelerates wound healing and reduces scarring. *FASEB J.*, 16: 1269-1270.
- Jeffcoate, W.J., P. Price and K.G. Harding, 2004. Wound healing and treatments for people with diabetic foot ulcers. *Diabetes Metab. Res. Rev.*, 20: S78-S89.
- Kang, J.S., Y.J. Jeon, H.M. Kim, S.H. Han and K.H. Yang, 2002. Inhibition of inducible nitric-oxide synthase expression by silymarin in lipopolysaccharide-stimulated macrophages. *J. Pharmacol. Exp. Ther.*, 302: 138-144.
- Kittur, S., S. Wilasrusmee, W.A. Pedersen, M.P. Mattson and K. Straube-West *et al.*, 2002. Neurotrophic and neuroprotective effects of milk thistle (*Silybum marianum*) on neurons in culture. *J. Mol. Neurosci.*, 18: 265-269.
- Kren, V. and D. Walterov, 2005. Silybin and silymarin-new effects and applications. *Biomed. Papers*, 149: 29-41.
- Li, W.L., H.C. Zheng, J. Bukuru and N. de Kimpe, 2004. Natural medicines used in the traditional Chinese medical system for therapy of diabetes mellitus. *J. Ethnopharmacol.*, 92: 1-21.
- Mantle, D., M.A. Gok and T.W.J. Lennard, 2001. Adverse drug react. *Toxicol. Rev.*, 20: 89-103.
- Maritim, A.C., R.A. Sanders and J.B. Watkins, 2003. Diabetes, oxidative stress and antioxidants: A review. *J. Biochem. Mol. Toxicol.*, 17: 24-38.
- McLennan, S., D.K. Yue and S.M. Twigg, 2006. Molecular aspects of wound healing in diabetes. *Primary Intention*, 14: 8-13.
- Pepping, J., 1999. Milk thistle: *Silybum marianum*. *Am. J. Health Syst. Pharm.*, 56: 1195-1197.
- Rakieten, N., M.L. Rakieten and M.V. Nadkarni, 1963. Studies on the diabetogenic action of streptozotocin (NSC-37917). *Cancer Chemother. Rep.*, 29: 91-98.
- Salio, C., B. Rihn, J. Cillard, T. Okamoto and L. Packer, 1998. Selective inhibition of NF- κ B activation by flavonoid hepatoprotector silymarin in HepG2. Evidence for different activating pathways. *FEBS Lett.*, 440: 8-12.
- Singer, A.J. and R.A.F. Clark, 1999. Cutaneous wound healing. *N. Engl. J. Med.*, 341: 738-746.

- Soto, C., R. Recoba, H. Barron, C. Alvarez and L. Favari, 2003. Silymarin increases antioxidant enzymes in alloxan-induced diabetes in rat pancreas. *Compar. Biochem. Physiol. Part C*, 136: 205-212.
- Wall, S.J., D. Bevan, D.W. Thomas, K.G. Harding, D.R. Edwards and G. Murphy, 2002. Differential expression of matrix metalloproteinases during impaired wound healing of the diabetes mouse. *J. Invest. Dermatol.*, 119: 91-98.
- Wall, S.J., M.J. Sampson, N. Levell and G. Murphy, 2003. Elevated matrix metalloproteinase-2 and -3 production from human diabetic dermal fibroblasts. *Br. J. Dermatol.*, 149: 13-16.
- Zhao, J., M. Lahiri-Chatterjee, Y. Sharma and R. Agarwal, 2000. Inhibitory effect of a flavonoid antioxidant silymarin on benzoyl peroxide-induced tumor promotion, oxidative stress and inflammatory responses in SENCAR mouse skin. *Carcinogenesis*, 21: 811-816.