

## Effect of Simvastatin on Apoptosis Inhibition in Renal Tissue after Unilateral Ureteral Obstruction in Rat

<sup>1</sup>Neshat Gharamaleky Mehrdad, <sup>2</sup>Doustar Yousef and <sup>3</sup>Safarmashaei Saeid

<sup>1</sup>Department of Clinical Science, <sup>2</sup>Department of Pathobiology, <sup>3</sup>Young Researchers Club, Islamic Azad University, Tabriz Branch, Tabriz, Iran

**Abstract:** Obstructive uropathy can be used to indicate any obstruction to urinary flow which causes a developing of hydronephrosis, tubular atrophy and associated renal impairment. Comparative reductase inhibitors such as simvastatin increase HDL-cholesterol and decrease serum triglyceride and cholesterol. It is widely recognized that statins have organ protective nature and most effective for organ damage progressing. The aim of this study was evaluation of simvastatin on apoptosis in renal tissue after unilateral ureteral obstruction in rat. In this experimental study, 50 adult male Sprague-Dawley rats were subjected to Unilateral Ureteral Obstruction (UUO) and randomly divided into five groups (ten rats in each groups) as follows: Control group, UUO, UUO/SIM, Sham-operated and Sham/SIM. Control animals received orally drug solvent by gavage for 15 days (start before operation). Unilateral ureteral obstruction was performed in groups 2 and 3 and sham operations were performed in groups 4 and 5. In group 2 animals received drug solvent and in group 3 animals received simvastatin (2 mg/kg/twice daily) for 15 days. Rats were sacrificed either at day 14. After sampling and fixation in saline formalin 10%, tissue processing and preparing histological section and staining with tunnel method, apoptosis were studied in renal tissue in different groups. Tunnel staining determined that experimental unilateral ureteral obstruction caused of induction of apoptosis in tubular cells of renal tissue. But in simvastatin treated animals number of apoptotic cells significantly ( $p < 0.05$ ) decreased. There was no significant difference between control and sham groups. The results showed that experimental unilateral ureteral obstruction induced apoptosis in renal tissue but simvastatin administration decreased number of apoptotic cells in renal tissue. It needs to be more investigation for approving of organ protective action of simvastatin in human renal disorders.

**Key words:** Unilateral ureteral obstruction, apoptosis, simvastatin, kidney, rat, Iran

---

### INTRODUCTION

Any disorder in normal urinary channels and its consequences called obstructive uropathy. Urine obstruction and halting has very important effect on kidney's function injury in urological point of view. Any kind of obstruction can cause subsequently to hydro-nephritis, atrophy and even complete loss of renal function. Furthermore, obstruction can lead to infection and make double the injury caused by obstruction. Several diseases cause urinary obstruction and the prognosis about which is variable, the disease depend upon location and severity of obstruction and body reaction to this occurrence. Therefore, obstructive uropathy must be included in as a disease so encounter fewer problems in remedial plans. The upper the location of obstruction, the greater of its effect on kidney. The effects of obstruction on renal function are very important

in its prognosis and treatment. Exact mechanism of changes in renal function has not been verified completely and attracts the attention of most of researcher (Klahr, 1991; Klahr and Purkerson, 1994). Competitive restrainers of redoketaze are structural analogous of 3-Hydroxy-3-Methyl Glutaryl-Coenzyme A (HMG-CoA). Simvastatin is as an inactive premedication which changes to active  $\beta$ -hydroxy derivatives in digestive system. The most effect of this medicine is on liver. This preferential effect can be attributed to the difference in medicine adsorption from blood circulation in different tissues. Decrease in plasma triglycerides and increase in HDL<sup>2</sup> cholesterol occur during utilization of this medicine. In some disease in which LDL<sup>2</sup> plasma level has increased HMO-CoA restrainers are effective (Bayorh *et al.*, 2005; Inman *et al.*, 2005; Iseri *et al.*, 2007; Rugale *et al.*, 2007; Vieira *et al.*, 2005). Various studies have shown that statins like simvastatin have protective effects on some

tissues such that it has been characterized that simvastatin decreases the liver and renal toxicity caused by cis-platin in rats (Isciri *et al.*, 2008). Also following renal chronic insufficiency in rat, simvastatin decreased renal losses caused by this phenomenon. In patients stricken by chronic renal diseases, the injury of heart tissue followed by renal insufficiency was decreased (Panichi *et al.*, 2008). In another study, it was shown by experimental nephritic syndrome model in rats that simvastatin can decrease injuries caused by oxidative stress as well as can cure proteinuria and decrease the injury of glomeruli (Sonmez *et al.*, 2008). It has been shown that hydroxy methyl glutaryl CoA reductase can prevent hypercholesterolemia and tissue injury subsequent by organ graft and decrease rejection of renal graft (Wanner *et al.*, 1997). Considering that any study has not been found to date based on the effect of simvastatin on apoptosis in renal tissue caused by ureter obstruction therefore, the study aimed at simvastatin effect on renal apoptosis consequence by complete bilateral obstruction of ureter in rats.

#### MATERIALS AND METHODS

**Animals:** This experimental study was conducted on 50 SD strain rats with weight of  $300 \pm 10$  g. The rats were from breeding and keeping center of laboratory animals of Tabriz University and were kept at identical condition and special cages of rats in  $23 \pm 2^\circ\text{C}$  with 12 h lightening and 12 h darkness. Animals were fed using special plates for laboratory animals. Feed and water were available freely.

**Drugs:** Simvastatin, ketamine hydrochloride, xylazine and ether were used in this study. Ethanol and physiological serum with ratio of 1:2 were used for solving simvastatin. Simvastatin was obtained from Sigma Co., ether from Merck Co. and ketamine hydrochloride and xylazine were obtained from Alfasun Co. in Netherlands.

**Experimental design:** In this study, the animals were divided in five groups with 10 animals in each group in separate cages, randomly. In first group (control group) the animals received  $10 \text{ mL kg}^{-1}$  medicine solvent during 15 days (the beginning time was a day before operation). In second group (UUO), the animals received  $10 \text{ mL kg}^{-1}$  medicine solvent during 15 days (the beginning time was a day before operation) after unilateral ureteral obstruction. In third group (UUO/SIM) the animals received  $2 \text{ mL kg}^{-1}$  simvastatin two times a day during 15 days orally (the beginning time was a day before operation) after unilateral ureteral obstruction. In fourth (Sham) and fifth (Sham/SIM) the animals were

operated as second and third groups' animals but ureter channel was not obstructed. Also medicine solvent and simvastatin were used in fourth and fifth groups, respectively. For removing the effect of medicine volume, simvastatin was prescribed  $10 \text{ mL kg}^{-1}$  orally.

**Surgical method:** In order to anesthesia the combination of ketamine hydrochloride ( $60 \text{ mg kg}^{-1}$ ) and xylazine hydrochloride ( $2 \text{ mg kg}^{-1}$ ) was used as intra-peritoneum then a 3 cm length incision was made on the skin of abdomen midline and then on white line of abdomen. After appearing kidney and separating it from lower connection such as renal artery and vein, ureter was obstructed using 2-0 suture in its initial one third. After returning the kidney and viscera in their natural situation, abdomen white-line was sutured simply by absorbable synthetic poly-gelactine 910, 2-0 suture completely. The skin of the main region was sutured using 2-0 silk suture simply single. In Sham group, the animal's abdomen was incised and operation was conducted but the ureter only repaired and didn't obstructed (Vieira *et al.*, 2005; Kaneto *et al.*, 1994; Lange-Sperandio *et al.*, 2005).

**Histopathological examination:** On 14 days following operation, the animals were anesthetized using diethyl ether and after autopsy, left kidney's sample transferred to 10% salty formalin solution (Merck, Germany) for obtaining histologist sections. Various stages of tissue passage were done on samples after fixation and serial sections of  $3 \mu\text{m}$  thickness were obtained following molding by paraffin. Mentioned sections were stained by Tunnel method using standard kit of Roche Co. and according to the manufacturer directions. Toluidine blue from Merck Co. of Germany was used in order to stain tissue background. For staining and administrating of tunnel technique, the obtained sections were washed with kinase protein K and incubation in  $37^\circ\text{C}$  for 30 min with phosphate buffer solution following paraffin and water removing. Then, tissue sections were adjacent to  $50 \mu\text{m}$  tunnel reactive solution in  $37^\circ\text{C}$  for 60 min followed by washing using phosphate buffer solution. In subsequent stage the tissue sections were washed with phosphate buffer solution following incubation with  $50 \mu\text{m}$  converter solution in  $37^\circ\text{C}$  for 30 min then was adjacent with tetrachloride di-amino Benzidine and re-incubated in  $25^\circ\text{C}$  for 20 min. In the following stage the sections were washed with phosphate buffer and stained with toluidine blue. The apoptotic cells which were observed in different parts of kidney's tissue were studied and 20 microscopic fields were selected among sections so the average level of apoptotic cells was recorded by 40x magnification.

**Statistical analysis:** Values were represented as mean±SEM. Data were analysed by one-way Analysis of Variance (ANOVA) followed by Dunnett's test using Statistical Package for Social Sciences (SPSS) version 10.  $p < 0.05$  was considered significant.

**RESULTS AND DISCUSSION**

Study of tissue sections of different groups showed that apoptosis is observed in tubular cells of kidney's tissue (Fig. 1). Statistical analysis of apoptotic cells showed that there isn't meaningful difference between control and sham groups (Table 1). Since, the tissue images of control and sham groups are similar, sham images has not been shown. In UUO group there is sever increase of apoptotic cells in kidney's tubular cells following ureter obstruction (Fig. 2). The average level of apoptotic cells ( $15.52 \pm 1.33$ ) showed meaningful increase

in comparison with control group ( $p < 0.05$ ) (Table 1). Administration of simvastatin during ureter obstruction in UUO/SIM ( $3.12 \pm 0.87$ ) could decrease apoptotic cells arising from ureter obstruction in kidney's tissue compared with UUO group, meaningfully ( $p < 0.05$ ) (Table 1 and Fig. 3).

In the current study, apoptosis phenomenon was evaluated in kidney's tissue after making experimental unilateral ureteral obstruction in rats. In order to observe and count apoptotic cells in testicle tissue, tunnel staining method was used in which quantitative and qualitative evaluation is possible. DNA internucleozemic fragmentation is considered as one of the special events and wasn't observed in any cell death so, tunnel method which is based on DNA fragmentation is the most sensitive and careful method. The 3OH extremity of the broken DNA is the aim of this method such that signed nucleotides are attached to the extremity of sections' 3OH by endogenous enzymes. In subsequent phase the DNA broken sections which have been signed by nucleotides are directed (Miura *et al.*, 2002). Clinical signs and physio-pathologic responses of urine obstruction are under the effect of different factors. Among these factors are the location of obstruction, severity and period of obstruction, existence or lack of urinary tract infection and uni or bilateralobstruction of upper urinary tract. Anuria, azotemia and uremia have been observed along with complete obstruction of urinary tract. A total of 48 h after the complete obstruction of urethra some abnormal signs are observed in blood biochemistry but after 78-72 h later, clinical signs and chemical changes make progress. As a result of complete urethra obstruction, morphologic and functional changes are created. Unilateral and gradual obstruction of ureter is accompanied with urea suppression and parenchyma destruction of kidney and results in kidney's enlargement (Klahr, 1991;

Table 1: Mean of apoptotic cells in renal tissue section after UUO

Groups	Control	UUO	UUO/SIM	Sham	Sham/SIM
Number of apoptotic cells	$0.96 \pm 0.21$	$15.52 \pm 1.33^*$	$3.12 \pm 0.78$	$1.17 \pm 0.29$	$1.84 \pm 0.56$

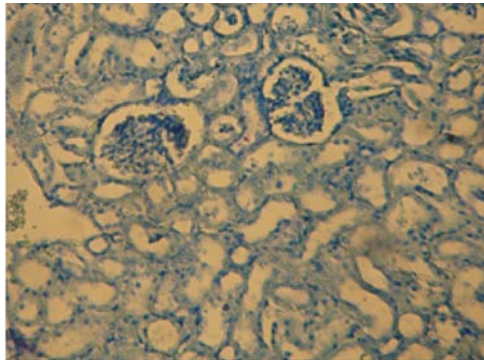


Fig. 1: Photomicrograph of tubular apoptotic cells belong to control group (Tunnel, x10)

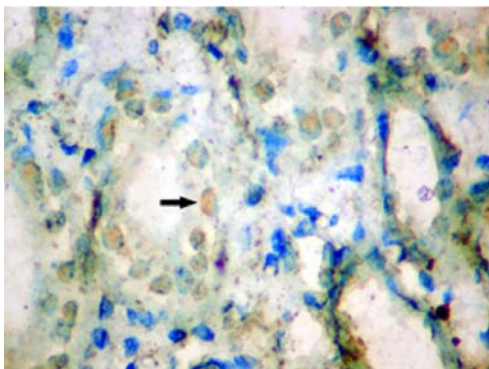


Fig. 2: Photomicrograph of tubular apoptotic cells belong to UUO group (Tunnel, x40)

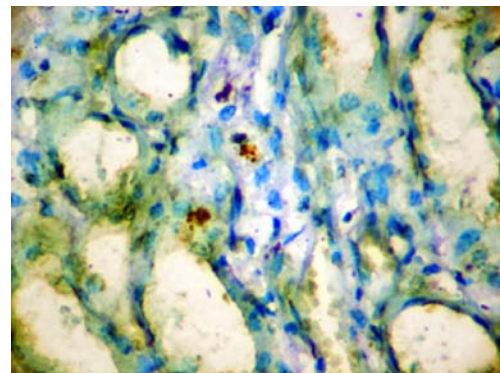


Fig. 3: Photomicrograph of tubular apoptotic cells belong to treated group with Simvastatin (Tunnel, x40)

Klahr and Purkerson, 1994). Many studies have been conducted on kidney's tissue in subjects with urethra obstruction or experimentally created urethra obstruction operationally in human and different animals. Previous studies have shown that unilateral obstruction of ureter in rat can result in half way tubular fibrosis, glomerulosclerosis, inflammatory cells' penetration and half way tissue inflammation. Klahr (1991), Klahr and Purkerson (1994) showed that dilation of Bowman's capsule space, severe glomerular and tubular atrophy and accumulation of unicellular cells occurs following half way tubular fibrosis of ureter obstruction (Klahr, 1991; Klahr and Purkerson, 1994). Kaneto *et al.* (1994) and Gonzales-Avila *et al.* (1988) showed that fibrosis and tissue inflammation of kidney occur followed by ureter obstruction (Kaneto *et al.*, 1994; Gonzalez-Avila *et al.*, 1988). Moriyama *et al.* (2000) and Lange-Sperandio *et al.* (2005) showed that ureter obstruction results in inflammatory cells' penetration and tissue fibrosis of kidney (Lange-Sperandio *et al.*, 2005; Moriyama *et al.*, 2000). In this study, unlike previous studies, apoptosis of tubular cells following experimental obstruction of ureter was studied. It seems that oxidative stress has a key role in starting and continuation of inflammation after the obstruction that its result is kidney's tubular injury, tissue fibrosis, necrosis and apoptosis (Moriyama *et al.*, 2000; Zhou and Kang, 2000). Following the oxidative stress, activation of endonuclease enzymes causes DNA destruction. During this process, DNA is broken to 180-200 open pairs sections which are parts of DNA length that winds around the histones in nucleosomes. In another word, DNA begins to break in connection regions among nucleosomes which is called intra nucleosomal fragmentation (Royere *et al.*, 2004). Beside the mentioned mechanism, other mechanisms cause chromatin changes in cell nucleolus. Inactivation of enzymes which have some roles in repairing DNA is one of these cases. PADP is the first protein that acts in DNA injuries and repair DNA by attaching opened chain of DNA and changing nucleotic proteins. Caspase 3 enzyme which is activated following apoptosis, remove PADP function in DNA repairing by breaking its enzyme (Yin *et al.*, 1997). Apoptotic changes following oxidative stress don't relate exclusively to the changes of apoptotic cell's nucleus and mitochondria are affected. In apoptotic cells' mitochondria, disorder in transferring potential and penetrability of interior layer is diagnosable such that the layer loses the presentation of some molecules leakage (Royere *et al.*, 2004). P53 protein is associated with nucleus coating and is transferred to the nucleus during oxidative stress therefore cell process stopping or cell removing mediated by P53 is occurred (Yin *et al.*, 1998). Therefore, DNA injuries following ureter experimental obstruction and oxidative stress in these cells are not

unexpected. On the other hand it has been shown that experimental ureter obstruction in rats leads to increase of fat peroxidation and inactivation of anti oxidant enzymes. Fat peroxidation and excessive free radicals can cause protein injury, apoptosis induction in kidney's tissue cells (Moriyama *et al.*, 2000; Zhou and Kang, 2000). In a study on rats, experimental obstruction of ureter caused to increase of cell fats' peroxidation which is a sign of oxidative stress. Free radicals produce during natural metabolism of body cells. Free radical production greater than defensive capability of anti oxidants causes to oxidative stress and irreversible responses such as apoptosis or necrosis in live cells (Moriyama *et al.*, 2000; Zhou and Kang, 2000). The results of the study demonstrated that simvastatin caused to decrease the number of kidney's apoptotic cells following ureter obstruction. Various studies have shown that simvastatin has protective effects on some of tissues such that Iscri *et al.* (2007) demonstrated that simvastatin decreases liver and renal toxicity caused by cisplatin in rats (Iscri *et al.*, 2007). Also Ivanovski *et al.* (2008) showed that simvastatin decreases renal injuries following chronic insufficiency of rat kidney (Ivanovski *et al.*, 2008). Panichi *et al.* (2008) in chronic renal patients decreased the severity of heart muscle injury following kidney insufficiency by administering simvastatin (Panichi *et al.*, 2008). Sonmez *et al.* (2008) in another study by experimental nephritic syndrome model on rats showed that simvastatin can decrease injuries caused by oxidative stress as well as can recover protonosis and decrease glomerular injuries (Sonmez *et al.*, 2008). Waner *et al.* (1997) have demonstrated that hydroxy methyl glutaryl CoA reductase can prevent hypercalcaemia and tissue injury following heart and kidney grafting (Waner *et al.*, 1997). Various mechanisms have been considered for protective effect of statins. As mentioned before, oxidative stress has an important role in beginning and continuation of inflammation following obstruction which results in renal tubular cells injury, tissue fibrosis, necrosis and apoptosis (Moriyama *et al.*, 2000; Zhou and Kang, 2000) on the other hand; some studies have demonstrated that simvastatin has anti oxidant effect on renal tissue following injury caused by chemical materials (Bayorh *et al.*, 2005; Inman *et al.*, 2005; Iseri *et al.*, 2007; Rugale *et al.*, 2007). With regard to antioxidative role of simvastatin it can be suggested that the medicine leads to decrease of apoptotic cells number following ureter obstruction by similar mechanism.

## CONCLUSION

The results of this study showed that ureter obstruction causes severe apoptosis induction in renal tissue. The reason of apoptosis occurrence may be

associated with oxidative stress. Coincidental administrating of simvastatin led to decrease the apoptotic cells number. Of course protective role of simvastatin in human renal diseases such as ureter obstruction and oxidative stress requires further studies.

#### REFERENCES

- Bayorh, M.A., A.A. Ganafa, D. Eatman, M. Walton and G.Z. Feuerstein, 2005. Simvastatin and losartan enhance nitric oxide and reduce oxidative stress in salt-induced hypertension. *Am. J. Hypertens*, 18: 1496-1502.
- Gonzalez-Avila, G., F. Vadillo-Ortega and R. Perez-Tamayo, 1988. Experimental diffuse interstitial renal fibrosis. A biochemical approach. *Lab. Invest.*, 59: 245-252.
- Iseri, S., F. Ercan, N.Gedik, M. Yüksel and I. Alican, 2007. Simvastatin attenuates cisplatin-induced kidney and liver damage in rats. *Toxicology*, 230: 256-264.
- Inman, S.R., N.A. Davis, M.E. Mazzone, K.M. Olson, V.A. Lukaszek and K.N. Yoder, 2005. Simvastatin and L-arginine preserve renal function after ischemia/reperfusion injury. *Am. J. Med. Sci.*, 329: 13-17.
- Ivanovski, O., D. Szumilak, T. Nguyen-Khoa, I.G. Nikolov and N. Joki *et al.*, 2008. Effect of simvastatin in apolipoprotein E deficient mice with surgically induced chronic renal failure. *J. Urol.*, 179: 1631-1636.
- Kaneto, H., J. Morrissey, R. McCracken, A. Reyes and S. Klahr, 1994. Enalapril reduces collagen type IV synthesis and expansion of the interstitium in the obstructed rat kidney. *Kidney Int.*, 45: 1637-1647.
- Klahr, S. and M.L. Purkerson, 1994. The pathophysiology of obstructive nephropathy: The role of vasoactive compounds in the hemodynamic and structural abnormalities of the obstructed kidney. *Am. J. Kidney Dis.*, 23: 219-223.
- Klahr, S., 1991. New insights into the consequences and mechanisms of renal impairment in obstructive nephropathy. *Am. J. Kidney Dis.*, 18: 689-699.
- Lange-Sperandio, B., M.S. Forbes, B. Thornhill, M.D. Okusa, J. Linden and R.L. Chevalier, 2005. A<sub>2A</sub> adenosine receptor agonist and PDE<sub>4</sub> inhibition delays inflammation but fails to reduce injury in experimental obstructive nephropathy. *Nephron Exp. Nephrol.*, 100: e113-e123.
- Miura, M., I. Sasagawa, Y. Suzuki, T. Nakada and J. Fujii, 2002. Apoptosis and expression of apoptosis-related genes in the mouse testis following heat exposure. *Fertil. Steril.*, 77: 787-793.
- Moriyama, T., N. Kawada, K. Nagatoya, M. Horio, E. Imai and M. Hori, 2000. Oxidative stress in tubulointerstitial injury: Therapeutic potential of antioxidants towards interstitial fibrosis. *Nephrol. Dial. Transplant.*, 6: 47-49.
- Panichi, V., E. Mantuano, S. Paoletti, S. Santi and G.M. Rizza *et al.*, 2008. Effect of simvastatin on plasma asymmetric dimethylarginine concentration in patients with chronic kidney disease. *J. Nephrol.*, 21: 38-44.
- Royere, D., F. Guerif, V. Laurent-Cadoret and M.T.H. de Reviers, 2004. Apoptosis in testicular germ cells. *Int. Congr. Ser.*, 1266: 170-176.
- Rugale, C., S. Delbosc, A. Mimran and B. Jover, 2007. Simvastatin reverses target organ damage and oxidative stress in Angiotensin II hypertension: Comparison with apocynin, tempol and hydralazine. *J. Cardiovasc Pharmacol.*, 50: 293-298.
- Somez, A., M.I. Yilmaz, A. Korkmaz, T. Topal and K. Caglar *et al.*, 2008. Hyperbaric oxygen treatment augments the efficacy of cilazapril and simvastatin regimens in an experimental nephrotic syndrome model. *Clin. Exp. Nephrol.*, 12: 110-118.
- Vieira, Jr. J.M., E. Mantovani, L.T. Rodrigues, H. Delle, I.L. Noronha, C.K. Fujihara and R. Zatz, 2005. Simvastatin attenuates renal inflammation, tubular transdifferentiation and interstitial fibrosis in rats with unilateral ureteral obstruction. *Nephrol. Dial. Transplant.*, 20: 1582-1591.
- Wanner, C., A. Kramer-Guth and J. Galle, 1997. Use of HMG-CoA reductase inhibitors after kidney and heart transplantation: Lipid-lowering and immunosuppressive effects. *BioDrugs*, 8: 387-393.
- Yin, Y., K.L. Hawkins, W.C. de Wolf and A. Morgentaler, 1997. Heat stress causes testicular germ cell apoptosis in adult mice. *J. Androl.*, 18: 159-165.
- Yin, Y., W.C. de Wolf and A. Morgentaler, 1998. Experimental cryptorchidism induces testicular germ cell apoptosis by p53-dependent and -independent pathways in mice. *Biol. Reprod.*, 58: 492-496.
- Zhou, Z. and Y.J. Kang, 2000. Cellular and subcellular localization of catalase in the heart of transgenic mice. *J. Histochem. Cytochem.*, 48: 585-594.