

## Using Fetal-Heart Size Measured from Ultrasound Scanner Images to Estimate Age of Gestation in Goat

R.K. Raja Ili Airina, A.R. Mohd Nizam, R.B. Abdullah and W.E. Wan Khadijah  
Animal Biotechnology-Embryo Laboratory, Institute of Biological Sciences, Faculty of Science,  
University of Malaya, 50603 Kuala Lumpur, Malaysia

**Abstract:** The necessity in detecting pregnancy particularly estimating the gestation period in goat is undeniable. This objectives of this study were to observe images of fetus and fetal-related images in goats throughout pregnancy period, to test the reliability of fetal counting using Real-time B mode ultrasound, to measure and then to compare the development of fetal heart size in both single and twin pregnancies, to compare the changes in heart echogenicity in both single and twin pregnancies in does and to estimate the accuracy of pregnancy detection as well as age related pregnancy structures using ultrasonography. Structures were detected during gestation period including sac, fetus, fetal heart, amniotic fluid, uterine wall, ribs, spinal cord, fetal organ and placentomes. Changes in fetal heart echogenicity and area throughout both single and twin pregnancy were determined and evaluated using ultrasound scanning. Equations to estimate age of gestation were derived from polynomial and linear regression between gestational age and heart area in does for single and twin pregnancies. Blind test was conducted on polynomial and linear relationships between heart area size and gestational age. For polynomial relationship, 65, 69 and 92% of pregnant does delivered within  $\pm 1$ ,  $\pm 2$  and  $\pm 3$  weeks of the delivery dates, respectively. Meanwhile, linear relationship gave 62, 69 and 77%, respectively. In conclusion, sonographic fetometry of fetal heart size is reliable to estimate the age of gestation in goat.

**Key words:** Fetometry, gestation age, goat, ultrasound, fetal heart size, Malaysia

---

### INTRODUCTION

Pregnancy diagnosis is a useful tool in modern goat management especially when technologies such as artificial insemination and embryo transfer are employed. An early, reliable, non-invasive, fast, repeatable and reproducible method for immediate early diagnosis of pregnancy or non-pregnancy is essential for efficient reproductive management of a flock (Bretzlaff, 1993; Romano *et al.*, 1998a, b). The importance of detecting pregnancy in goat is undeniable. The early and precise detection of pregnancy is especially important from economic point of view that is it allows separation of the flock into pregnant and non-pregnant and thus it permits appropriate scheduling of breeding technologies (Yotov, 2005).

Ultrasonography has rapidly become established as one of the principle imaging techniques used in veterinary practice (Goddard, 1995). Real-time B-mode ultrasonography is an alternative for diagnosing pregnancy and studying the development of the conceptus in livestock (Suguna *et al.*, 2008). There are many reports regarding ultrasonography in sheep (Taverne *et al.*, 1985; Buckrell, 1988; Garcia *et al.*, 1993;

Kahn *et al.*, 1993; Schrick and Inskeep, 1993) but there is a paucity of information on the suitability of this technique for use in goats (Padilla-Rivas *et al.*, 2005). Nizam *et al.* (2009) described the characteristics of pregnancy-related structures during the various stages of pregnancy in Boer-crossbred does. There is little information on breed differences in regards to relationship between pregnancy-related structures and pregnancy age in goats. Fetal counting and its age at the respective time will enable improvement of feeding management and subsequently improve newborn survival. This will later lead to the rapid enhancement of breeding programme and goat production. Number of fetus may affect the accuracy for pregnancy diagnosis especially on gestational age estimation (Nizam *et al.*, 2009). Postmortem studies in ewes showed that there are minor small differences between single and twin pregnancies and they are only detectable at the end of gestation (Robinson *et al.*, 1977; McDonald *et al.*, 1978). On the contrary, some other researches using ultrasonography found no differences between single and twin pregnancy in ewes for any of pregnancy-related structures measurement (Kelly and Newnham, 1989; Sergeev *et al.*, 1990; De Bulnes *et al.*, 1998).

This study was carried out with the aims: to observe images of fetus and fetal-related images in goats throughout pregnancy, to test the reliability of fetal counting using Real-time B mode ultrasound, to measure and then to compare the development of fetal heart size in both single and twin pregnancies in Jermasia does, to evaluate and to compare the changes in heart echogenicity in both single and twin pregnancies in Jermasia does and to estimate the accuracy of pregnancy detection as well as age related pregnancy structures in different breeds of goat using ultrasonography.

## MATERIALS AND METHODS

**Experimental animals:** A total of 100 females consisting of Jermasia and Boer-crossbred does aged between 1-7 years old were used in experiment 1. Meanwhile, 8 Jermasia does were subjected to natural mating in experiment 2 and 105 does from Boer-crossbred and Katjang breed were used in experiment 3. The does were housed under intensive conditions and fed with 0.5 and 500 g doe<sup>-1</sup> of green fodder on daily basis. Water and salt licks were provided *ad libitum*.

**Ultrasound procedure:** Ultrasonography was conducted using a real-time B-mode scanner (ALOKA SSD 500, Aloka Co., Ltd., Japan) equipped with 7.5 MHz linear array transducer and/or 5.0 MHz convex transducer. For transrectal ultrasonography, the goats were restrained in a standing position followed by the insertion of the linear transducer, lubricated with carboxy methyl cellulose gel into the rectum until the bladder were displayed on the screen. Later, the uterine horns were observed cranial to the bladder and the transducer was rotated 90° clockwise and then 180° counter clockwise to image and visualise the entire reproductive tract (Martinez *et al.*, 1998). In conducting transabdominal ultrasonography, the abdominal part was shaved and later carboxy methyl cellulose gel was applied to the surface of convex transducer to eliminate the air spaces. Does were placed in a standing position and ultrasonographic examination was preferably done from the right side (as on left side, the filled rumen could impede proper observation of uterus) (Suguna *et al.*, 2008). Thereafter, the transducer was placed in the shaved area and slowly moved and rotated till the anechoic urinary bladder appeared.

**Ultrasound images:** All images recorded were printed using a thermal printer (Sony Corporation, Japan). When the images of were obtained from scanning, the pregnancy-related structures were identified and recorded as follows:

**Fetus:** Fetus was confirmed from heartbeat detection and its independent movement. Later, it was classified based on its visualisation on screen.

**Heart echogenicity:** The echogenicity of heart was classified into five groups based on colors; white, white-grey, grey, grey-black and black. The heart was confirmed by observation of rhythmic pulsation and thoracic area.

**Heart size:** Area of heart was measured by taking as oval shape as possible.

To minimize technical errors, heart area only was measured at a fixed and specific angle as well as fetal orientation.

## Experimental design

**Experiment 1:** Images of fetus and fetal-related structures were observed and recorded using 7.5 MHz transrectal and 5.0 MHz transabdominal probes. Scanning procedures were carried out on 100 does (natural mating and artificial insemination). Images showing different structures detected were used as indicators to confirm pregnancy in does. Gestation age was determined by retrospective counting from the delivery dates.

**Experiment 2:** The study was conducted on 8 does. All does were naturally mated with fertile male for 2 days upon natural estrus detection. The 1st day of the does exposed to male was designated as day 0 of gestation. Ultrasound scanning was conducted starting from day 21 post-mating (week 3 of gestation) and continued on weekly basis until delivery day (weeks 20-21 of gestation). Images of fetus and fetal-related structures were identified and number of fetus was estimated. In addition, size of fetal heart was measured and subsequently, equations for relationship between gestational age and fetal heart size were constructed.

**Experiment 3:** Flock test was conducted on 105 does with unknown mating dates. Each doe was tested on pregnancy status based on fetus and fetal-related structures obtained from experiment 1. Gestational age for each doe was determined using equations established from experiment 2. Actual delivery date for each pregnant doe was recorded and was compared with the estimated one.

## RESULTS AND DISCUSSION

**Experiment 1:** Out of 100 does used in this experiment, 63 does (63%) were detected pregnant after using both transrectal and transabdominal probes. Structures detected during the first trimester were sac (day 21) and

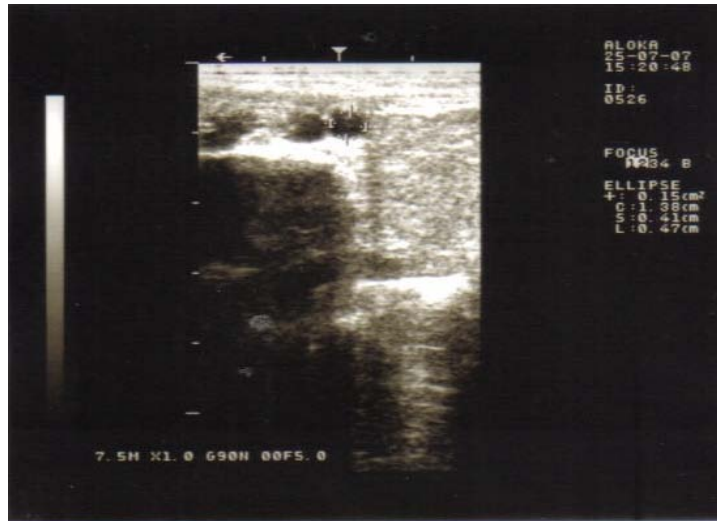


Fig. 1: Sac was detected on day 21 of gestation (first trimester)

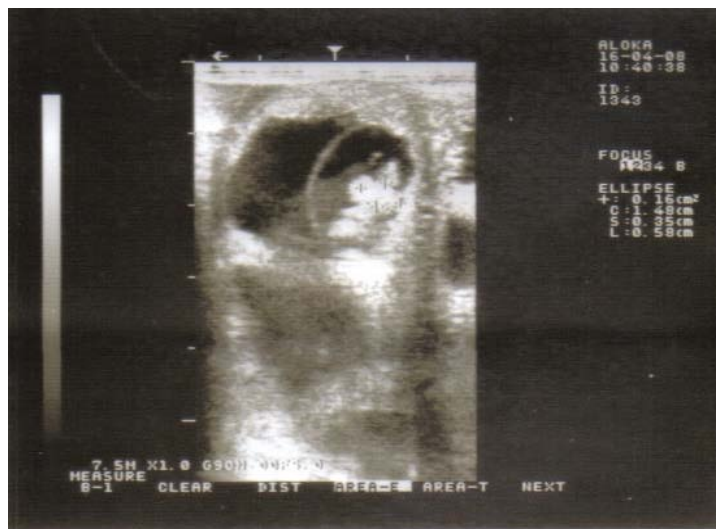

Fig. 2: Fetus with heartbeat and amniotic fluid were detected on day 33 of gestation (early stage)

fetus-fetal heart-amniotic fluid-uterine wall (day 33) (Fig. 1 and 2). During the second trimester, images of fetus-fetal heart, ribs-spinal cord, fetal organ-placentomes on days 63, 82 and 103 were observed (Fig. 3-5). However, only placentomes and fetal heart were easily identifiable during the third semester of pregnancy (day 121) (Fig. 6). Images of non-pregnant does were included as comparison (Fig. 7 and 8) (Table 1).

**Experiment 2:** Single (3/3; 100%) and twin pregnancies (5/5; 100%) were identified from the images obtained during pregnancy. Table 2 and 3 show the detectability of pregnancy-related structures throughout pregnancy using both transrectal and transabdominal probes,

respectively. Table 4 shows changes in fetal heart echogenicity and area in both single and twin pregnancies. During the fifth month of pregnancy (weeks 17-21), the colour image of fetal heart was observed as black with slow beating characteristic. Figure 9 shows fetal hearts at days 30, 56, 84, 119 and 140 of gestation. Figure 10 shows fixed fetal position for heart measurement to be made.

On week 8 of pregnancy and onwards, the heart showed definable shape with white-grey in colour. Hence, measurements of heart size were taken on weekly basis starting from week 8 of gestation up to the delivery date. Unfortunately, 2 does with single pregnancy were aborted during the gestation period. In both cases, measurements

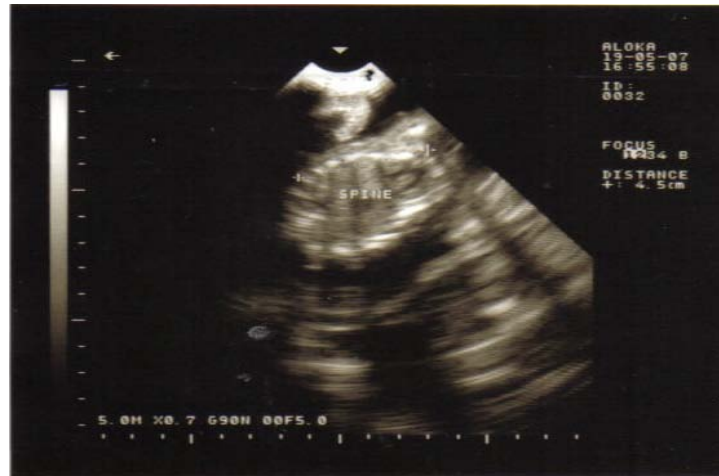

Fig. 3: Fetus and heartbeat were detected on day 82 of gestation (middle stage)

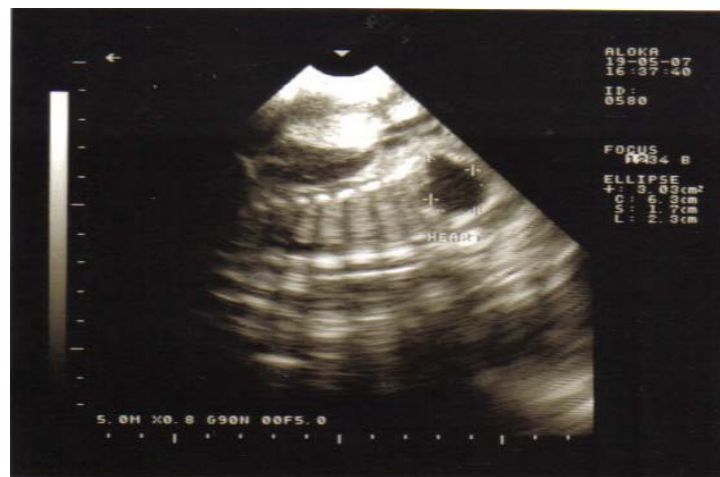

Fig. 4: Fetus with heartbeat and spinal cord were detected on day 63 of gestation (second trimester)

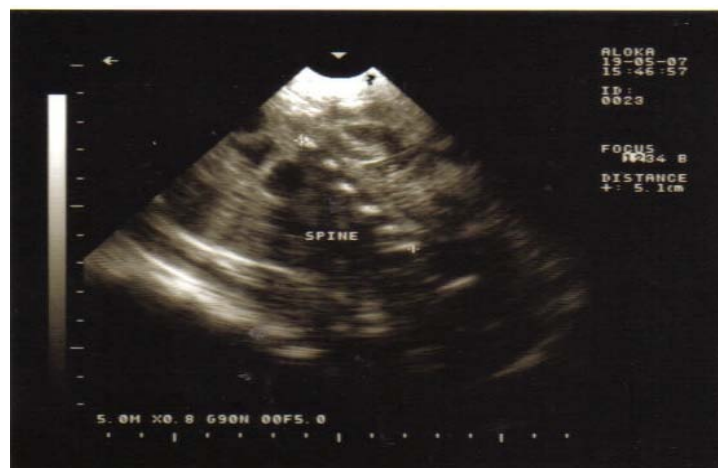

Fig. 5: Fetus with spinal cord, ribs and foetal organs were detected on day 103 of gestation (late stage)



**Table 1: Detected fetus and fetal-related structures using both probes in different range of gestation**

Structure	Detection time (days)	
	Transrectal probe	Transabdominal probe
Placentome	55-65	55-147
Fetal heart	28-43	52-147
Fetal head	-	70-120
Fetal organ	-	95-120

**Table 2: Measurability of pregnancy-related structures throughout pregnancy via transrectal procedure**

Pregnancy age (days)	Pregnancy-related structures													
	Embryonic sacs		Amniotic fluid		Crown rump length		Heart size		Heartbeat		Fetal-head diameter		Placentome diameter	
	DA	MA	DA	MA	DA	MA	DA	MA	DA	MA	DA	MA	DA	MA
21-28	+	+	+	+	+	+	-	-	-	-	-	-	-	-
29-35	+	+	+	+	+	+	+	-	+	-	-	-	-	-
36-42	+	+	+	+	+	+	+	-	+	-	+	+	+	+
43-49	-	-	-	-	-	-	+	-	+	-	+	+	+	+
50-56	-	-	-	-	-	-	+	+	+	+	+	+	+	+
57-63	-	-	-	-	-	-	+	+	+	+	+	+	+	+
64-70	-	-	-	-	-	-	+	+	+	+	+	+	+	+
71-77	-	-	-	-	-	-	-	-	-	-	-	-	+	+
78-84	-	-	-	-	-	-	-	-	-	-	-	-	+	+
85-91	-	-	-	-	-	-	-	-	-	-	-	-	+	+
92-98	-	-	-	-	-	-	-	-	-	-	-	-	+	+
99-105	-	-	-	-	-	-	-	-	-	-	-	-	+	+
106-112	-	-	-	-	-	-	-	-	-	-	-	-	+	+
113-119	-	-	-	-	-	-	-	-	-	-	-	-	+	+
120-126	-	-	-	-	-	-	-	-	-	-	-	-	+	+
127-133	-	-	-	-	-	-	-	-	-	-	-	-	+	+
134-140	-	-	-	-	-	-	-	-	-	-	-	-	+	+
141-147	-	-	-	-	-	-	-	-	-	-	-	-	+	+

**Table 3: Measurability of pregnancy-related structures throughout pregnancy via transabdominal procedure**

Pregnancy age (days)	Pregnancy related structures													
	Embryonic sacs		Amniotic fluid		Crown rump length		Heart size		Heart beat		Fetal-head diameter		Placentome diameter	
	DA	MA	DA	MA	DA	MA	DA	MA	DA	MA	DA	MA	DA	MA
21-28	-	-	-	-	+	-	-	-	-	-	-	-	-	-
29-35	+	+	+	+	+	+	-	-	+	-	-	-	-	-
36-42	+	+	+	+	+	+	-	-	+	-	-	-	+	+
43-49	+	+	+	+	+	+	-	-	+	-	+	+	+	+
50-56	+	-	+	-	-	-	+	+	+	-	+	+	+	+
57-63	+	-	+	-	-	-	+	+	+	-	+	+	+	+
64-70	+	-	+	-	-	-	+	+	+	-	+	+	+	+
71-77	+	-	+	-	-	-	+	+	+	-	+	+	+	+
78-84	+	-	+	-	-	-	+	+	+	-	+	+	+	+
85-91	+	-	+	-	-	-	+	+	+	-	+	+	+	+
92-98	+	-	+	-	-	-	+	+	+	-	+	-	+	+
99-105	+	-	+	-	-	-	+	+	+	-	+	-	+	+
106-112	+	-	+	-	-	-	+	+	+	-	+	-	+	+
113-119	+	-	+	-	-	-	+	+	+	-	+	-	+	+
120-126	+	-	+	-	-	-	+	+	+	-	+	-	+	+
127-133	+	-	+	-	-	-	+	+	+	-	+	-	+	+
134-140	+	-	+	-	-	-	+	+	+	-	+	-	+	+
141-147	+	-	+	-	-	-	+	+	+	-	+	-	+	+

+: Positive; -: Negative; DA: Detectable; MA: Measurable

were only taken up to the week before abortion. Data obtained (Table 4) shows that there is some difference in value of heart area for single and twin pregnancy throughout pregnancy.

However, from statistical analysis, the difference is not significant except for the 5th month (week 20th) of pregnancy. The equations derived for both single and twin pregnancy (Fig. 11-14) are as follows:

**Table 4: Changes in fetal heart echogenicity and area throughout both single and twin pregnancy**

Gestational age, X (weeks)	Heart colour	Heart size for single pregnancy (cm <sup>2</sup> )	Heart size for twin pregnancy (cm <sup>2</sup> )
<4	White	-	-
4<<8	White-grey	0.36±0.07 <sup>a,x</sup>	0.41±0.01 <sup>a,x</sup>
8<<12	Grey	2.33±0.43 <sup>a,x</sup>	2.30±0.32 <sup>a,x</sup>
12<<16	Grey-black	5.86±1.30 <sup>a,x</sup>	7.66±0.59 <sup>a,x</sup>
16<<21	Black	7.90±1.22 <sup>a,x</sup>	14.09±1.24 <sup>b,y</sup>

<sup>a, b</sup>Means with different superscripts in a row were significantly different (p<0.05); <sup>x, y</sup>Means with different superscripts in a column were significantly different (p<0.05)



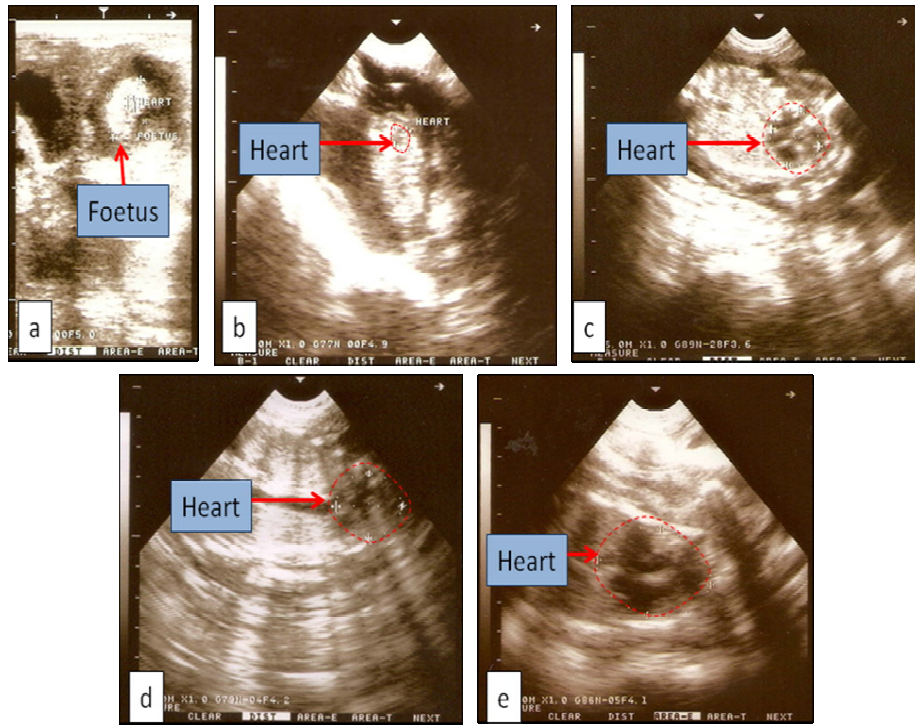


Fig. 9: Fetal hearts at the age of, a) 30 days; b) 56 days; c) 84 days; d) 119 days and e) 140 days (fetal heart area could not be measured in (a) however, heartbeat was detected)

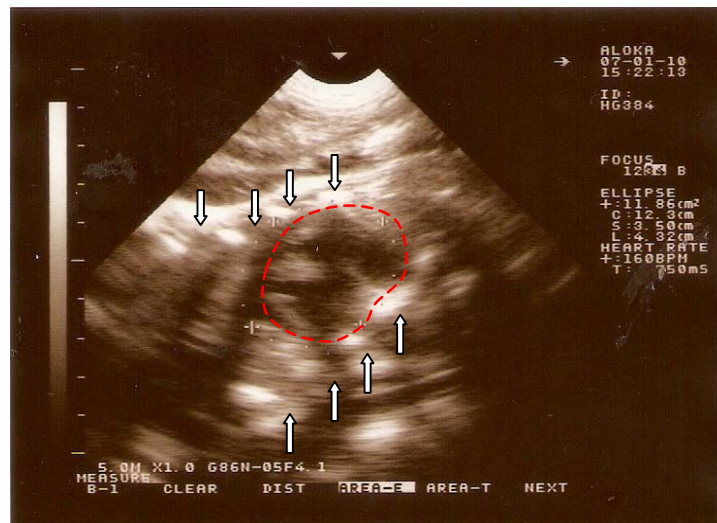


Fig. 10: Fixed fetal position for heart measurement to be made. Foetal Heart (H) appeared as non-echogenic structure between the white dots (arrows) which represent ribs

**Single pregnancy (polynomial regression):**

$$x = \frac{0.218 \pm \sqrt{(0.218)^2 - 4(0.032)(0.002 - y)}}{0.064}$$

Where:

x = Gestational age (weeks)

y = Heart size (cm<sup>2</sup>)

**Single pregnancy (Linear regression):**

$$x = \frac{(y + 5.987)}{0.704}$$

Where:

x = Gestational age (weeks)

y = Heart size (cm<sup>2</sup>)

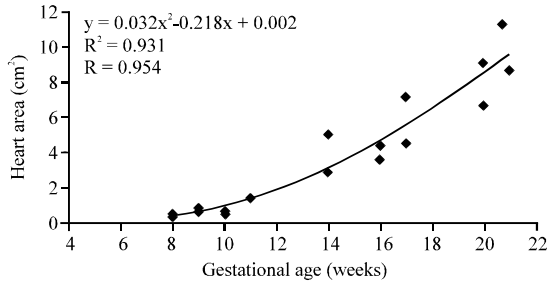


Fig. 11: Polynomial regression between gestational age and heart area in Jermasia does (single pregnancy)

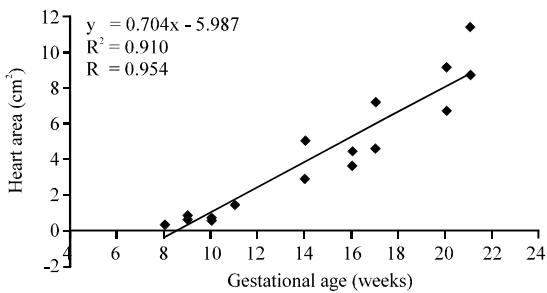


Fig. 12: Linear regression between gestational age and heart area in Jermasia does (single pregnancy)

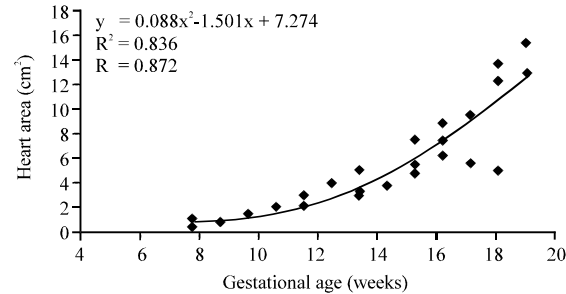


Fig. 13: Polynomial regression between heart area and gestational age in Jermasia does (twin pregnancy)

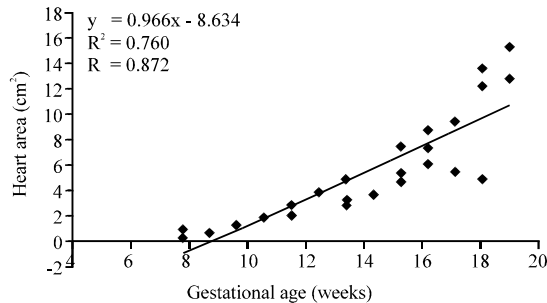


Fig. 14: Linear regression between heart area and gestational age in Jermasia does (twin pregnancy)

**Twin pregnancy (Polynomial regression):**

$$x = \frac{1.051 \pm \sqrt{(-1.051)^2 - 4(0.088)(7.274 - y)}}{0.176}$$

Where:

x = Gestational age (weeks)

y = Heart size (cm<sup>2</sup>)

**Twin pregnancy (Linear regression):**

$$x = (y + 8.634)/0.966$$

Where:

x = Gestational age (weeks)

y = Heart size (cm<sup>2</sup>)

Gestational age (x) is in the range as follows :  $0 < x \leq 21$

**Experiment 3:** The accuracy of ultrasound scanning in pregnancy diagnosis was 100% for both positive (22) and negative pregnancies (83). Animal was considered as pregnant when allantoic sacs (Fig. 15), pregnancy-related structures; placentome (Fig. 16) and fetal head (Fig. 17) were recognized. As for gestational age estimation, heart area was measured only when the foetus was in position as in Fig. 3.

Table 5-6 describe the results of blind test conducted on 26 does from different genotypes based on polynomial and linear relationships between heart area size and gestational age. For polynomial relationship, 65, 69 and 92% of pregnant does delivered within  $\pm 1$ ,  $\pm 2$  and  $\pm 3$  weeks of the delivery dates, respectively. Meanwhile, linear relationship gave 62, 69 and 77%, respectively.

**Observation on different foetal structures:** Different fetal related structures were observed during pregnancy. Such structures detected were fetal heart, ribs, spinal cord, fetal organ and placentomes. Structural images obtained in this experiment were similar with those images reported by Martinez *et al.* (1998), Medan *et al.* (2004) and Padilla-Rivas *et al.* (2005).

Detection of sac was observed on day 21 using transrectal probe. Medan *et al.* (2004) and Padilla-Rivas *et al.* (2005) detected a sac on days 22 and 21 of gestation, respectively. Embryonic vesicle was detected on days 17 and 21 by Karen *et al.* (2009) and Suguna *et al.* (2008), respectively.

Using transabdominal approach, Medan *et al.* (2004) observed spinal cord on day 60 of gestation. Suguna *et al.* (2008) reported detection on skeletal structures such as the skull, rib cage and vertebral column



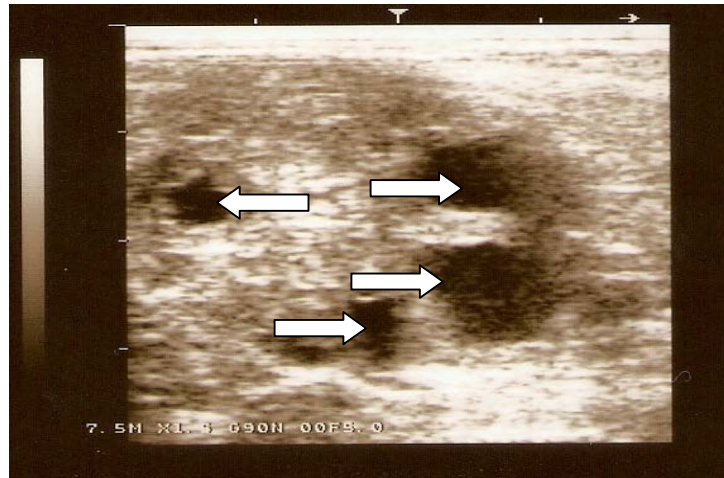


Fig. 15: Allantoic sacs (arrows)

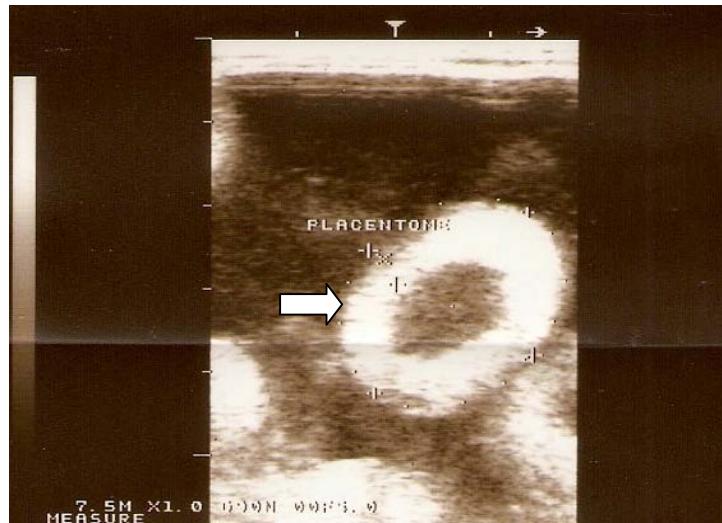

Fig. 16: Placentome (arrow)

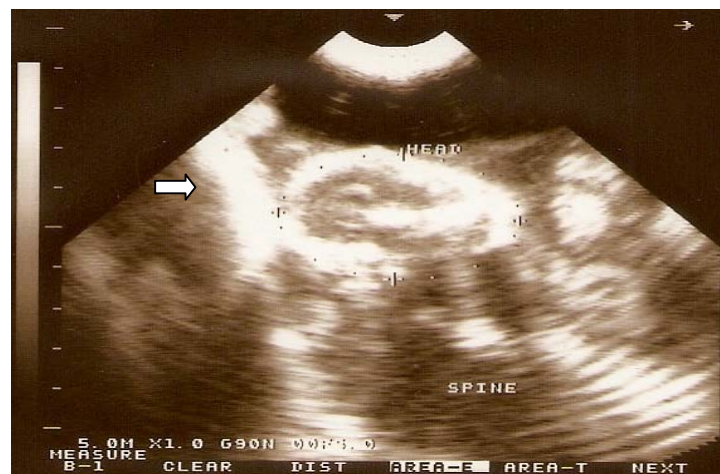

Fig. 17: Fetal head (arrow)

**Table 5: Accuracy of gestational age estimation based on polynomial regression equation for different genotypes of goats**

Genotypes	Total number confirmed pregnant (n)	Positive pregnancy accuracy (%)	Kidded within ±1 week expected date accuracy (%)	Kidded within ±3 weeks expected date accuracy (%)	Kidded within ±2 weeks expected date accuracy (%)
Boer-crossbred	15	100 (15/15*)	60 (9/15)	67 (10/15)	93 (14/15)
Katjang	7	100 (7/7)	86 (6/7)	86 (6/7)	100 (7/7)
Saanen	4	100 (4/4)	25 (1/4)	50 (2/4)	75 (3/4)
Overall accuracy	-	100 (26/26)	62 (16/26)	69 (18/26)	92 (24/26)

\*Number in brackets shows the number of positive pregnancy/total number of goats

**Table 6: Accuracy of gestational age estimation based on linear regression equation for different genotypes of goats**

Genotypes	Total number scanned	Positive pregnancy accuracy (%)	Kidded within ±1 week expected date accuracy (%)	Kidded within ±2 weeks expected date accuracy (%)	Kidded within ±3 weeks expected date accuracy (%)
Boer-crossbred	15	100 (15/15*)	60 (9/15)	73 (11/15)	80 (12/15)
Katjang	7	100 (7/7)	86 (6/7)	86 (6/7)	86 (6/7)
Saanen	100 (4/4)	100 (4/4)	25 (1/4)	25 (1/4)	50 (2/4)
Overall accuracy	-	100 (26/26)	62 (16/26)	69 (18/26)	77 (20/26)

\*Number in brackets shows the number of positive pregnancy/ total number of goats

on day 56 of gestation. In this research, ribs and spinal cord were observed as early as days 63-119 of gestation. In addition, fetal organs were detected on day 103 of gestation. Beyond this point, it was impossible to measure any of these structures as the images became distorted (Suguna *et al.*, 2008). In current research, only placentomes and fetal heart were detected for third semester of gestation.

Fetal heart and fetus were detected on days 21 (Martinez *et al.*, 1998; Suguna *et al.*, 2008), 23 (Padilla-Rivas *et al.*, 2005), 24 of pregnancy (Medan *et al.*, 2004). In the present experiment, fetal heart was detected on day 33 of gestation that is a few days after sac was observed using transrectal probe. Fetus with a beating heart was observed on days 22 and 28 by Karen *et al.* (2009) and Suguna *et al.* (2008), respectively. Throughout the three trimesters, detection of fetal heart was the most accessible and reliable for pregnancy confirmation because detection on fetal heart gave 100% accuracy on fetal viability as indicated by the results of the present study.

**Fetal counting:** From the results, it is suggested that Real-time B-mode ultrasound is a highly reliable means for pregnancy detection and fetal counting where 100% were correctly diagnosed for single and twin pregnancy. In current research, fetal counting was found to be possible conducted on day 35 of gestation together with the observation of first fetal independent movement. Fetal number was determined from the number of independent heartbeat detected.

From this experiment, fetal counting was possible up to weeks 7 and 10 of gestation using transrectal and transabdominal probes, respectively. This finding is in agreement with Suguna *et al.* (2008) who reported that weeks 5-7 was the best period for differentiation between singles and twins in goats. Dawson *et al.* (1994) reported that week 7 of gestation was more accurate than week 5

for the prediction of foetal numbers. After that, fetal counting was found to be difficult to be conducted due to the increase in fetal size. In other finding, Lavoit and Taverne (1989) suggested that the best period for counting fetal numbers in goats is between days 40 and 70 of gestation. Current results indicate that weeks 5-7 and weeks 5-10 to be the best period for the differentiation of singles and twins using transrectal and transabdominal probes, respectively which corroborates with the findings of other researchers as mentioned above. Determination of fetal number and viability is a clear advantage of real-time B-mode ultrasound over progesterone assay (Medan *et al.*, 2004).

**Estimation of gestational age using fetal heart structure:** Measurement of fetal heart area was taken at a fixed angle (Fig. 10) to minimize variation. Different angle would give different images of the pregnancy-related structures. This is supported by finding by Azevedo *et al.* (2009) who reported different accessibilities of fetal organ visualisation for fetal sexing from different planes of scanning suggesting that one specific angle is needed for one specific image visualisation. In addition, placentome also gives two different shapes when imaged from different angles; O-shaped when viewed in a longitudinal section or a regular C-shaped in cross section (Karen *et al.*, 2009). Hence, the need for certain angle of foetal heart imaging by ultrasound scanning is verified. B-mode ultrasound produces an accurate two-dimensional image of soft tissue cross section. The brightness of the dots on the oscilloscope is projected in various shades of gray, comparable to a black and white succession; they will reveal any motion in the tissue being imaged (Jainudeen and Hafez, 2000). Based on this principle, any specific structure and movement will be able to be measured and recorded. As found in current research, the change of heart colour (echogenicity) from white to black is presumably caused by the increasing amount of blood in the foetal heart making it less echodense.

Current research indicates that echogenicity of fetal heart changes as pregnancy progress become less echodense. This finding is in agreement with Medan *et al.* (2004) who reported that fetal heart appeared as non-echogenic structure at the age of 60 days. However, Suguna *et al.* (2008) reported that fetal heart appeared as echodense structure at day 120 of gestation. The difference between the findings is presumably caused by the angle the images were taken. Fetal images recorded in current research were taken in the same angle with Medan *et al.* (2004) but slightly different from the one taken by Suguna *et al.* (2008). Both images were recorded by 5.0 MHz sector array transducer but using different ultrasound machine model. The fetal orientation fixed in this experiment was the easiest to be accessed during pregnancy period with thoracic area and fetus heart as indication.

To the best of the knowledge, this research is the first to incorporate fetal heart size in estimating gestational age in does. Earlier studies focus on other fetal structures and pregnancy-related structures such as placentome (Haibel, 1990; Doize *et al.*, 1997; Medan *et al.*, 2004; Suguna *et al.*, 2008), fetal head (Haibel, 1988; Reichle and Haibel, 1991; Lee *et al.*, 2005) and fetal kidney (Ali and Hayder, 2007).

Two main limitations from the earlier studied pregnancy related structures used for gestational age estimation are their specificity and accessibility throughout gestation. For instance, fetal kidney and fetal head are specific and represent only one fetus but it only could be detected during a short time interval during pregnancy period.

On the contrary, placentomes can be easily detected throughout pregnancy. Unfortunately, it is not possible to measure the development of specific placentomes throughout pregnancy due to large number of them.

Pregnant goats, sheep and cattle have around 75-125 placentomes in total (Bowen, 2000). Even though several researchers reported high correlation between placentome diameter and gestational age (Doize *et al.*, 1997; Suguna *et al.*, 2008; Karen *et al.*, 2009) there still will be high chance for error when this approach to be performed for flock test in farm animals. Even though precaution has been made in earlier research to minimize error of which measurement were taken on 2-5 of representative placentomes (Doize *et al.*, 1997) there still will be high chance for error when it is practiced at farm level.

From current research, it was observed that placentomes are accessible throughout pregnancy starting from day 42 of gestation. However, newly formed placentomes which is smaller in size can be observed together with older and bigger placentomes. This smaller size placentomes might be accidentally taken for gestational age estimation when flock test for gestational age estimation is to be conducted. This will reduce the accuracy of gestational age from placentome diameter (Fig. 18).

Earlier studies have applied bi-parietal diameter for gestational age estimation. Bi-parietal diameter was found to show high correlation with gestational age (Haibel, 1988; Reichle and Haibel, 1991; Medan *et al.*, 2004; Lee *et al.*, 2005; Suguna *et al.*, 2008). However, one downside of this parameter is that it only can be observed up to from the middle of first trimester to the end of the second trimester of pregnancy. After this timeframe, it was

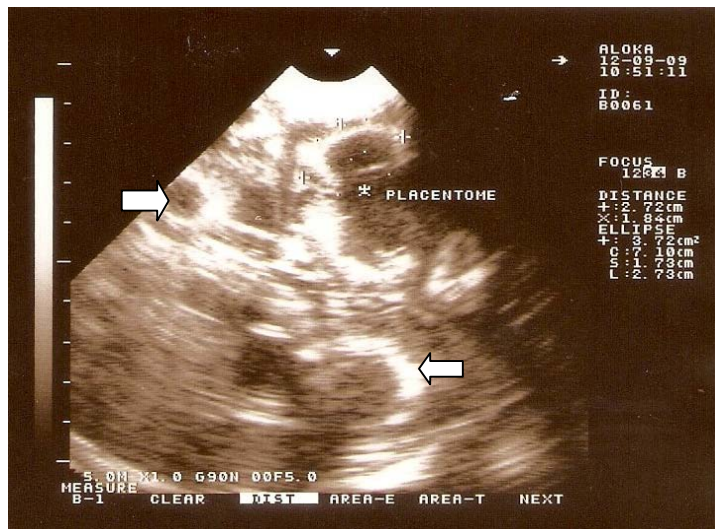

Fig. 18: Smaller size placentomes (arrow: →) was detected with placentome which is way bigger than it size (arrow: ←)

difficult to visualize the fetal head due to the rapid increase in size. Current finding is in agreement with Reichle and Haibel (1991) and Karen *et al.* (2009) who detected fetal head from approximately days 30-100 of gestation. Meanwhile, Suguna *et al.* (2008) reported that fetal head can be observed from days 56-98 and 56-130, respectively using transrectal and transabdominal probes. The current study is the first that incorporate heart area size as a biometric index estimating gestational age in does. Figure 9 shows the development of fetal heart size throughout pregnancy. The graph plotted shows polynomial function as observed on the rapid development of heart size starting from the 2nd month of pregnancy suggesting that this criterion is a reliable indicator for pregnancy age during that period. Each graph shows polynomial and linear relationship based on data obtained from Jermasia breed. The value of coefficient of determination  $R^2$  in polynomial regression in Jermasia ( $R^2 = 0.931$ ) was found to be slightly higher than those in linear regression ( $R^2 = 0.910$ ). The polynomial growth pattern of the fetal heart during pregnancy may be the cause for this difference. Similar difference is shown in twin pregnancy as well (polynomial vs. linear;  $R^2 = 0.836$  and  $R^2 = 0.760$ , respectively).

Current research shows that polynomial relationship between heart area size and gestational age gives higher accuracy as compared to linear relationship; maximum accuracy = 92% and 77% within  $\pm 3$  weeks of estimated date, respectively. This finding is supported by the actual polynomial pattern showed by foetal heart throughout pregnancy (Fig. 3-4). As explained earlier, no previous literature has been found on fetal heart size development thus it is believed that current research is the first to evaluate this new aspect of pregnancy-related structure. In reference to breed difference, Boer-crossbred and Katjang does give high maximum accuracy when the polynomial equation was applied 93 and 100%, respectively. In addition, linear regression as well gave high accuracy 80 and 86%, respectively. This finding indicates the suitability and reliability of the equation on Boer-crossbred and Katjang does. However, the equations were found to show lower accuracy when applied on Saanen does (polynomial vs. linear relationship: 75 vs. 50%). The difference number of does tested for each breed might influence the variation. Nevertheless, earlier research studies suggested a specific predicting chart for each goat breed (Haibel, 1990; Karen *et al.*, 2009). Present study has successfully identified fetal heart as a reliable indicator for gestational age estimation. It is found that polynomial relationship between fetal heart area size and gestational age give acceptable accuracy when tested on flock from different goat genotypes, gestational age and farm management.

Moreover as discussed earlier, fetal heart was found to be less echogenic as pregnancy advances. This visible change in heart colour (white to black) will complement in more accurate estimation. In comparison with placentome diameter, study of fetal heart is more reliable owing to its specificity; only one heart for one fetus but 75-125 placentomes within one pregnancy (Bowen, 2000).

One difficulty faced during the study was the availability for does to undergone breeding programme for weekly data collection (experiment 3). Therefore, in future research, it is highly suggested that more does to be used to solidify the relationship between the parameters. Besides that it is believed that correlation between fetal heart area, fetal heartbeat rate, kid's birth weight and gestational age will lead to breakthrough finding in future research.

## CONCLUSION

In this study, it is found that sonographic fetometry of fetal heart size is valuable for the evaluation of fetal development. Confirmation of fetal number, fetal viability and fetal age are the obvious advantages of fetal heart evaluation as compared to other pregnancy-related structures.

## REFERENCES

- Ali, A. and M. Hayder, 2007. Ultrasonographic assessment of embryonic, fetal and placental development in Ossimi sheep. *Small Rumin. Res.*, 73: 277-282.
- Azevedo, E.M.P., C.R.A. Filho, L.M.F. Neto, R.T.D. Moura and E.R. Santos Jr., *et al.*, 2009. Ultrasonographic scan planes for sexing ovine and caprine fetuses. *Med. Vet.*, 3: 21-29.
- Bowen, R., 2000. Placentation in ruminants. <http://www.vivo.colostate.edu/hbooks/pathphys/reprod/placenta/ruminants.html>.
- Bretzlaff, K.N., 1993. Development of hydrometra in a ewe flock after ultrasonography for determination of pregnancy. *J. Am. Vet. Med. Assoc.*, 203: 122-125.
- Buckrell, B.C., 1988. Applications of ultrasonography in reproduction in sheep and goats. *Theriogenology*, 29: 71-84.
- Dawson, L.J., T. Sahlh, S.P. Hart, G. Detweiler and T.A. Gipson *et al.*, 1994. Determination of fetal numbers in Alpine does by real-time ultrasonography. *Small Rumin. Res.*, 14: 225-231.
- De Bulnes A.G., J.S. Moreno and A.L. Sebastian, 1998. Estimation of fetal development in Manchega dairy ewes by transrectal ultrasonographic measurements. *Small Rumin. Res.*, 27: 243-250.

- Doize, F., D. Vaillancourt, H. Carabin and D. Belanger, 1997. Determination of gestational age in sheep and goats using trans-rectal ultrasonographic measurement of placentomes. *Theriogenology*, 48: 449-460.
- Garcia, A., M.K. Neary, G.R. Kelly and R.A. Pierson, 1993. Accuracy of ultrasonography in early pregnancy diagnosis in the ewe. *Theriogenology*, 39: 847-861.
- Goddard, P.J., 1995. *Veterinary Ultrasonography*. CAB International, Wallingford, Oxon.
- Haibel, G.K., 1988. Real-time ultrasonic fetal head measurement and gestational age in dairy goats. *Theriogenology*, 30: 1053-1057.
- Haibel, G.K., 1990. Use of Ultrasonography in Reproductive Management of Sheep and Goat Herds. In: *Advances in Sheep and Goat Medicine. The Veterinary Clinics of North America Food Animal Practice*, Smith, M.C. (Ed.). Vol. 6, W.B. Saunders, Philadelphia, pp: 597-613.
- Jainudeen, M.R. and E.S.E. Hafez, 2000. Gestation, Prenatal Physiology and Parturition. In: *Reproduction in Farm Animals*, Hafez, E.S.E. and B. Hafez (Eds.). 7th Edn., Lippincott Williams and Wilkins, Philadelphia, pp: 140-155.
- Kahn, W., J. Achtzehn, B. Kahn, A. Richter, J. Schulz and M. Wolf, 1993. Sonography of pregnancy in sheep. II. Accuracy of transrectal and transcutaneous pregnancy diagnosis. *Dtsch. Tieraerztl. Wschr.*, 100: 29-31.
- Karen, A.M., E.S.M. Fattouha and S.S. Abu-Zeid, 2009. Estimation of gestational age in Egyptian native goats by ultrasonographic fetometry. *Anim. Reprod. Sci.*, 114: 167-174.
- Kelly, R.W. and J.P. Newnham, 1989. Estimation of gestational age in Merino ewes by ultrasound measurement of fetal head size. *Aust. J. Agric. Res.*, 40: 1293-1299.
- Lavoit, M.C. and M.A.M. Taverne, 1989. The Diagnosis of Pregnancy and Pseudopregnancy and the Determination of Foetal Number in Goats, by Means of Real-Time Ultrasound Scanning. In: *Diagnostic Ultrasound and Animal Reproduction*, Taverne, M.M. and A.H. Willems (Eds.). Kluwer Academic Publisher, Dordrecht, pp: 89-96.
- Lee, Y., O. Lee, J. Cho, H. Shin and Y. Choi, 2005. Ultrasonic measurement of fetal parameters for estimation of gestational age in Korean black goats. *J. Vet. Med. Sci.*, 67: 497-502.
- Martinez, M.Z., P. Bosch and R.A. Bosch, 1998. Determination of early pregnancy and embryonic growth in goats by transrectal ultrasound scanning. *Theriogenology*, 49: 1555-1565.
- McDonald, Y., G. Wenham and J.J. Robinson, 1978. Studies on reproduction in prolific ewes. III. The development in size and shape on the foetal skeleton. *J. Agric. Sci. Cambridge*, 89: 375-391.
- Medan, M., G. Watanabe, G. Absy, K. Sasaki, S. Sharawy and K. Taya, 2004. Early pregnancy diagnosis by means of ultrasonography as a method of improving reproductive efficiency in goats. *J. Reprod. Dev.*, 50: 391-397.
- Nizam, M.A.R., W.E.W. Khadijah and R.B. Abdullah, 2009. Accuracy of ultrasonographic assessment pregnancy related structures in Boer does. *Proceedings of the International Conference on Animal Health and Human Safety*, Dec. 6-8, Palm Garden Hotel, IOI Resort, Selangor, pp: 310-311.
- Padilla-Rivas, G.R., B. Sohnrey and W. Holtz, 2005. Early pregnancy detection by real-time ultrasonography in Boer goats. *Small Rumin. Res.*, 58: 87-92.
- Reichle, J.K. and G.K. Haibel, 1991. Ultrasonic biparietal diameter of second trimester Pygmy goat fetuses. *Theriogenology*, 35: 689-694.
- Robinson, J.J., I. McDonald, C. Fraser and R.M.J. Crofts, 1977. Studies on reproduction in prolific ewes. 1. Growth of the products of conception. *J. Agric. Sci.*, 88: 539-552.
- Romano, J.E., C.J. Christians and B.G. Crabo, 1998a. Applications of transrectal ultrasonography in ewe reproduction. 1998 Minnesota Sheep Research Report, Dept. of Animal Science, Univ. of Minnesota, St. Paul, MN, pp: 81-82.
- Romano, J.E., C.J. Christians and B.G. Crabo, 1998b. Early pregnancy detection by transrectal ultrasonography in Suffolk Ewes. 1998 Minnesota Sheep Research Report, Dept. of Animal Science, Univ. of Minnesota, St. Paul, MN, pp: 83-86.
- Schrack, F.N. and E.K. Inskeep, 1993. Determination of early pregnancy in ewes utilizing transrectal ultrasonography. *Theriogenology*, 40: 295-306.
- Sergeev, L., D.O. Kleemann, S.K. Walker, D.H. Smith, T.I. Grosser, T. Mann and R.F. Seamark, 1990. Real-time ultrasound imaging for prediction ovine fetal age. *Theriogenology*, 34: 593-601.
- Suguna, K., S. Mehrotra, S.K. Agarwal, M. Hoque, S.K. Singh, U. Shanker and T. Sarath, 2008. Early pregnancy diagnosis and embryonic and fetal development using real time B mode ultrasound in goats. *Small Rumin. Res.*, 80: 80-86.
- Taverne, M.A., M.C. Lavoit, R. van Oord, G.C. van der Weyden, 1985. Accuracy of pregnancy diagnosis and prediction of foetal numbers in sheep with linear-array real-time ultrasound scanning. *Vet. Q.*, 7: 256-263.
- Yotov, S., 2005. Diagnostics of early pregnancy in Stara Zagora dairy sheep breed. *Bulgarian J. Vet. Med.*, 8: 41-45.