

## Report of *Physaloptera praeputialis* (Von Linstow 1889, Nematoda) in Mountain Lion (*Puma concolor*, Linnaeus 1771)

<sup>1</sup>J.H. Martinez Guerrero, <sup>1</sup>M.E. Pereda Solis, <sup>2</sup>J.J. Zarate Ramos,  
<sup>1</sup>F. Rosales Alferez and <sup>1</sup>H. Herrera Casio

<sup>1</sup>Facultad de Medicina Veterinaria, Zootecnia de la Universidad,  
Juarez del Estado de Durango, Durango, Dgo. 34000, Mexico

<sup>2</sup>Facultad de Medicina Veterinaria and Zootecnia,  
Universidad Autonoma de Nuevo Leon, Monterrey, Nuevo Leon, Mexico

---

**Abstract:** We recovered five adult individuals and various eggs of the gastric parasite *Physaloptera praeputialis* in a wild mountain lion that was living in the Mapimi Biosphere Reserve in the state of Durango, Mexico. The adult nematodes were whitish-pink in color, between 25 and 34 mm in length and 0.8 mm in diameter with an extension of the cuticle similar to a prepuce on the anterior extreme of the body and a bilabiate head. All of these characteristics align with the description of the order Spirurida. The eggs were between 45 and 58 µm in length and 30-42 µm in width, which is consistent with the descriptions of Bowman. Although, it is possible to find pathological effects of these parasites in their hosts, the necropsy did not reveal any damage that would compromise the health of the puma.

**Key words:** *Physaloptera praeputialis*, mountain lion, *Puma concolor*, gastric parasites, eggs

---

### INTRODUCTION

Parasitism is one of the most prevalent ecological relationships in nature. In Mexico, the study of parasites of wildlife is limited. The host-parasite relationship has various pathological consequences but it is especially interesting in wildlife at the top of the food chain. Numerous findings and reports of parasites in these species come from hunters who see these animals as threats to cattle and subsequently kill them legally or illegally (Shaw, 1977). The mountain lion (*Puma concolor*, also known as puma, panther, cougar, catamount or mountain cat) has the most expansive range of any mammal in the western hemisphere (Cougar Discussion Group, 1999). This distribution means that the puma has a wide array of prey but it generally takes old and/or sick animals (Russell, 1978).

Deising began the study of parasites of *Puma* at the beginning of the 19th century with individuals collected in Brasil (Raush *et al.*, 1983), where gastrointestinal helminthes are the parasites of greatest diversity and importance. *Physaloptera praeputialis* is a gastrointestinal nematode with an indirect life cycle that has been reported in domestic and wild felines and canines throughout the world and is a very common gastric parasite of cats (Naem *et al.*, 2006). The various pathological effects of

this parasite on its hosts include gastritis, ulcers, edema and anorexia, among others (Clark, 1990; Jones, 1995).

### MATERIALS AND METHODS

The body of an adult male mountain lion was recovered from a trap that had been set by cattle ranchers outside of the Mapimi Biosphere Reserve (RBM) in the state of Durango, Mexico. We performed the necropsy at the RBM's Desert laboratory (Fig. 1), located at 26°41'10.29"N and 103°44'50.91"W in the Chihuahuan Desert. We found the parasites in the puma's stomach, washed them in a physiological solution and deposited them in a container of lactophenol (Coffin, 1953) to better view their structures and therefore identify them, with aid of a 40x optical microscope. We followed Olsen (1974)'s technique to identify the adult parasites, one of which we macerated with mortar and pestle to be able to view eggs under the microscope (to which we attached a MotiCam® video recorder).

### RESULTS AND DISCUSSION

We recovered five adult nematodes from the lion's stomach, in which we found small, diffuse hemorrhages in the stomach lining.

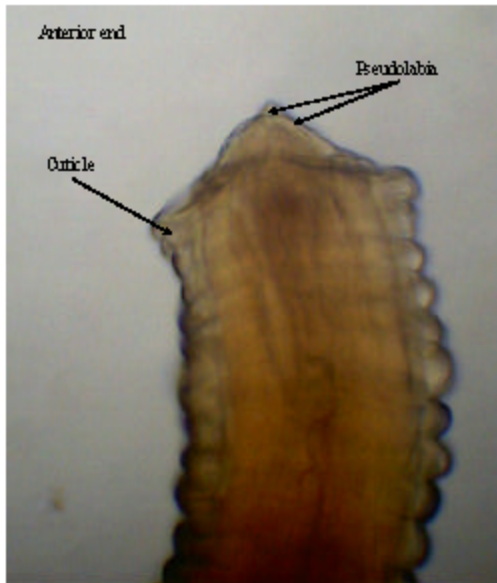


Fig 1: Anterior end of *Physaloptera praeputialis* (Moticam, 10X)

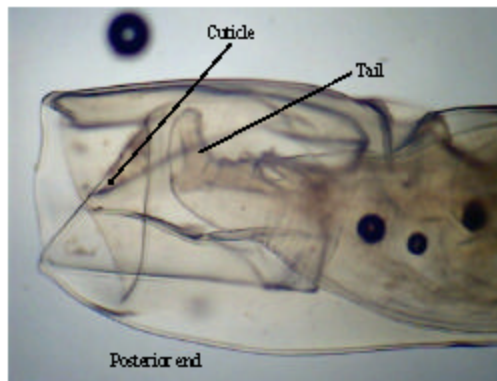


Fig. 2: Posterior end of *Physaloptera praeputialis* (Moticam 10X)

The classification of the parasites follows (Olsen, 1974):

Class: *Secernentea*  
Order: *Spirurida*  
Family: *Physalopteridae* Falliet, 1893  
Genus: *Physaloptera* Rudolphi, 1819  
Species: *Physaloptera praeputialis* von Linstow, 1889

The nematodes were whitish pink in color with lengths between 25 and 34 mm, a diameter of 0.8 mm, an extension of the cuticle similar to a prepuce on the anterior extreme of the body (Fig 1) and a bilabiate head characteristics of the order Spirurida (Cordero *et al.*, 2000). Figure 2 shows the cuticular extension that covers the

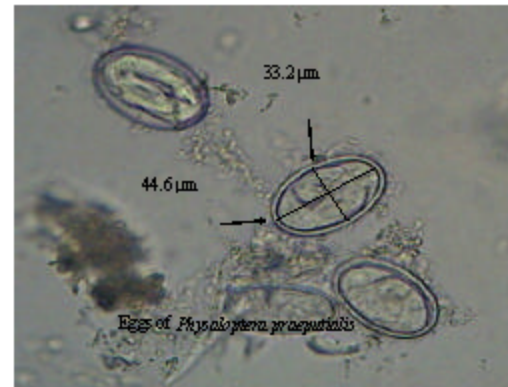

Fig 3: Eggs of *Physaloptera praeputialis* (Moticam 10X)

tail of individuals of both sexes (Bowman *et al.*, 2003). The eggs (Fig 3) were between 45 and 58  $\mu\text{m}$  in length and 30-42  $\mu\text{m}$  in width, which is consistent with the descriptions of Bowman *et al.* (2003).

## CONCLUSION

We identified the presence of *Physaloptera praeputialis* in a wild mountain lion from the Mapimí Biosphere Reserve in the state of Durango, Mexico. This nematode, which has an indirect life cycle, has been reported in wild felines and canines. Although, it is possible to find pathological effects of these parasites in their hosts, the necropsy did not reveal any damage that would suggest danger to the individual.

## REFERENCES

- Bowman, D.D., S.C. Barr, C.M. Hendrix and D.S. Lindsay, 2003. *Gastrointestinal Parasites of the Cat Companion and Exotic Animal Parasitology*. International Veterinary Information Service, Ithaca, New York.
- Clark, J.A., 1990. *Physaloptera*, stomach worms associated with chronic vomiting in a dog in Western Canada. *Can. Vet. J.*, 31: 840-840.
- Coffin, D.L., 1953. *Manual of Veterinary Clinical Pathology*. 3rd Edn., Comstock Publishing Associates, Ithaca, NY., USA., pp: 19-65.
- Cordero, C., F.A. Rojo, A.R. Martínez, C. Sánchez and S. Hernández *et al.*, 2000. *Parasitología Veterinaria*. McGraw-Hill Interamericana, Madrid, Espana, ISBN: 84-486-0236-6, pp: 113-123.
- Cougar Discussion Group, 1999. *Utah Cougar Management Plan*. Utah Division of Wildlife Resources, Salt Lake, Utah, pp: 2-5.

- Jones, H.I., 1995. Pathology associated with physalopterid larvae (Nematoda: Spiruridia) in the gastric tissue of Australian reptiles. *J. Wildlife Dis.*, 31: 299-306.
- Naem, S., A. Farshid and V. Marand, 2006. Pathological findings on natural infections with *Physaloptera praeputialis* in cats. *Vet. Arhiv*, 76: 315-321.
- Olsen, W.O., 1974. *Animal Parasites: Their Life Cycle and Ecology*. University Park Press, Baltimore, Maryland, ISBN: 0-486-65126-6, pp: 562.
- Raush, L.R., C. Maser and E.P. Hober, 1983. Gastrointestinal helminths of the Cougar *Felis concolor*, in Northeastern Oregon. *J. Wildlife Dis.*, 19: 14-19.
- Russell, K.R., 1978. Mountain Lion. In: *Big Game of North America* (A Wildlife Management Institute Book), Gilbert, D. (Ed.). Gazelle Book Services Ltd., Harrisburg, PA., ISBN: 10:0811702448, pp: 499.
- Shaw, H.G., 1977. Impact of mountain lion on mule deer and cattle in Northwestern Arizona. *Proceedings of the 1975 Predator Symposium*, June 16-19, Missoula, Montana, pp: 17-32.