

Laparoscopic Partial Hepatectomy by Using Horizontal Interrupted Mattress Suture in Goats

M.J. Eesa

Department of Surgery and Obstetric, College of Veterinary Medicine, Baghdad University, Iraq

Abstract: This study was designed to evaluate the feasibility of laparoscopic partial hepatectomy by using the intracorporeal horizontal interrupted mattress suture technique. Ten Black Iraqi local old goats of both sexes were used. Animals divided into two equal groups. Laparoscopic partial hepatectomy were performed in both groups comparing horizontal interrupted mattress suture by using polygalactine synthesis absorbable suture material, to suture around the resected part as a triangular in shape. Then resected this a triangular area and without approximate of resected edge in group, A. While the same method in group B but with approximation of the resected edge by simple interrupted suture pattern. The animals were inspected laparoscopically, one month post operation, which revealed that the regeneration of the resected site was better in group, B compared with group, A. In addition to that the adhesion of the resected site with adjacent structures were slight in degree in group, B than in group, A. This technique of intracorporeal horizontal interrupted mattress suture provides to be feasible and can be used in laparoscopic partial liver resection of the peripheral abnormal lesion.

Key words: Liver, minimally invasive surgery, laparoscopy, laparoscopic partial liver resection, liver suture, horizontal interrupted mattress suture

INTRODUCTION

The application of laparoscopy to hepatectomy has been slowed, because of technical difficulties such as homeostasis from the transection plane, controlling hemorrhage from intrahepatic vessels and exploration of deep regions. The first laparoscopic anatomic liver resection was reported by Azagra *et al.* (1996). Wedge resection is not as problematic as regard bleeding because of an improvement in homeostasis devices such as the ultrasonic dissector for small vein and the argon beam coagulator and/or fibrin glue sealant for parenchymal tissue (Ueda *et al.*, 2004). Since this time, the improvements in laparoscopic devices have significantly extended the surgeons ability to perform these procedure safely, as a reflection in publications (Koffron *et al.*, 2006). However, the continuing evolution of a variety of laparoscopic instrument and device has been gradually applied to the laparoscopic hepatectomy in many countries (Kaneko *et al.*, 2008). Also, water jet dissection technique is safe, feasible and can be used in open and in laparoscopic liver resection (Rau *et al.*, 2008). For safe laparoscopic hepatectomy, it is important to have all necessary equipment. The intraoperative laparoscopic ultra sonography, microwave coagulators, ultrasonic dissection, argon beam coagulators, laparoscopic

coagulation shear (Harmonic scalpel), endoliner staplers and tissue link monopolar sealer are essential (Kaneko *et al.*, 2008). Once resection is started from the liver surface, exposed small vessels and biliary structure <2 mm in diameter are coagulated with laparoscopic coagulating shear or ultrasonic surgical system (Kaneko *et al.*, 2008). While, bleeding from larger vessels can usually be managed by clip application or intracorporeal suturing (Montorsi *et al.*, 2002). The majority of clinicians use CO₂ pneumoperitoneum, but others prefer the abdominal wall lift method, especially during parenchymal transection given the potential risk for CO₂ embolism (Kaneko, 2005). From available literatures, it was observed that no laparoscopic partial liver resection has been reported by using suture technique.

Therefore, the aim of the present study was to investigate the ability of intracorporeal horizontal interrupted mattress sutured technique for laparoscopic partial hepatectomy in goats.

MATERIALS AND METHODS

Ten Black Iraqi local goats of both sexes aged 2.0-4.5 years and their body weight ranged 26-45 kg were used. The animals were kept in Animal Farm College of Veterinary Medicine. Animals were randomized into two equal groups (A and B). Group A were used for

laparoscopic liver partial resection by using intracorporeal horizontal interrupted mattress suture around the resected part, while group B were used to the same above method as in group A, but after resection was sutured the resected edge by simple interrupted suture technique. Preoperatively, the animals were fasted for 36 h for feeding and 12 h for watering. Abdominal area in between xiphoid cartilage and pubis was prepared aseptically. The animals were given thiopentone sodium 5% (25 mg kg⁻¹ B.W) intravenously in order to intubate and the anesthesia was maintained by halothane and oxygen (McEwen *et al.*, 2000). The operation was performed with animal in supine position. Canulation was applied for fluid therapy. The pneumoperitoneum CO₂ was insufflated by Veress needle and maintained at constant abdominal pressure at 12 mm Hg. Four ports were used during the course of the procedure, a 10 mm trocar was placed at umbilicus for camera, 5 mm trocar in mid-line near the xiphoid cartilage and 10 mm trocar on the right side at the level of camera port and the last port in mid space, between the camera and the right side ports, but slight up of the line which connected between its (Fig. 1). The last three ports were used to introduce all laparoscopic instruments, such as needle holder, grasper, scissor, suction and irrigation.

Group A: Laparoscope was introduced through 10 mm umbilicus trocar following a diagnostic overview of the abdominal cavity, three additional working trocars were introduced, through the three sites mentioned above under direct vision. The left hepatic lobe was identified for partial resection. Three stitch's of horizontal interrupted mattress suture were applied on each side of the resected

part using polygalactine (synthetic absorbable suture material size (0)) suture material (Fig. 2a-f). Then, the area in between two suture lines was cutting by scissor at the distance for about half cm from the line of suture (Fig. 3g-k). If minimal bleeding occurred after resection, holding the omentum by grasper and pressure on bleeding site for about 2-3 min and aspiration of blood clot in order to visualize the surgical site. Extraction of the resected part was achieved by extending the 10 mm port at the right side. The ports were removed and the incision closed as a routine manner. The animals were stopped



Fig. 1: Typical: 4-ports placement for laparoscopic partial liver resection. The animal in supine position. The specimen was extracted through port 3. 1): 10 mm umbilicus port for laparoscope, 2): 5 mm right hand working port (surgeon), 3): 10 mm port for left lobe grasper (assistant surgeon) and 4): 5 mm left hand working port (surgeon)

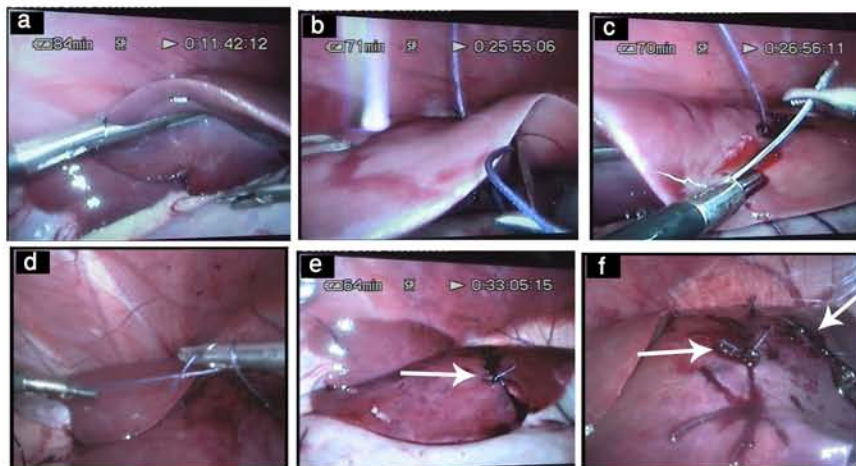


Fig. 2: Laparoscopic of the abdomen showing the: a) proper grasper of the left lobe for application of intracorporeal suture, b-e (one stitch) "arrow" and f) "arrow": show application of two row of horizontal interrupted mattress suture around the triangular resected site

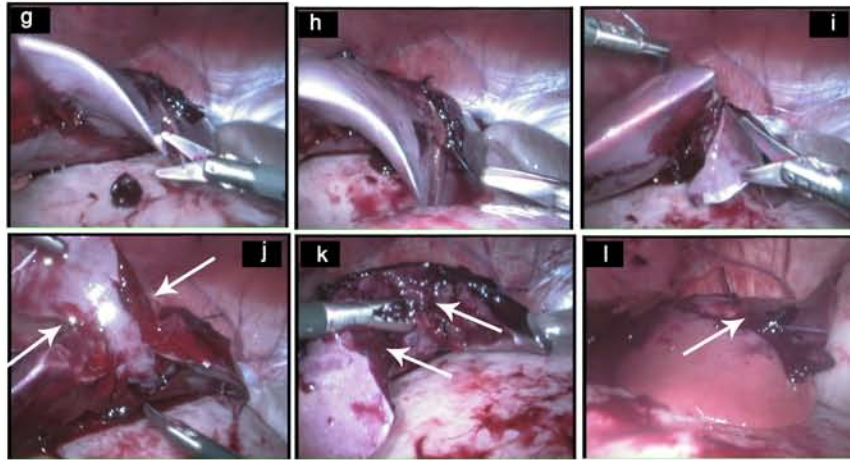


Fig. 3: Laparoscopic of the abdomen showing the: g-j) Liver parenchymal resected by use scissor, cut in between two row of the suture j "arrow", k) Complete resected of the triangular area, "arrow" represent group (A), l) Approximate of the resected edge by simple interrupted suture "arrow" represent group (B)

from anesthesia and extubated after pharyngeal reflex observe. The animals were examined laparoscopically after one month post operation to show the degree of regeneration of hepatic resected area and any other complications, which may occurred on the surgical site. Penicillin-streptomycin at a dose of 10,000 IU, 20 mg kg⁻¹ B.W. intramuscular, respectively, for 4 days post-operation were used. Skin suture was removed after 10 days post-operation.

Group B: The operative laparoscopic procedures for partial hepatic resection was the same as describe for group A. Except that after partial hepatic resection were achieved, the resected edge was approximated by simple interrupted suture pattern, using the same thread shown in Fig. 3l.

RESULTS AND DISCUSSION

The results of this study showed that the intraoperative homeostasis was achieved by application of a horizontal interrupted mattress suture. The operative time was in between 90-120 min and blood loss during the intervention was no serious and not measured. Nine cases were performed successfully, while one case in group A died. Laparoscopic animals were responsive, alert and feeding 2 h after recovery from anesthesia. In group B laparoscopic examination were performed one month postoperatively showed good regeneration of the resected site, with slight degree of simple adhesion in between resected site, omentum, diaphragm and omasum. The regeneration of the resected site was appeared similar to the irregular line (Fig. 4o). While in group A, the

regeneration of the resected site was appeared similar to the notch (Fig. 4m) and there was adhesion between resected site and other adjacent organs (Fig. 4n), which are more severe when compared with in group B. No clinically gas embolism was occurred.

Liver surgery has several problems in comparison to that of other organs. The major problem in liver resection is the control of bleeding, because the liver is one of the vascular rich organ (Ueda *et al.*, 2004). The laparoscopic surgery was provide good visual of anatomic detail in addition to that less pain, shorter recovery time and more cosmetic incision. This study showed that laparoscopic partial liver resection is feasible and not difficult. The application of a intracorporeal horizontal interrupted mattress suture in a triangular shape around the resection area with subsequent partial liver resection was provide to be possible and effective method. This technique was allowed to control bleeding, if the surgeon has good experience for application of suture around the resected area. Minimal bleeding was occurred after hepatic resection by scissor, which control by holding of the omental by grasper and pressure over the bleeding site for about 3-4 min, besides that in group B, the simple interrupted suture which used to approximate the resected edge also help to stop bleeding. This observation was disagree with other worker (Constant *et al.*, 2005), whom said that laparoscopic suturing is difficult in the best circumstances, trying to control a bleeding. But in this study suturing the liver parenchyma around the resected part create a suitable pressure on the hepatic blood and bile vessels in order to control bleeding from resected edge. While, Montorsi *et al.* (2002) mentioned that bleeding from larger vessels can usually be managed by

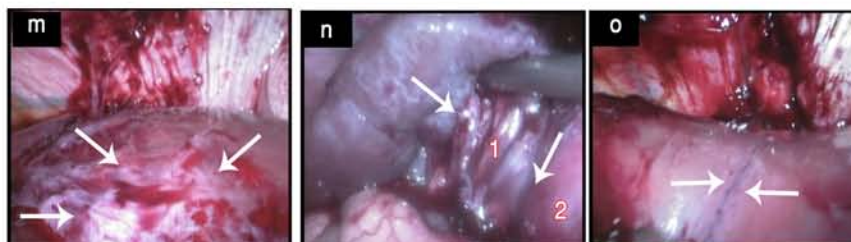


Fig. 4: Laparoscopic of the abdomen after one month post-operation showing: m) Dorsal view of the liver, partial regeneration of the resected site "arrow" (group, A), n) Ventral view of the liver, adhesion between ventral side of the resected site and omentum (1) and omasum (2) "arrow" (group, A), o) Irregular line, represent the regeneration of the approximate of the resected edge "arrow" (group, B)

clips application or intracorporeal suturing. Kaneko *et al.* (2008) said that ultrasonic dissection of the liver tissue provides coagulation of small vessels <2 mm in diameter and the laparoscopic suturing technique also contributes ensuring secure ligation of large intrahepatic vessels during parenchyma dissection, although double clipping might have been sufficient.

There are different methods of liver transection was performed such as a harmonic scalpel, which is a surgical device utilizing ultrasonic energy to cut and coagulate tissue, this system coagulates with relatively low heat and limited lateral thermal injury without charring the tissue. Also, tissue link monopolar sealer employs the radiofrequency energy and saline causes the tissue and blood vessels to shrink, resulting in sealing and hemostasis. Or microwave coagulates, microwave emission is started after the liver tissue is punctured with microwave scalpel, so that the liver parenchyma around the scalpel is coagulated. Also, the endostapler was particularly useful for dividing hepatic parenchyma and large vessels to minimize bleeding from the resected edge (Ueda *et al.*, 2004; Ardito *et al.*, 2007; Kaneko *et al.*, 2008). Also, Mami *et al.* (2009), describe that the vessel sealing system (LigaSure) was safe in hepatic resection.

There was one case died in group A, this may be due to during resected part, cut close to the loop of stitch, which lead to loose of its, with create uncontrolled bleeding and invisible surgical field. This phenomenon was coinciding with other workers (Ryan and Jaulkner, 1989), whom said that mortality of hepatic resection correlate closely with operative blood loss. De Boer *et al.* (2007) mention that partial liver resections remain a major surgical procedure and carry the risk for excessive blood loss and a subsequent need for blood transfusion. Wakabayashi *et al.* (2009) explain that for safer laparoscopic liver resection, efficient bleeding control techniques, such as radiofrequency pre-coagulation and the liver hanging maneuver, are needed during parenchymal transection of the liver.

The results of laparoscopic findings at one month post-operation showed that there was a better regeneration of the resected site in group B, as compare with group A, this may be due to, the approximation of resected edge, help to enhance regeneration. In addition to that more degree of adhesion in group A, may be result from exposure of resected edge to the peritoneal cavity and adjacent structure, which help to adherent with its. While in group B, the approximation of resected site minimized to exposure of the liver parenchyma to the peritoneal cavity. Ikeda *et al.* (2009) describe that the parasympathetic system (vagus nerve) contributes to liver regeneration after hepatectomy by stimulating IL-6 release from Kupffer cells followed by signal transducer and activator of transcription-3 activation in hepatocytes. While Huang *et al.* (2006), identify a role for nuclear receptor-dependent bile acid signaling in normal liver regeneration. Elevated bile acid levels accelerate regeneration and decreased levels inhibit liver regrowth.

CONCLUSION

This study revealed that the laparoscopic partial hepatectomy by intracorporeal horizontal interrupted mattress suture was feasible and not difficult. But, it needs good experience surgeons to applicate of suture and also require modification in some laparoscopic instruments to hold the liver without tearing of its. It can be suggest that this technique was possible to use in partial liver resection of localized tumor, abscess, limited cirrhosis, cyst and other localized lesion at the suitable distance from the edge of liver lobe. To the knowledge this method of partial hepatectomy by suture technique is to be the first report in study.

ACKNOWLEDGEMENTS

I would like to thanks, Ali Abbas Ajeel, Majid Abdul Rahman Alkhalany (Ph.D students, Department of Surgery and Obstetric, College of Veterinary Medicine,

Baghdad University) and Abd Al-Star Selman Hamza (MSc, Department of Surgery and Obstetric, College of Veterinary Medicine, Diwania University), for their help all the way out in the research.

REFERENCES

- Azagra, J.S., M. Goergen, E. Gilbert and D. Jacobs, 1996. Laparoscopic anatomical (hepatic) left lateral segmentectomy technical aspects. *Surgery Endoscopic.*, 10: 758-761. <http://www.springerlink.com/index/KU55581T56512482.pdf>.
- Constant, D.L., D.P. Slakey, R.J. Campeau and J.B. Dunne, 2005. Laparoscopic nonanatomic hepatic resection employing the LigaSure device. *J. Soc. Laparoendoscopic Surgeons*, 9: 35-38.
- De Boer, M.T., M.I. Quintus and R.J. Porte, 2007. Impact of blood Loss on outcome after liver resection. *Digestive Surg.*, 24: 259-264. <http://content.karger.com/produktedb/produkte.asp?typ=fulltext&file>.
- Huang, W., K. Ma, J. Zhang, M. Qatanani, J. Cuvillier, J. Liu, B. Dong, X. Huang and D.D. Moore, 2006. Nuclear receptor-dependent bile acid signaling is required for normal liver regeneration. *Science*, 312 (5771): 233-236. <http://www.sciencemag.org/cgi/content/full/sci.312/5771/233>.
- Ikeda, O., M. Ozaki, S. Murata, R. Matsuo, Y. Nakano, M. Watanabe, K. Hisakura, A. Myronovych, T.K. Takuya, K. Kohno and N. Ohkohchi, 2009. Autonomic regulation of liver regeneration after partial hepatectomy in mice. *J. Surgical Res.*, 152: 218-223. <http://linkinghub.elsevier.com/retrieve/pii/S0022480408001601>
- Kaneko, H., Y. Otsuka, M. Tsuchiya, A. Tamura, T. Katagiri and K. Yamazaki, 2008. Application of devices for safe laparoscopic hepatectomy. *Hepato Pancreato Biliary (Oxford)*, 10 (4): 219-224. <http://www.pub-medcentral.nih.gov/articlerender.fcgi?artid=2518297>.
- Kaneko, H., 2005. Laparoscopic hepatectomy: Indications and outcomes. *J. Hepatobiliary Pancreatic Surg.*, 12: 438-443. <http://www.springerlink.com/index/726U07719U444V53.pdf>.
- Koffron, A., D. Geller, T.C. Gamblic and M. Abecassis, 2006. Laparoscopic liver surgery: Shifting the management of liver tumors. *Hepatology*, 6 (44): 1694-1700. DOI: 10.1002/hep.21485.
- Mami, I., H. Kiyoshi, S. Keiji, I. Hiroshi, B. Yoshifumi, S. Yasuhiko, K. Norihiro and M. Masatoshi, 2009. The Vessel Sealing System (LigaSure) in hepatic resection: A randomized controlled trial. *Ann. Surg.*, 250 (2): 199-203. <http://journals.lww.com/annalsofsurgery/toc/2009/08000>.
- McEwen, M.M., R.D. Gleed, J.W. Ludders, T. Stokol, F.D. Del Piero and H.N. Erb, 2000. Hepatic effects of halothane and isoflurane anesthesia in goats. *J. Am. Vet. Med. Assoc.*, 217 (11): 1697-1700. <http://avmajournals.avma.org/doi/pdf/10.2460/javma.2000.217.1697>.
- Montorsi, M., R. Santambrogio, P. Bianchi, G. Dapri, A. Spinelli and M. Podda, 2002. Perspectives and drawbacks of minimally invasive surgery for hepatocellular carcinoma. *Hepatogastroenterology*, 49 (43): 56-61. <http://www.ncbi.nlm.nih.gov/pubmed/11941985>.
- Rau, H.G., A.P. Duessel and S. Wurzbacher, 2008. The use of water-jet dissection in open and laparoscopic liver resection. *Hepato Pancreato Biliary*, 10 (4): 275-280 (Abst.).
- Ryan, J.A. and D.J. Jaulkner, 1989. Liver resection without blood transfusion. *Am. J. Surg.*, 157 (5): 472-475 (Abst.). <http://www.ncbi.nlm.nih.gov/pubmed/2712203>.
- Ueda, K., P. Turner and M. Gagner, 2004. Stress response to laparoscopic liver resection. *Hepato Pancreato Biliary (Oxford)*, 6 (4): 247-252. DOI: 10.1080/13651820410023987.
- Wakabayashi, G., H. Nitta, T. Takahara, M. Shimazu, M. Kitajima and A. Sasaki, 2009. Standardization of basic skills for laparoscopic liver surgery towards laparoscopic donor hepatectomy. *J. Hepatobiliary Pancreatic Surg.*, 21: 16 (4): 439-444. <http://www.springerlink.com/index/2760656061GW01P8.pdf>.