

Fatal Adverse Reactions of Enterotoxaemia Vaccine in a Sheep Flock

¹Nuri Mamak and ²Ismail Aytekin

¹Department of Internal Medicine, Faculty of Veterinary Medicine,
Mehmet Akif Ersoy University, Burdur 15100, Turkey

²Directorate of District Agriculture, Suut-Afyonkarahisar, Turkey

Abstract: The aim of the present report was to describe the clinical signs, haematological findings and post-mortem lesions in sheep developing fatal complication after enterotoxaemia vaccination in an Awassi sheep flock in Hatay Province. The study included 3 Awassi ewes of 4 years old and 3 lambs from a sheep flock recently vaccinated against enterotoxaemia. Following blood samples collection for routine haematology the live animals were euthanized and subjected to necropsy along with dead animals at the department of pathology. In the histopathological examination, the liver contained multiple, small, randomly distributed foci of necrosis that contained neutrophils. The lungs were affected by mild intra-alveolar and interstitial hemorrhages. There was oedema and haemorrhage around arterioles and venules in the cerebrum. To improve the margin of safety and decrease undesired reactions, pharmaceutical companies provide specific guidelines for the administration of vaccines. However, even when vaccines are administered correctly, there is still the potential for an adverse reaction in a small proportion of the flock. Therefore, further research is obviously needed to discover of developing such an adverse effect.

Key words: Sheep, enterotoxaemia, vaccine, adverse reactions, haematology

INTRODUCTION

Vaccines are manufactured to boost host's immune system against diseases caused by microorganisms. Vaccination plays a very important role in protection of animal and public health. Vaccines contain antigens that stimulate the body's defences to produce either antibodies or activated cells that in turn modify or inactivate the causative agents of diseases. Billions of animals are vaccinated and thus, exposed to various antigens and adjuvant present in vaccines each year. However, the vaccines can occasionally lead to adverse reactions in recipient (Bullen, 1954). A range of local or systemic adverse reactions to vaccines has been observed in reports such as the onset of inflammatory, allergic, autoimmune or neoplastic diseases. Routinely performed vaccination may rarely cause the adverse effect in animals. Local reactions to vaccines have well been documented and are usually observed by clinicians (Day, 2006). However, systemic adverse reactions associated with various vaccines are not as common and clinical cases of these reactions are poorly documented (Ellis and Yong, 1997).

Enterotoxaemia is caused by *Clostridium perfringens* type D-producing e-toxin is the most common cause in

sheep and goats worldwide and younger animals usually are the most affected (Carlton, 2005). Small ruminants are routinely vaccinated against enterotoxaemia and associated adverse local reactions have been reported previously (Bullen, 1954). However, no reports on detailed systemic reactions associated with enterotoxaemia vaccine in sheep have been produced so far.

The aim of the present report was to describe the clinical signs, haematological findings and post-mortem lesions in sheep developing fatal complication after enterotoxaemia vaccination in an Awassi sheep flock in Hatay Province.

MATERIALS AND METHODS

The study included 3 Awassi ewes of 4 years old and 3 lambs from a sheep flock recently vaccinated against enterotoxaemia. Flock was grazed on pasture managed in local conditions in Kirikhan, Hatay. The history revealed that 2 ewes from the flock died of unknown reason and the veterinarian had prescribed a treatment regimen for prophylactic purposes just before enterotoxaemia vaccination. Thus, each animal in the flock received long-acting oxytetracycline intramuscularly at a rate of 20 mg kg⁻¹ Body Weight (BW), doramectin (Dectomax 1% injectable Solution, Pfizer) at a rate of 1 mL/50 kg BW and

flunixin meglumine (Finadyne, Intervet, 2.2 mg kg⁻¹ intravenously. Seven days after this treatment, all animals were subjected to regular vaccination against clostridial diseases with commercial enterotoxaemia vaccines, according to manufacturer's instructions.

Two ewes and two lambs had sudden death and were referred to the clinics of the faculty of veterinary medicine, Mustafa Kemal University, Hatay, Turkey along with one live ewe and lamb with clinical signs resembling to those of dead sheep. A thorough clinical examination was carried out on these live ewe and lamb.

Following blood samples collection for routine haematology the live animals were euthanized and subjected to necropsy along with dead animals at the department of pathology. From internal organs, samples were collected and immersed in 10% buffered formalin for at least 48 h. The samples were embedded in paraffin wax, sectioned at 6 mm and stained with haematoxylin and eosin.

RESULTS

The history revealed that all the animals were clinically normal before vaccination and clinical alterations were observed approximately, 2-4 h after the vaccination. 16 of the 54 sheep showed signs ranging from mild depression to dyspnoea with foamy nasal and oral discharge. The shepherd stated that twelve animals of the more severely affected 16 ewes died on the farm and after 2 days of enterotoxaemia vaccination death of particularly well nourished 5 or 6 months old lambs and ewes increased.

Clinical examination of live animals revealed nervous symptoms such as dullness, muscular tremors, opisthotonos, convulsions and circling, mild hyperemia in conjunctiva, cyanosis of oral mucosa and mucoid nasal discharge. Vaccination of the animals also resulted in swelling of approximately 5 cm in diameter at the injection site after vaccination (Fig. 1). Findings of haematology of the live ewe and lamb were within reference range. Rest of the diseased animals showing mild to moderate clinical signs was cured with dexamethasone and epinephrine and the death ceased in the sheep flock.

On gross examinations, all ewes and baby lambs had similar changes. The dead animals had good body condition. Necropsy revealed the presence of mild peritoneal and pericardial bloody effusions, congested oedematous lungs and pale friable liver in animals. Observations on the necropsy of each ewes and baby lambs, which were obvious in sudden dead animals, had



Fig. 1: Gross appearing of the swelling tissue of injection site after vaccination

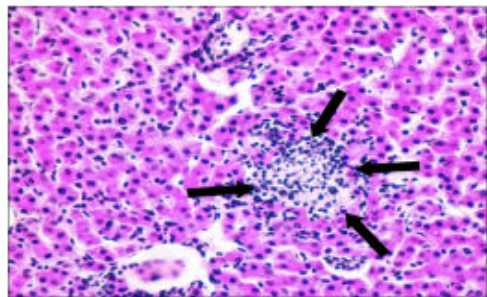


Fig. 2: Histopathological appearing of liver containing necrosis foci with neutrophil infiltrations (arrows)

interstitial pulmonary edema, congestion and multifocal-to-coalescing hemorrhages in the dorsal pulmonary parenchyma, which failed to collapse, when the thoracic cavity was opened. In some regions of the lung hepatization was observed. Bilateral and mostly symmetrical areas of haemorrhage were evident that mainly involved areas of grey matter in the brainstem from the level of the caudal colliculi to the thalamus. In the occipital and caudal parietal cortex, there was oedema of white matter.

In the histopathological examination, the liver contained multiple, small, randomly distributed foci of necrosis that contained neutrophils. No etiological agents were visible (Fig. 2).

The lungs were affected by mild intra-alveolar and interstitial hemorrhages. The interalveolar septa were thickened by interstitial edema, mild activation of pulmonary macrophages and endothelial cells and congested/hyperemic capillaries containing a multifocally increased number of neutrophils (Fig. 3).

There was oedema and haemorrhage around arterioles and venules in the cerebrum, hippocampus, internal capsule, thalamus, midbrain, dorsal medulla and central cerebellar and cerebellar folial white matter (Fig. 4).

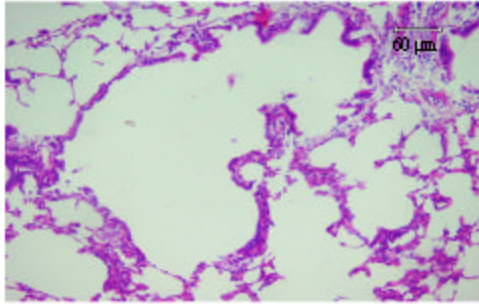


Fig 3: Histopathological appearing of lungs with mild intra-alveolar and interstitial hemorrhages and alveolar emphysema, thickened interalveolar septa and hyperemic capillaries neutrophils infiltrations

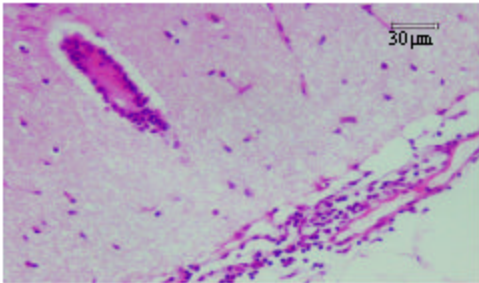


Fig 4: Histopathological appearing of cerebrium with haemorrhage around arterioles and venules

DISCUSSION

Fatal adverse reactions to vaccination are uncommon and poorly documented. To the knowledge, this is the first report of fatal adverse reaction to vaccination in sheep from a flock vaccinated against clostridial diseases in Turkey.

Commercial multi-component clostridial vaccine was used in current report. Vaccine contained the specific formal treated toxoids of *Clostridium perfringens* types C and D, *Clostridium tetani*, *Clostridium septicum* together with the products of lysed organisms and formalized whole cultures of *Clostridium chavoei*, *Clostridium oedematiens* types B and D and *Clostridium perfringens* type B. The enterotoxaemia vaccine would be an enormous benefit for sheep breeders all over the world (Radostits *et al.*, 1994). However, it seems that the use of vaccine will result in adverse reaction in some sheep flock, when administered under the conditions some veterinarian practitioner used. The vaccinated animals may have undesired local or systemic adverse reactions associated with vaccination. Local reactions to vaccines are relatively well documented and are usually

observed by clinicians. Most common local reactions to vaccines are transient erythema, oedema and swellings (Brooks, 1991) as observed in our report (Fig 1). There are limited scientific data that explain how the majority of vaccine reactions occur (Day, 2006). To the best of our knowledge, published data of the fatal adverse reaction in sheep vaccinated against clostridial diseases in Turkey farm animal do not exist.

Each animal received flunixin meglumine prophylactically by the attending veterinarian before vaccination. Nonsteroidal anti-inflammatory drugs have various effects on the immune response. Decreased blastogenesis has been described for ibuprofen as well as other such agents (Graham *et al.*, 1990; Panush, 1978). In addition, Graham *et al.* (1990) showed decreased antibody response to rhinovirus infections, when given ibuprofen. Similarly, the administration of nonsteroidal anti-inflammatory drugs was possibly associated not only with reduced titers of serum neutralizing antibodies after enterotoxaemia vaccine, but also with greater clinical severity of a possible subclinical infection with *Clostridial* toxin in sheep, which received nonsteroidal anti-inflammatory agents.

Sudden deaths occurred as a result of vaccination with *Clostridial* sp., which proliferated in parenchymal tissues with subsequent fatal toxemia (Glock and DeGroot, 1998). Assuming that the same conditions in here might be effective in sheep flock. However, the findings found here were not entirely consistent with *Clostridial* sp. in sheep (Bullen, 1954).

The presence of local reactions in sheep and lambs after the vaccinations occurred as reported before (Bullen, 1954). Accordingly, it is suggested that clostridial vaccines in animals be administered at sites distinct from regional lymph nodes in order to avoid confusing such reactions.

Essentially, we believed that if all other vaccinated sheep were treated with dexamethasone and epinephrine after the sheep died suddenly there would not be additional mortalities in the sheep flock associated with this vaccination as reported by Ramsay *et al.* (2005) in calves.

CONCLUSION

To improve the margin of safety and decrease undesired reactions, pharmaceutical companies provide specific guidelines for the administration of vaccines. However, even when vaccines are administered correctly, there is still the potential for an adverse reaction in a small

proportion of the flock. The number of adverse reactions in vaccinated animals can be greatly increased if the vaccine is not administered according to the manufacturer's instructions. Therefore, it is essential to educate producers to administer appropriately vaccines and to conform to the product specifications. Nevertheless, further research is obviously needed to discover of developing such an adverse effect.

ACKNOWLEDGEMENTS

I would like to thank Assoc. Prof. Dr. Ramazan DURGUT (Department of Internal Medicine, Veterinary Faculty, Mustafa Kemal University), Assis. Prof. Dr. Murat GUZEL (Department of Internal Medicine, Veterinary Faculty, Mustafa Kemal University), Assis. Prof. Dr. Sule Yurdagül OZSOY (Department of Pathology Veterinary Faculty, Mustafa Kemal University) and Dr. Mehmet TUZCU (Department of Pathology, Adana Veterinary Control and Research Institute) for their kind help.

REFERENCES

- Bullen, J.J., 1954. Enterotoxemia of sheep: *Clostridium welchii* type D in the alimentary tract of normal animals. *J. Pathol. Bacteriol.*, 64: 201-206. <http://www3.interscience.wiley.com/journal/110529689/abstract?CRETRY=1&SRETRY=0>.
- Brooks, R., 1991. Adverse reactions to canine and feline vaccines. *Aust. Vet. J.*, 68: 342-344. PMID: 1755787. <http://www.ncbi.nlm.nih.gov/pubmed/1755787>.
- Carlton, L.G., 2005. Clostridial Disiases. 9th Edn. In: Cynthia, B.A. and M.A. Kahn (Eds.). *The Merck Veterinary Manuel*, M., Whitehouse Station, N.J., USA, pp: 493-495. ISBN: 978-0-911910-50-6.
- Day, M.J., 2006. Vaccine side effects: Fact and fiction. *Vet. Microbiol.*, 117: 51-58. PMID: 16701964. <http://www.ncbi.nlm.nih.gov/pubmed/16701964>.
- Ellis, J.A. and C. Yong, 1997. Systemic adverse reactions in young Simmental calves following administration of a combination vaccine. *Can. Vet. J.*, 38: 45-47. PMID: 8993786. <http://www.ncbi.nlm.nih.gov/pubmed/8993786>.
- Glock, R.D. and B.D. DeGroot, 1998. Sudden death of feedlot cattle. *J. Anim. Sci.*, 76: 315-319. PMID: 9464913. <http://www.ncbi.nlm.nih.gov/pubmed/9464913>.
- Graham, N.M.H., C.J. Burrell, R.M. Douglas, P. DeBelle and L. Davies, 1990. Adverse effects of aspirin, acetaminophen and ibuprofen on immune function, viral shedding and clinical status in rhinovirus-infected volunteers. *J. Infect. Dis.*, 162: 1277-1282. PMID: 2172402. <http://www.ncbi.nlm.nih.gov/pubmed/2172402>.
- Panush, R.S., 1978. Clinical drug efficacy and *in vitro* inhibition of lymphocyte responses in rheumatoid arthritis. *Arthritis Rheum.*, 21: 171-173. PMID: 341896. <http://www.ncbi.nlm.nih.gov/pubmed/341896>.
- Radostits, O.M., D.C. Blood and C.C. Gay, 1994. *A Textbook of the Diseases of Cattle, Sheep, Pigs, Goats and Horses*. 8th Edn. Veterinary Medicine Bailliere Tindall, London. ISBN: 0702017949, 9780702017940. <http://www.worldcat.org/wcpa/isbn/9780702017940>.
- Ramsay, J.D., C.L. Williams and E. Simko, 2005. Fatal adverse pulmonary reaction in calves after inadvertent intravenous vaccination. *Vet. Pathol.*, 42: 492-495. <http://www.vetpathology.org/cgi/content/abstract/42/4/492>.