

## Seasonal Distribution of Sheeppox Cases in Lambs in Eastern Turkey

<sup>1</sup>Y. Eroksuz, <sup>2</sup>H. Bulut, <sup>2</sup>İ. Gulacti and <sup>1</sup>A.O. Ceribasi

<sup>1</sup>Department of Pathology, <sup>2</sup>Department of Virology, Faculty of Veterinary Medicine, Firat University, 23110, Elazığ, Turkey

**Abstract:** Sheeppox is an endemic disease in Turkey and cause significant economical losses. Although sheeppox cases can be seen in Turkey during various periods in a year, the cases occurring in the March-April period are the most prevalent in lambs of approximately one and half months of age. The objective of the present study was the virological, pathological and epidemiological investigation of the seasonal cases that cause high mortality in lambs. Following the clinical and pathological examinations of the cases, DNAs extracted from the samples were amplified by the Polymerase Chain Reaction (PCR) and PCR products were sequenced. According to PCR and sequence results, it was confirmed that the lambs were infected with sheeppox virus. In the anamnesis, it was reported by the owners of the animals that the mother ewes of the affected lambs had been in the pasture before the occurrence of the disease. Therefore, it could be concluded that being in the pasture for mother ewes for a period of time plays a major role in the epidemiology of the seasonal cases. In addition, lambs can play a role in the spread and maintenance of the virus in the environment.

**Key words:** Sheeppox disease, polymerase chain reaction, lamb, pasture

### INTRODUCTION

Sheeppox Virus (SPPV), Goatpox Virus (GTPV) and Lumpy Skin Disease Viruses (LSDV) are classified in the genus Capripoxvirus of *Poxviridae* family. These viruses have a 96% similarity at the nucleotide level (Tulman *et al.*, 2002). Sheeppox virus and GTPV are the etiological agents of sheeppox and goatpox diseases, respectively. Sheeppox disease is highly contagious disease of small ruminants characterized by fever, nasal discharge, generalized skin, internal pox lesions and lymphadenopathy (Bhanuprakash *et al.*, 2006; Gulbahar *et al.*, 2000). Although the disease can be seen in all ages, it is more frequent in younger animals with high mortality rate (80-100%) (Mariner *et al.*, 1991). Furthermore, when sheeppox is seen in a country, restricted on the international trade of animal and animal products cause significant economical losses. Sheeppox has now been eradicated in developed countries, but remain as the cause of major losses in some developing countries (World Organization for Animal Health, 2005-2006). In Turkey, the disease is endemic and cause important economical losses. Sheeppox is considered as an exotic disease that is absent in EU countries, with the exception of sporadic cases. It is believed that the

cases occurred in EU countries originated from Asian countries such as Turkey (Oğuzoğlu *et al.*, 2006). Serological tests such as agar gel immunodiffusion, complement fixation, counter immunoelectrophoresis or Enzyme Linked Immunosorbent Assay (ELISA) and the methods based on virus isolation have been used for diagnosis of sheeppox. The methods based on virus isolation are time consuming and laborious. On the other hand, the antibody responding against the SPPV has a cross reaction with the Orf virus from the same family. Therefore, these serological tests have low specificity (Mangana-Vougiouka *et al.*, 2000; Rao and Bandyopadhyay, 2000). Polymerase Chain Reaction (PCR) is preferably used in the diagnosis of the SPPV cases since, it yields results faster and have a high sensitivity and specificity (Mangana-Vougiouka *et al.*, 1999). In Turkey, it is obliged to notify sheeppox and the vaccination has been used for its control for a very long time. However, some cases may still occur. Generally, high mortality and morbidity rates in lambs (1-2 months old, mothers vaccinated) was shown to be high especially between March and April.

The objectives of this study were to identify the viruses obtained from the seasonal cases and to attempt to explain the seasonal variations in occurrence of sheeppox cases.

## MATERIALS AND METHODS

**Clinical materials:** Ten Akkaraman lambs were obtained from clinically diagnosed sheeppox cases in Elazig and Bingol provinces between March and April from 2004-2006. The lambs were housed in ten different private flocks. The age of the animals ranged from 4-7 weeks. The samples for PCR analysis were taken under aseptic conditions from under-tail, mouth and vesicles over the tongue. The animals were euthanized and necropsied at Firat University, Veterinary Pathology Laboratory. Additional tissue samples were also taken from lungs, liver, skin, kidneys, tongue and esophagus for histopathological examinations.

**Histopathological examination:** Tissue specimens from skin, lungs, kidneys, tongue, esophagus were collected and fixed in 10% formalin, embedded in paraffin and sectioned at 5 µm and stained with hematoxylin-eosin (H and E). Selected sections were also stained Grocott's and periodic acid schiff stains (Bancroft and Stevens, 1990).

**DNA-RNA extraction and PCR:** DNA extractions from the clinical and control specimens (distilled water and sheep-goat poxvirus vaccine) were performed with using a NucleoSpin®Tissue commercial kit by following the procedure recommended by the manufacturer (Macherey-Nagel Inc., USA). Some epidemics of orf and Peste des Petits Ruminant (PPR) that have clinical similarity with sheeppox in our country also can be determined. Therefore, in addition to DNAs that would be used for sheeppox and orf, RNAs were extracted. For presence of PPR virus from the clinical samples, RNA extractions were carried out using commercial kit by following the procedure recommendations by the manufacturer (EZ-RNA Total RNA Isolation Kit, Biological Industries Corp, Beit Haemek-Israel). DNA and RNA pellets were dissolved in 50 µL distilled water and stored at -20°C until time they were used.

The primers used for diagnosis of SPPV in this study were InS 1.1/InS-1.1' and KS-1.5/KS-1.6 and were described previously (9). PCR for SPPV was performed in a total reaction volume of 50 µL containing 5 µL of 10X PCR buffer (100 mM Tris-HCl, pH 8.0, 500 mM potassium chloride, 15 mM magnesium chloride), 200 µM each of the four deoxynucleotide trifosphates, 1 U Taq DNA polymerase (Bioron), 100 pM primers and 10 µL DNA. DNAs were amplified for 35 cycles of 30 sec at 95°C, 30 sec at 55°C and 30 sec at 72°C. A final extension step was performed at 72°C for 10 min. The PCR products were stained with etidium bromide and visualized under ultraviolet light on 2% agarose gel.

DNA and RNA isolated from clinical samples were also used to amplify by PCR using primers for orf virus and PPRV. PCR method for orf (Inoshima *et al.*, 2000) and PPR (Couacy-Hymann *et al.*, 2002) viruses were performed as previously described.

**Sequencing:** Two of the samples that were detected as PCR positive with InS 1.1 and InS-1.1' primers were randomly selected and sequenced. The DNAs of these samples were purified and sequenced by using ABI 310 Genetic Analysis System (Intec Co., Istanbul/Turkey). Comparison of these sequence results with the present genome sequences in databank was performed with the BLAST program.

**Serum neutralization:** Blood samples for serological test were taken only from 6 lambs and 4 mother ewes. Sera were obtained from the samples. Serum neutralization assay was performed as Frey and Liess. In the assay, VERO cells and Turkey vaccine strain (Pocvac-Biovet) were used.

## RESULTS AND DISCUSSION

**Macroscopical findings:** Papular lesions having approximately 0.5-1.5 cm diameter which covered by the formation of a thin crust were seen mainly in the areas of skin regions where the wool is scant and shortest in all the lambs. Discrete circumscribed changes were additionally detected on the tongue, esophagus and ruminal mucosa in 3 cases. The pulmonary lesions consisted of circular and yellow-white papules and multifocal consolidated areas were present in all cases. The kidney lesions consisting of multifocal pale papules throughout the renal cortex and were present in 3 of the lambs.

**Histopathological findings:** Skin sections had prominent areas of acanthosis and parakeratotic hyperkeratosis. Degenerative changes characterized by intraepidermal microvesiculation were seen epidermis. There were many mononuclear cells, scattered neutrophils and sheeppox cells in dermis and subcutis. Similar degenerative and inflammatory changes were also present on tongue (5/10), oesophageal (4/19) and ruminal (3/10) mucosal epithelium. The pulmonary lesions characterized by alveolar septal thickening due to infiltration of mononuclear cells, few neutrophils and sheeppox cells. Sheeppox cells had vacuolated nuclei and basophilic cytoplasm and some contained inclusion body (Fig. 1). Alveolar edema and bronchial epithelial hyperplasia were additional findings detected. Focal interstitial mononuclear cell infiltrations were also present in some

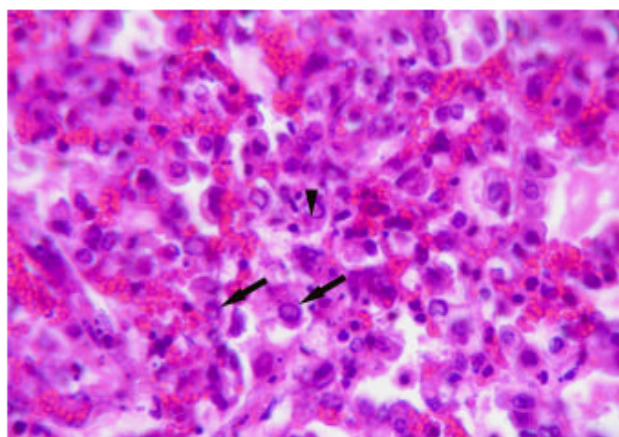


Fig. 1: Sheeppox cells (arrows) and inclusion body (arrow head) in marked aggregation of mixture of inflammatory cells in dermis, H and E, x200

2005/23/ELG	AGAAACGAGGTCTCGAAGCAATACCAACACCTTCATAGAAGAACAAAGTTGGAGATGATT
AY077834.1	AGAAACGAGGTCTCGAAGCAATACCAACACCTTCATAGAAGAACAAAGTTGGAGATGATT
AY077833.1	AGAAACGAGGTCTCGAAGCAATACCAACACCTTCATAGAAGAACAAAGTTGGAGATGATT
AY077832.1	AGAAACGAGGTCTCGAAGCAATACCAACACCTTCATAGAAGAACAAAGTTGGAGATGATT
AY077835.1	AGAAACGAGGTCTCGAAGCAATACCAACACTTTACAGAACAAAGTTGGAGATGATT
2005/23/ELG	TCCACCCCAATATTCTGCTGCTCTTGCTAAAAATTCCAATCACTGCACATGATTCCCTAAT
AY077834.1	TCCACCCCAATATTCTGCTGCTCTTGCTAAAAATTCCAATCACTGCACATGATTCCCTAAT
AY077833.1	TCCACCCCAATATTCTGCTGCTCTTGCTAAAAATTCCAATCACTGCACATGATTCCCTAAT
AY077832.1	TCCACCCCAATATTCTGCTGCTCTTGCTAAAAATTCCAATCACTGCACATGATTCCCTAAT
AY077835.1	ACCACCCCAATATTCTGCTGCTCTTGCTAAAAATACCAATCACTGCACATGATTCCCTAAT
2005/23/ELG	GTGATTTTCTTTTTTAACATGGAATTAATCATAATTTTGTATGTTCAAATCCAATTTT
AY077834.1	GTGATTTTCTTTTTTAACATGGAATTAATCATAATTTTGTATGTTCAAATCCAATTTT
AY077833.1	GTGATTTTCTTTTTTAACATGGAATTAATCATAATTTTGTATGTTCAAATCCAATTTT
AY077832.1	GTGATTTTCTTTTTTAACATGGAATTAATCATAATTTTGTATGTTCAAATCCAATTTT
AY077835.1	GTAATTTTCTTTTTTAACATGGAATTAATCATAATTTTGTATGTTCAAATCCAATTTT
2005/23/ELG	AGAAATCCAAAAACATGTTTTTGACAAAAGCTGTTAGATCATTTCCAAATACAAGTGAGGC
AY077834.1	AGAAATCCAAAAACATGTTTTTGACAAAAGCTGTTAGATCATTTCCAAATACAAGTGAGGC
AY077833.1	AGAAATCCAAAAACATGTTTTTGACAAAAGCTGTTAGATCATTTCCAAATACAAGTGAGGC
AY077832.1	AGAAATCCAAAAACATGTTTTTGACAAAAGCTGTTAGATCATTTCCAAATACAAGTGAGGC
AY077835.1	AGAAATCCAAAAACATGTTTTTGACAAAAGCTGTTAGATCATTTCCAAATACAAGTGAGGC
2005/23/ELG	ATCCTTTTGTAAAGATTCAAAAACTAAGAACACATTTCCAGCAACCTCC
AY077834.1	ATCCTTTTGTAAAGATTCAAAAACTAAGAACACATTTCCAGCAACCTCC
AY077833.1	ATCCTTTTGTAAAGATTCAAAAACTAAGAACACATTTCCAGCAACCTCC
AY077832.1	ATCCTTTTGTAAAGATTCAAAAACTAAGAACACATTTCCAGCAACCTCC
AY077835.1	ATCCTTTTGTAAAGATTCAAAAACTAAGAACACATTTCCAGCAACCTCC

Fig. 2: Alignment of the nucleotide sequences of the InS.1.1 region of some capripoxvirus strains with the nucleotide sequences amplified PCR from the clinical sample (2005/23/ELG)

kidney sections. Perivascular infiltrations consisting of lymphocytes, macrophages, neutrophils and edema were detected in arterioles, venules and capillaries in the lungs and skin. No fungi were apparent in Grocott's or PAS stain.

**PCR and Sequencing:** The PCR with two different primer pairs (KS-1.5/KS-1.6, InS-1.1/InS-1.1') specific for poxvirus

successfully amplified 149 and 289 bp fragment from all clinical samples, respectively (data not shown). There was no band after the PCR that were performed with Orf and PPR primers for the same samples (data not shown). For the confirmation of the PCR, the PCR products amplified with the InS.1.1 and InS-1.1' primers were sequenced and sequencing analysis confirmed the isolates as SPPV (Fig. 2).

**Serology:** According to the neutralization assay results, all the ewes and lambs had neutralizing anti-SPPV antibodies.

Sheeppox endemics can be seen in Turkey in various periods during a year, which are more frequent especially in the periods of October-November and March-April (Oğuzoğlu *et al.*, 2006; World Organization for Animal Health, 2005-2006). Although, epidemics occurring in the October-November period are generally seen in adult sheep, those occurring in the March-April period are especially seen in lambs of approximately one and half months of age. The objective of the present study has been the virological, pathological and epidemiological investigations of the seasonal cases with high mortality in lambs.

For control and prevention of sheeppox infections, live attenuated virus vaccines are used for a very long time in Turkey. These vaccines are administered to the animals before their return from pastures (late October) and provide long-term (about 10 months) immunity. In support to this, in the anamnesis, the owners of the case lambs reported that the mother of the lambs had mated (September) and vaccinated just before their return from the pastures (late October). The lambs were born in February. The mothers of the lambs showed no clinical signs of sheeppox except for mastitis seen in some animals. Based on our clinical observations for long years in the region, we can state that the sheeppox has not been seen in animals vaccinated but not been in the pasture for anytime. Therefore, we believe that there is a strong relation between the occurrence of the disease in lambs and being their mothers in the pasture. It can be speculated that those sheep that were subclinically infected due having lower antibody level from previous vaccination could be the source of infection and those sheep could be carrying the virus to the sheep-folds from pasture. One of the most possible causes of the disease in lambs which are considered to carry maternal antibodies could be presence of remaining infective viruses from previous cases which are resistant to the environment of sheep-folds. Occurrence of the disease in 1-2 months old lambs may suggest that the lambs are protected by the maternal antibodies against the effect of the virus in the first days of their lives and the disease occurs when the level of the maternal antibodies begin to decline. However, a more extensive study is required investigating the entire time period between the leaving for pasture from the sheep-fold and returning from the pasture times and until the time the disease occurs.

In the cases of the present investigation, some of the lactating sheep displayed symptoms of mastitis. Chronic mastitis is known to be one of the most important causes of sheeppox (Dixon, 2001). However, the causes of

mastitis in the lactating sheep have not been subject of the present study. Although the lactating sheep show no clinical symptoms of sheeppox except for mastitis, they spread the virus by milk, due to which the lesions of the disease are frequent, especially in the oral cavities of breast-feeding animals (Garner *et al.*, 2000; Jubb *et al.*, 1985; Rao and Bandyopadhyay, 2000). In the present study, sheeppox lesions in the lambs were detected especially in the tongue, gingiva, axillary region and the areas under the tail. Diffuse lesions were detected on the tongues and gingiva of all lambs selected for diagnostic purposes. Meanwhile, these lesions can make breast feeding difficult, as a result of which lambs will not only acquire the virus, but also, because of insufficient breast feeding, they will lose the opportunity to intake sufficient maternal antibody which would prevent them from the disease. We consider sheep with mastitis to be the primary cause of these cases.

## CONCLUSION

In the present study, presence of sheeppox virus into the samples obtained from the lambs was confirmed by PCR along with the specific pathological changes for the disease. It was concluded under the light of these results that the seasonal cases in lambs can play a role as the passage of the virus and can lead to prolongation of the presence of the virus in the environment. In this respect, it is important to determine these viral infections in a short time and to use control methods in lambs. In addition, considering the potential relationship between being in the pasture and the occurrence of the disease. It is necessary to follow up of vaccination record of those animals that are taken to pasture and strong control measures to be taken to prevent animal smuggling from the borders and disinfection of sheep-folds for eradication or minimization of sheeppox cases in Turkey or in EU countries.

## REFERENCES

- Bancroft, J.D. and A. Stevens, 1990. Theory and Practise of Histological Techniques. 3rd Edn. Churchill, Livingstone, Edinburg, pp: 112-147, 509-596.
- Bhanuprakash, V., B.K. Indrani, M. Hosamani and R.K. Singh, 2006. The current status of sheeppox disease. *Comparative Immunol. Microbiol. Inf. Dis.*, 29: 27-60.
- Couacy-Hymann, E., F. Roger, C. Hurard, J.P. Guillou, G. Libeau and A. Diallo, 2002. Rapid and sensitive detection of peste des petits ruminants virus by a polymerase chain reaction assay. *J. Virol. Methods*, 100: 17-25.

- Dixon, R.J., 2001. Exotic Disease. Faculty of Veterinary Science. The University of Sydney Camden, pp: 5-6.
- Garner, M.G., S.D. Sawarkar, E.K. Brett, J.P. Edwards, V.B. Kulkarni, D.B. Boyle and S.N. Singh, 2000. The extent and impact of sheeppox and goatpox in the state of Maharashtra, India. *Trop. Anim. Health Prod.*, 32: 205-223.
- Gulbahar, M.Y., M. Cabalar, Y. Gul and H. Icen, 2000. Immunohistochemical detection of antigen in lamb tissues naturally infected with sheeppox virus. *J. Vet. Med. Series B Infect. Dis. Vet. Public Health*, 47: 173-181.
- Inoshima, Y., A. Morooka and H. Sentsui, 2000. Detection and diagnosis of parapoxvirus by the polymerase chain reaction, *J. Virol. Methods*, 84: 201-208.
- Jubb, K.V.F., P.C. Kennedy and N. Palmer, 1985. In: *Pathology of Domestic Animals*, Academic Press, New York, 2: 466-468.
- Mangana-Vougiouka, O., P. Markoulatos, G. Koptopulos, K. Nomikou, N. Bakandritso and O. Papadopoulos, 1999. Sheeppox virus identification by PCR in cell cultures. *J. Virol. Methods*, 77: 75-79.
- Mangana-Vougiouka, O., P. Markoulatos, G. Koptopulos, K. Nomikou, N. Bakandritsos and P. Papadopoulos, 2000. Sheeppox virus identification from clinical specimens by PCR, cell culture, immunofluorescence and agar gel immuno-precipitation assay. *Mol. Cel. Probes.*, 14: 305-310.
- Mariner, J.C., J.A. House, T.M. Wilson, M. Van Den Ende and I. Diallo, 1991. Isolation of sheeppox virus from a lamb in Niger. *Trop. Anim. Health Prod.*, 23: 27-28.
- Oğuzoğlu, T.C., F. Alkan, A. Ozkul, S.A. Vural, A.B. Güngör and I. Burgu, 2006. A sheeppox virus outbreak in Central Turkey in 2003: isolation and identification of capripoxvirus ovis. *Vet. Res. Comm.*, 30: 965-971.
- Rao, T.V. and S.K. Bandyopadhyay, 2000. A comprehensive review of goatpox and sheeppox and their diagnosis. *Anim. Health Res. Rev.*, 1: 127-136.
- Tulman, E.R., C.L. Alfonso, Z. Lu, L. Zsak, J.H. Sur, N.T. Sandybaev, U.Z. Kerembekova, V.L. Zaitsev, G.F. Kutish and D.L. Rock, 2002. The genomes of sheeppox and goatpox viruses. *J. Virol.*, 76: 6054-6061.
- World Organization for Animal Health, 2005-2006. In *Sheep and goatpox virus*. Annual Animal Health Information, Handistatus II.