

Diabetes Decreases Mast Cell Infiltration During the Acute Phase of the Active Arthus Reaction

P.M. Hernández-Mendoza, K.Y. Coronado-Manzanares, A.M. Nevárez-Garza,
L.E. Rodríguez-Tovar, G. Hernández-Vidal, J.A. Salinas-Meléndez and R. Ramírez-Romero
Departamento de Patología Veterinaria, Facultad de Medicina Veterinaria y Zootecnia,
UANL. Av. Lázaro Cárdenas 4600, Unidad Universitaria Mederos,
C.P. 64930, Monterrey, N.L. México

Abstract: Herein, we explored the number of infiltrating mast cells in the skin of diabetic rabbits during the acute phase of the inflammatory response induced by an active Arthus reaction. New Zealand Rabbits were divided in 5 groups ($n = 5/\text{group}$). One group served as control while the others were subjected to the reaction. Two Arthus groups (groups 1 and 2) received alloxan to induce diabetes 75 days before the hyperimmunization protocol. Diabetes was confirmed by blood glucose tests 48 h after alloxan injection and at the time of euthanasia. An agar immunodiffusion test showed that diabetics and non-diabetics (groups 3 and 4) had enough serum antibodies by the time of euthanasia. Rabbits were euthanized at 8 h (groups 1 and 3) and 24 h (groups 2 and 4). Controls (group 5, non-Arthus, non-diabetes) received saline and were killed at 24 h. Skin samples were fixed in Carnoy's solution and mast cells were identified employing a low pH toluidine blue stain. Mast cells were quantified per square millimetre and then, those degranulated cells were registered to obtain absolute values. An ANOVA test employing a completely random design and subsequently, a Tukey's w test were carried out. Arthus reaction influenced markedly mast cell infiltration. Although, diabetic animals had fewer mast cells than non-diabetics ($p < 0.05$), numbers of degranulated cells were similar among them ($p > 0.05$). Diabetes markedly decreases the infiltration of mast cells during the active Arthus reaction in the skin. However, their degranulation status is comparable with non-diabetics.

Key words: Diabetes, active arthus reaction, mast cells, acute phase

INTRODUCTION

Diabetes is considered the most important metabolic disease and diabetes-derived complications account for the highest health risk in medicine (Bonow and Gheorghiade, 2004). Although a persistent, non-healing inflammatory response is the hallmark in diabetes, a diminished neutrophilic infiltration occurs during the earlier phase of this tissue reaction (Goova *et al.*, 2001). These inflammatory abnormalities could be linked to other diabetic complications, such as microvascular alterations (Gilbert *et al.*, 2000), modified chemotactic and phagocytic activities in neutrophils (Goova *et al.*, 2001) and reduced mast cell infiltration (Diaz *et al.*, 2001; de Oliveira Barreto *et al.*, 2003).

Mast cells have been traditionally associated with the severe clinical manifestation of hypersensitivity reactions; however, it is now clear that these cells

intermingle inflammation, restoration and immune response (Rodríguez-Aguirre *et al.*, 2008). Their prominent influence depends on vasoactive molecules, enzymes and an array of cytokines, including TNF- α , which is stored preformed in mast cell granules (Abraham and Arock, 1998; Krishnaswamy *et al.*, 2001). It has been demonstrated that mast cells have an important role during initiation and progression of the Arthus reaction (Zhang *et al.*, 1991; Zweiman *et al.*, 1998; Baumann *et al.*, 2001).

The Arthus reaction is an immune-mediated inflammatory phenomenon induced originally in the skin of rabbits (Udaka, 1971). This phenomenon is considered a classical example of a type III, immune complex-mediated, hypersensitivity reaction (Udaka, 1971; Ramírez-Romero and Brogden, 2000; Baumann *et al.*, 2001). The characteristic lesions induced include a marked polymorphonuclear infiltration, vasculitis, oedema and

haemorrhage (Udaka, 1971; Baumann *et al.*, 2001). Mast cells are considered one of the main orchestrators of this inflammatory phenomenon (Zhang *et al.*, 1991; Baumann *et al.*, 2001).

The current study examines the density of mast cell and their activation status based on degranulation during the acute phase of the inflammatory response of the active Arthus reaction in the skin of diabetic rabbits.

MATERIALS AND METHODS

Animals and treatments: Twenty-five New Zealand white rabbits, both sexes, weighting approximately 2.0 kg at the beginning of experiment were maintained under conventional conditions and constant veterinary supervision. The research protocol was carried out following the guidelines of the Asociación Mexicana de Especialistas en Animales de Laboratorio. The animals were assigned to 5 groups (n = 5/group). Four groups were subjected to an active Arthus reaction. Previously, two of them received alloxan 75 days before receiving the hyperimmunization protocol (groups 1 and 2). Non-diabetics received saline (groups 3 and 4) before hyperimmunization. One group remained as control (group 5, non-diabetic, non-Arthus). Animals were killed at 8 (groups 1 and 3) and 24 h (groups 2, 4 and 5) after challenge.

Induction of diabetes: Diabetes was induced by injecting 150 mg kg⁻¹ of Alloxan (Sigma, St. Louis, Missouri, USA), endovenously. Controls received saline. Forty-eight hours after a blood glucose test was carried out (Ascencia, Elite, Bayer, México).

Induction of the active Arthus reaction: The hyperimmunization procedure was carried out with administration of three intramuscular injections (100 mg, each) of bovine serum albumin (BSA) (Sigma, St. Louis, Missouri, USA) diluted into 1.5 mL saline, with seven days intervals. An extra immunization was administered to diabetics to ensure a humoral immune response comparable to non-diabetics. Subsequently, animals were challenged intradermally with 200 µg of BSA diluted into 0.1 mL saline, injected in 2 sites of the dorsal skin.

Immunodiffusion test: An agar immunodiffusion test was carried out with serum samples obtained at the time of euthanasia from diabetic animals.

Collection of samples and histological procedures: Animals were killed with an overdose of sodium

pentobarbital at 8 and 24 h after induction of the Arthus reaction. Immediately after euthanasia the skin was excised and fixed in Carnoy's solution for 20 h at 4°C and then rinsed twice in absolute ethanol. After this, samples were routinely processed and sectioned at 4 µm and stained with a low pH toluidine blue to recognize mast cells easily (Ramírez-Hernández *et al.*, 2004). In addition, representative sections of each group were stained with H and E for routine observation.

Procedure for mast cell quantification: The skin sections stained with low pH toluidine blue were used to quantify the infiltrating mast cells. The two sites obtained from each rabbit were included in two different slides. Mast cells were counted in 20 high-power (× 400) fields, which are equivalent to 3.694 mm². The fields were randomly selected following a zigzag pattern of the superficial dermis. When the counts were completed all of the values obtained were adapted to mm². For degranulated cells the criteria was to include mast cells with metachromatic granules scattered in their immediate vicinity. The percentage of degranulated cells was established by counting 100 mast cells with higher magnification (× 1000). Then, the corresponding absolute value for each animal was adapted to mm². This procedure has been validated previously (Ramírez-Hernández *et al.*, 2004; Rodríguez-Aguirre *et al.*, 2008).

Statistical procedure: A two-sample t test for blood glucose levels including controls versus diabetics at 48 h after alloxan administration was utilised. Then a paired t test to compare the blood glucose level registered at 48 h versus level at time of euthanasia was carried out. An ANOVA test employing a completely random design was utilised for mast cell comparisons. After this, a Tukey's w procedure for multiple comparisons of means was carried out. The level of significance for all of the procedures was p = 0.05 or lower. The statistical software employed was Minitab for Windows.

RESULTS

Blood glucose test: Diabetic animals remained hyperglycaemic throughout the study as was demonstrated with the blood samples collected 48 h after alloxan administration and also by the time of euthanasia. Blood samples collected at 48 h after alloxan administration gave 474.75 (mean)±63.87 (standard deviation) whereas controls had 102.60±6.46. A two sample t test with the assumption of unequal variances demonstrated a strong difference (p = 0.0001).

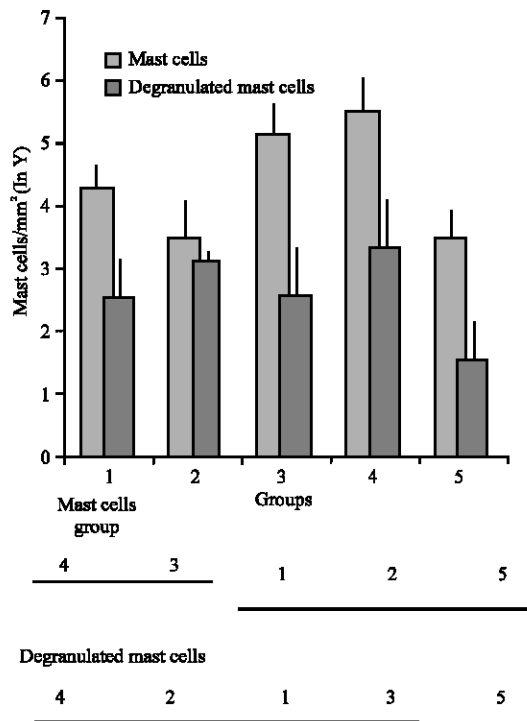


Fig. 1: Mast cells and degranulated mast cells values. A tukey's *w* test for means comparison showed that groups 4 and 3 (non-diabetics with Arthus at 24 and 8 h, respectively) had the higher numbers of mast cells in comparison with groups 1, 2 and 5 (diabetics with Arthus at 8 and 24 h and controls, respectively) ($p < 0.05$). However, when degranulated mast cells were compared, only the controls (group 5) had the lowest numbers of degranulated cells in comparison with all of the Arthus groups, either diabetics and non-diabetics ($p < 0.05$).

Subsequently, a paired *t* test carried out in diabetic animals at 48 h versus time of euthanasia (428.88 ± 78.01) demonstrated that hyperglycaemia prevailed throughout the study ($p > 0.05$).

Immunodiffusion test: The Ouchterlony's test showed that diabetics had serum antibodies enough for precipitation (titre 1:16). However, precipitation bands were more evident in non-diabetics.

Gross lesions and histopathology: All of the rabbits subjected to the active Arthus reaction showed the typical changes attributed to the reaction. The lesions were mostly characterised by severe oedema and eritema. Microscopically the changes were severe protein-rich

oedema accompanied by massive infiltration of polymorphonuclears. In some areas of the dermis, perivascular haemorrhages and vasculitis were present, but thrombosis was observed occasionally. No differences in severity were recognized between diabetics and non-diabetics. Controls showed no changes.

Quantification of mast cells: For valid statistical inference, natural logarithm transformation was required to make variance homogeneous among groups. The ANOVA showed strong differences among groups ($p = 0.001$). A subsequent comparison of the means using the Tukey's *w* procedure showed that only the non diabetics with Arthus (groups 3 and 4) had higher numbers of mast cells ($p < 0.05$) whereas diabetics with Arthus (groups 1 and 2) share similar values with controls (group 5) ($p > 0.05$). Degranulated cells were also compared employing the same procedures. ANOVA showed statistical differences among groups ($p = 0.005$). Subsequently, Tukey's *w* test showed that all of the Arthus groups, either diabetics or non-diabetics share similar values ($p > 0.05$) but different from controls ($p < 0.05$) (Fig. 1).

DISCUSSION

The Arthus reaction is considered the prototype model of immune-complexes mediated inflammatory diseases (Yanaba *et al.*, 2003). The relevance of mast cells during these kind of inflammatory reactions has been established (Udaka, 1971; Zweiman *et al.*, 1998; Kaburagi *et al.*, 2002; Yanaba *et al.*, 2003). In the experiment performed herein we determined the number of mast cells by squared millimetre and their reactivity status based on degranulation. It has been referred previously that cell degranulation is one of the most accurate evidence of mast cell reactivity (Ramírez-Hernández *et al.*, 2004). Furthermore, the influence of long-lasting hyperglycaemia on mast cell infiltration and degranulation was also evaluated in diabetic animals.

We explored the reaction between 8 and 24 h and established it as an early phase period based on a previous report by Kaburagi *et al.* (2002) who encountered that oedema, haemorrhage, neutrophils and mast cell infiltration peaked at 8 h after induction of an Arthus reaction. Additionally, Udaka (1971) determined that around 20-24 h the reaction begins to decline.

In this study we have clearly demonstrated that diabetes drastically decreases the number of mast cells infiltrating the skin of rabbits subjected to the reaction. Indeed, the trend is toward a progressive time-dependent

diminution. Our results are in accordance with previous studies that referred a deficiency in mast cell infiltration and reactivity in immune-complex models of inflammation in diabetic animals. For instance, reduced number and reactivity of mast cells were registered in the trachea, ileum and skin of diabetic rats subjected to an allergen-evoked model of inflammation (de Oliveira Barreto *et al.*, 2003). Additionally, airway reactivity was diminished and accompanied by fewer numbers of degranulated mast cells in the airways of diabetic rats sensitised to ovalbumin (Cavalher-Machado *et al.*, 2004). More recently, Carvalho *et al.* (2005) demonstrated that a reduction of mast cells in diabetic rats resulted in a weak allergic response despite their histamine content was unaffected. This alteration was associated with an increased glucocorticoid levels and a diminished pro-inflammatory influence of insulin (Carvalho *et al.*, 2005).

In the experiment presented herein, mast cells exhibit a higher degranulation status either in diabetics and non-diabetics subjected to the reaction. Degranulation of mast cells, probably the piecemeal way, is a stereotyped condition in acute inflammation (Ramírez-Hernández *et al.*, 2004). On this respect, Kaminer *et al.* (1995) confirmed that piecemeal degranulation of skin mast cells occurs as a natural process during activation. In addition, Dvorak (1998) proposed that piecemeal degranulation is a constitutive activity susceptible to be up regulated by a wide variety of stimulus. These arguments are in accordance with the fewer numbers of degranulated mast cells that we found in controls and the contrasting higher numbers in Arthus, with a discrete increased trend by 24 h. Apparently, diabetes markedly decreases the recruitment of mast cells but, contrary to previous reports (de Oliveira-Barreto *et al.*, 2003; Cavalher-Machado *et al.*, 2004), their degranulation reactivity remain unaffected.

We have recently reported that neither number of infiltrating mast cells nor degranulation were affected in rabbits with a seven days-lasting diabetes, subjected to a local Shwartzman reaction in the skin (Rodríguez-Aguirre *et al.*, 2008). It is possible that a longer hyperglycaemic period, such as the period described here, would be necessary to observe significant effects.

In the present experiment we considered the possibility that diabetics rabbits respond in a weaker manner to the antigen as has been reported in some papers (Ptak *et al.*, 1977; Gaulton *et al.*, 1985). On this respect, although diabetics showed a less defined precipitation line than non-diabetics, the reaction was evident and therefore, a comparable reaction could be expected *in vivo*. Nonetheless, we recognized a marked decrease in infiltrating mast cells. It has been reported that

despite a comparable humoral immune response *in vitro*, a decreased intensity in an allergen-induced respiratory reaction occurred in diabetics (Vianna and García-Leme, 1995).

The chemokines RANTES, MIP-1 α and MIP-2, as well as the cytokines TNF- α and IL-6 are included in the functional profile of activated murine mast cells obtained from foetal skin (Matsushima *et al.*, 2004). All of these mediators exert a pro-inflammatory scenario with capability to influence mast cells in an autocrine manner (Vianna and García-Leme, 1995; Abraham and Arock, 1998; Coward *et al.*, 2002). For instance, RANTES induces mast cell recruitment in the skin of mice as soon as 4 h after experimental inoculation (Conti *et al.*, 1998). Considering the relevance of mast cells in the whole process of inflammation-restoration, it is the most likely that limited numbers of mast cells at the beginning of the process explain, at least in part, the overall deficiency in diabetics.

CONCLUSION

Diabetes decreases the number of infiltrating mast cells in the skin of rabbits subjected to an active Arthus reaction but their degranulation status remains unaffected. Therefore, the deficiency during the acute phase of the inflammatory response in diabetes could be more quantitative than qualitative.

REFERENCES

- Abraham, S.N. and M. Arock, 1998. Mast cell and basophils in innate immunity. *Semin. Immunol.*, 10: 373-381.
- Baumann, U., N. Chouchakova, B. Gewecke, J. Köhl, M.C. Carroll, R.E. Schmidt and J.E. Gessner, 2001. Distinct tissue site-specific requirement of mast cell and complement components C3/C5a receptor in IgG immune complex-induced injury of skin and lung. *J. Immunol.*, 167: 1022-7.
- Bonow, R.O. and M. Gheorghiade, 2004. The diabetic epidemic: A national and global crisis. *Am. J. Med.*, 116 (5A): 2s-10s.
- Carvalho, V.F., E.O. Barreto, R.S.B. Cordeiro, V. Lagente, M.A. Martins and P.M.R. Silva, 2005. Mast cell changes in experimental diabetes: Focus on attenuation of allergic events. *Mem. Inst. Oswaldo Cruz*, 100 (Suppl. 1): 121-125.
- Cavalher-Machado, S.C., W. de Lima, A.S. Damazo, V. de Frias Carvalho, M.A. Martins, P.M. de Silva and P. Sannomiya, 2004. Down regulation of mast cell activation and airway reactivity in diabetic rats: Role of insulin. *Eur. Respir. J.*, 24: 552-558.

- Conti, P., M. Reale, R.C. Barbacane, R. Letourneau and T.C. Theoharides, 1998. Intramuscular injection of RANTES causes mast cell recruitment and increases transcription of histidine decarboxylase in mice: Lack of effects in genetically mast cell-deficient W/W^v mice. *FASEB. J.*, 12: 1693-1700.
- Coward, W.R., Y. Okayama, H. Sagara, S.J., Wilson, S.T. Holgate and M.K. Church, 2002. NF-kappa B and TNF-alpha: A positive autocrine loop in human lung mast cells? *J. Immunol.*, 169: 5287-5293.
- de Oliveira Barreto, E., V. de Frias Carvalho, B.L. Diaz, A. Balduino, R.S. Cordeiro, M.A. Martins and P.M. Rodríguez e Silva, 2003. Adoptive transfer of mast cells abolishes the inflammatory refractoriness to allergen in diabetic rats. *Int. Arch. Allergy Immunol.*, 131: 212-130.
- Diaz, B., E. Barreto, R. Cordeiro, M. Perretti, M. Martins and P.M. Rodríguez e Silva, 2001. Enhanced serum glucocorticoid levels mediate the reduction of serosal mast cell numbers in diabetic rats. *Life Sci.*, 68: 2925-2932.
- Dvorak, M.A., 1998. Histamine content and secretion in basophils and mast cells. *J. Histochem. Cytochem.*, 33: 169-328.
- Gaulton, G.N., J.L. Schuwartz and D.D. Eardley, 1985. Assessment of the diabetogenic drugs alloxan and streptozotocin as model for the study of immune defects in diabetic mice. *Diabetologia*, 28: 769-775.
- Gilbert, R.E., J.R. Rumble, A.J. Cao, P. van Eeden, T.J. Allen, D.J. Kelly and M.E. Cooper, 2000. Endothelium receptor antagonism ameliorates mast cell infiltration, vascular hypertrophy and epidermal growth factor expression in experimental diabetes. *Circ. Res.*, 86: 158-165.
- Goova, M.T., J. Li, T. Klislinger, W. Qu, Y. Lu, L.G. Bucciarelli, S. Nowygrod, B.M. Wolf, X. Caliste, S.F. Yan, D.M. Stern and A.M. Schmidt, 2001. Blockade of receptor for advanced glycation end-products restores effective wound healing in diabetic mice. *J. Pathol.*, 159: 513-525.
- Kaburagi, Y., M. Hasegawa, T. Nagaoka, Y. Shimasa, Y. Hamaguchi, K. Kazuhiro, E. Saito, K. Yanaba, K. Takehara, K. Takafumi, A.D. Steeber, T.F. Tedder and S. Sato, 2002. The cutaneous reverse Arthus reaction requires intercellular adhesion Molecule 1 and L-selectin expression. *J. Immunol.*, 168: 2970-2978.
- Kaminer, M.S., G.F. Murphy, B. Zweiman and R.M. Lavker, 1995. Connective tissue mast cell exhibit time-dependent degranulation heterogeneity. *Clin. Diagn Lab Immunol.*, 2: 297-301.
- Krishnaswamy, G., J. Kelley, D. Johnson, G. Youngberg, W. Stone, S-K. Huang, J. Bieber and D.S. Chi, 2001. The human mast cell: Functions in physiology and disease. *Front. Biosci.*, 6: 1109-1127.
- Matsushima, H., N. Yamada, H. Matsue and S. Shimada, 2004. TLR3-, TLR7- and TLR9-mediate production of proinflammatory cytokines and chemokines from murine connective tissue type skin-derived mast cells but not from bone marrow derived mast cells. *J. Immunol.*, 173: 531-514.
- Ptak, W., M. Hanczakowska, R. Rozycka and D. Rozycka, 1977. Impaired antibody responses in alloxan diabetic mice. *Clin. Exp. Immunol.*, 29: 140-146.
- Ramírez-Hernández, C., G. Hernández-Vidal, A. Wong-González, E. Gutiérrez-Ornelas, M.R. Ackermann and R. Ramírez-Romero, 2004. Mast cell density during initiation and progression of the local Shwartzman reaction. *J. Inflamm. Res.*, 53: 107-110.
- Ramírez-Romero, R. and K.A. Brogden, 2000. The potential role of the Arthus and Shwartzman reactions in the pathogenesis of pneumonic pasteurellosis. *Inflamm. Res.*, 49: 98-101.
- Rodríguez-Aguirre, A.C., C.F. Rodríguez-Ortega, A.M. Nevárez-Garza, L.E. Rodríguez-Tovar, G. Hernández-Vidal and R. Ramírez-Romero, 2008. Short-term diabetes has no influence on mast cell infiltration and reactivity during the local Shwartzman reaction. *J. Anim. Vet. Adv.*, 7: 264-268.
- Udaka, K., 1971. The Arthus reaction. In: *Moviat HZ. Inflammation, Immunity and Hypersensitivity*. 1st Edn. New York, pp: 389-423.
- Vianna, E.O. and J. Garcia Leme, 1995. Allergen-induced airway inflammation in rats. Role of insulin. *Am. J. Respir Crit. Care. Med.*, 151: 809-814.
- Yanaba, K., Y. Kaburagi, K. Takehara, D.A. Steeder, T.F. Tedder and S. Sato, 2003. Relative contributions of selectins and intercellular adhesion molecule-1 to tissue injury induced by immune complex deposition. *Am. J. Pathol.*, 162: 1463-1473.
- Zhang, Y., B.F. Ramos and B.A. Jakschik, 1991. Augmentation of reverse Arthus reaction by mast cell in mice. *J. Clin. Invest.*, 88: 841-846.
- Zweiman, B., A.R. Moskovitz and C. Allmen, 1998. Comparison of inflammatory events during developing immunoglobulin E- mediated late-phase reactions and delayed-hypersensitivity reactions. *Clin. Diagn. Lab. Immunol.*, 5: 574-577.