

## Quantification of Mast Cells During Initiation and Progression of the Active Arthus Reaction

K. Y. Coronado-Manzanares, A.M. Nevárez-Garza, L.E. Rodríguez-Tovar,  
A. Wong-González, G. Hernández-Vidal, J.A. Salinas-Meléndez and R. Ramírez-Romero  
Departamento de Patología, Facultad de Medicina Veterinaria y Zootecnia,  
UANL. Av. Lázaro Cárdenas 4600, Unidad Universitaria Mederos,  
C.P. 64930, Monterrey, N.L., México

**Abstract:** Mast cells numbers and reactivity status based on their degranulation was determined in the skin of rabbits during the initiation and progression of the active Arthus reaction. New Zealand Rabbits divided in three groups (n = 5/group) were subjected to the reaction and killed at three different time periods. Briefly, the animals received three immunizations (seven days intervals) with bovine serum albumin intramuscularly and a challenge seven days apart intradermally. Animals were euthanized at 8 h, 24 h and 8 days, post challenge. One group served as control (saline for immunization and challenge) and was killed at 24 h. Skin samples were fixed in Carnoy's solution and mast cells were identified employing a low pH toluidine blue stain. Numbers of mast cells were identified per square millimetre and, subsequently, those cells degranulated were identified and quantified to obtain absolute values. The values were transformed (natural logarithms) for appropriate statistical comparisons. An ANOVA test using a completely random design and a Tukey's w test were carried out. The numbers of infiltrating mast cells were significantly different in all of the Arthus groups in comparison with controls ( $p < 0.05$ ). Although, all of the Arthus groups had higher values of degranulated cells, only group at 24 h was significantly different from controls. It was concluded that mast cells have a prominent role during the early and late phases of this inflammatory model.

**Key words:** Active arthus reaction, mast cells, degranulation, quantification

### INTRODUCTION

The Arthus reaction is an immune-mediated inflammatory phenomenon induced originally in the skin of rabbits (Udaka, 1971). This experimental model is considered a classical example of a type III, immune complex-mediated, hypersensitivity reaction. The characteristic lesions induced include a marked polymorphonuclear infiltration, vasculitis, oedema and haemorrhage (Ramírez-Romero and Brogden, 2000; Baumann *et al.*, 2001). Mast cells are considered the orchestrators of the Arthus reaction (Zhang *et al.*, 1991; Ramírez-Romero and Brogden, 2000; Baumann *et al.*, 2001). More recently, it has been demonstrated that C3, originally thought to be an important component of this immune-mediated reaction, has not a real preponderance in the initiation of this reaction in the skin (Baumann *et al.*, 2001).

Mast cells have been traditionally associated with the severe clinical manifestations of the hypersensitivity reactions; however, it is now clear that these cells intermingling the inflammatory reaction, the

tissue restoration and the immune response (Rodríguez-Aguirre *et al.*, 2008). Their prominent influence depends on vasoactive molecules, enzymes and an array of cytokines, including TNF- $\alpha$ , which is stored preformed in mast cell granules (Abraham and Arock, 1998; Krishnaswamy *et al.*, 2001). It has been demonstrated that mast cells have an important role during initiation and progression of the Arthus reaction in the skin (Zhang *et al.*, 1991; Zweiman *et al.*, 1998; Baumann *et al.*, 2001).

The current study examines the density of mast cell and their activation status based on degranulation throughout initiation and progression of the active Arthus reaction in the skin of rabbits.

### MATERIALS AND METHODS

**Animals and treatments:** Twenty New Zealand White rabbits, both sexes, weighting approximately 2.6 kg at the beginning of experiment were maintained under conventional conditions and constant veterinary supervision. The research protocol was carried out

following the guidelines of the Asociación Mexicana de Especialistas en Animales de Laboratorio. The animals were assigned to four groups ( $n = 5/\text{group}$ ). Three groups were subjected to an active Arthus reaction and euthanized at 3 different times 8, 24 h and 8 days after challenge. The other group was control and killed at 24 h.

**Induction of the active arthus reaction:** The hyperimmunization procedure was carried out with administration of 3 intramuscular injections (100 mg, each) of bovine serum albumin (BSA) (Sigma, St. Louis, Missouri, USA) diluted into 1.5 mL saline, with seven days intervals. Subsequently, animals were challenged intradermally with 200  $\mu\text{g}$  of BSA diluted into 0.1 mL saline, injected in 2 sites of the dorsal skin, seven days after.

**Collection of samples and histological procedures:** Animals were killed with an overdose of sodium pentobarbital at 8 h, 24 h and 8 days after induction of the Arthus reaction. Immediately after euthanasia the skin was excised and fixed in Carnoy's solution for 20 h at 4°C and then rinsed twice in absolute ethanol. After this, samples were routinely processed and sectioned at 4  $\mu\text{m}$  and stained with a low pH toluidine blue to recognize mast cells easily (Ramírez-Romero *et al.*, 2000; Rodríguez-Aguirre *et al.*, 2008). In addition, representative sections of each group were stained with H and E for routine observation.

**Procedure for mast cell quantification:** The skin sections stained with low pH toluidine blue were used to quantify the infiltrating mast cells. The 2 sites obtained from each rabbit were included in two different slides. Mast cells were counted in 20 high-power ( $\times 400$ ) fields, which are equivalent to 3.694  $\text{mm}^2$ . The fields were randomly selected following a zigzag pattern of the superficial dermis. When the counts were completed all of the values obtained were adapted to  $\text{mm}^2$ . For degranulated cells the criteria was to include mast cells with metachromatic granules scattered in their immediate vicinity. The percentage of degranulated cells was established by counting 100 mast cells with higher magnification ( $\times 1000$ ). Then, the corresponding absolute value for each animal was adapted to  $\text{mm}^2$ . This procedure has been validated previously (Ramírez-Romero *et al.*, 2000; Rodríguez-Aguirre *et al.*, 2008).

**Statistical procedure:** An ANOVA test employing a completely random design was utilized. After this, a Tukey's *w* procedure for multiple comparisons of means was carried out. The level of significance for all of the procedures was  $p = 0.05$  or lower. The statistical software employed was Statistix for Windows version 1996.

## RESULTS

**Gross lesions and histopathology:** All of the rabbits subjected to the active Arthus reaction showed the typical changes attributed to the model. The lesions were mostly characterised by severe oedema and eritema. One animal showed marked haemorrhage. All of the lesions disappeared by the last time period (8 days). Microscopically, the changes were severe protein-rich oedema accompanied by massive infiltration of polymorphonuclears. In some areas of the dermis, perivascular haemorrhages and vasculitis were present, but thrombosis was observed occasionally. The changes were more severe by 24 h after challenge. Nonetheless, most of the changes remained until 8 days but were discrete. Controls showed no changes.

**Quantification of mast cells:** For valid statistical inference, natural logarithm transformation was required to make variance homogeneous among groups. The ANOVA showed higher significance ( $p < 0.001$ ) demonstrating strong differences among groups. A subsequent comparison of the means using the Tukey's *w* procedure showed that the unique group different from all of the rest was the control ( $p < 0.05$ ), whereas the rest shared similarities ( $p > 0.05$ ). Degranulated cells were also

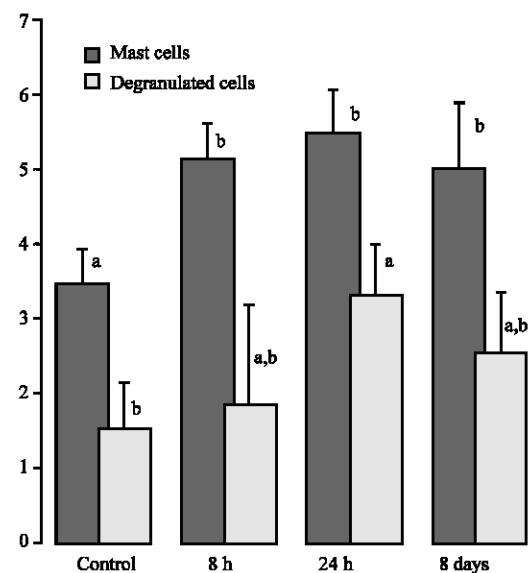


Fig. 1: Comparison of mast cell numbers (natural logarithm values) during early and late phases of the active Arthus reaction. There are no differences among mast cells during the evolution of the Arthus reaction. However, control group has significantly fewer mast cells. Degranulated cells were different from control only at 24 h (Tukey's test,  $p < 0.05$ )

compared employing the same procedures. ANOVA analysis showed statistical differences among groups ( $p < 0.05$ ). However, means comparison by Tukey's *w* test showed that only group at 24 h was really different from control ( $p < 0.05$ ) (Fig. 1).

## DISCUSSION

Despite the relevance of mast cells during the immune complexes-mediated hypersensitivity reactions (Udaka, 1971; Zweiman *et al.*, 1998; Kaburagi *et al.*, 2002; Yanaba *et al.*, 2003), to our knowledge, there are no data concerned with the quantification of mast cells during the initiation and progression of the Active Arthus reaction. This work refers to a quantitative profile of infiltrating mast cells during the early and late phases of this experimental induced phenomenon considered a prototype of the immune complex-mediated hypersensitivity reactions (Yanaba *et al.*, 2003).

Zweiman *et al.* (1998) encountered that mast cell activation is already markedly increased at 5 h of initiated an immune-mediate inflammatory reaction. However, Kaburagi *et al.* (2002) encountered that oedema, haemorrhage, neutrophils and mast cell infiltration peaks at 8 h. For that reason we explored the reaction at 8 h and considered it an early phase of the reaction. On the other hand, Udaka (1971) says that the reaction begins to decline between 20-24 h after induction; thus we considered this time point as the late phase of the Arthus reaction. Furthermore, our study also determines the status of mast cell activation based on degranulation. It has been referred previously that cell degranulation is one of the most accurate evidence of mast cell activity (Ramírez-Hernández *et al.*, 2004).

Although, infiltration of mast cells resulted statistically similar among early and late phases and inclusively, at 8 days, all of the Arthus groups were statistically different from control. It is the most likely that conditions favouring mast cell infiltration remain in this pro-inflammatory milieu. On this respect, adhesion molecules such as vascular selectins E and P and ICAM-1 are necessary for the accumulation of mast cells during initiation and progression of the Arthus reaction (Kaburagi *et al.*, 2002; Yanaba *et al.*, 2003). The apparent decline tendency of infiltrating mast cells by 8 days has to be confirmed in studies including longer time periods.

With respect to mast cell degranulation, we observed a tendency in accordance with density at each time point; however, in this case, the numbers of degranulated cells were statistically different from controls only at 24 h. We originally expected increased numbers of degranulated

cells at the earlier phase of the Arthus reaction but they remained with values statistically similar during all time periods. Massive and immediate degranulation has been attributed to anaphylactoid reactions (Kaminer *et al.*, 1995). Conversely, piecemeal and slow degranulation has been reported in various chronic processes and during wound healing (Dvorak and Kissell, 1991; Kaminer *et al.*, 1995). Nevertheless, Kaminer *et al.* (1995) encountered that even during an IgE-mediated reaction, piecemeal degranulation occurs and this is probably a natural process during mast cell activation. In our study, mast cells appeared degranulated even until 8 days and this was probably in accordance with piecemeal degranulation. Moreover, the slight decline in their numbers appearing by 8 days seems to be also a natural condition attributed to antigen decay. It has been widely accepted that the role of mast cells in wound healing is preponderant (Abraham and Arock, 1998) and in our study, the increased number of degranulated cells by the considered late phase of the reaction, seems in accordance with the beginning of the healing process. Obviously, conditions to stimulate mast cell degranulation remain during all of the process and the major influence could be a stimulation of the low affinity IgG receptor III (FcγRIII). It has been widely demonstrated that this low affinity Fc receptor and the complement fraction C5a receptor (C5aR) are required on mast cell surface for a complete expression of the inflammatory phenomenon during an Arthus reaction (Baumann *et al.*, 2001; Yuasa *et al.*, 2001).

## CONCLUSION

Our experiment confirms the preponderant role of mast cells during this classical immune-mediated type III hypersensitivity model, the active Arthus reaction.

## REFERENCES

- Abraham, S.N. and M. Arock, 1998. Mast cell and basophils in innate immunity. *Seminars in Immunol.*, 10: 373-381.
- Baumann, U., N. Chouchakova, B. Gewecke, J. Köhl, M.C. Carroll, R.E. Schmidt and J.E. Gessner, 2001. Distinct tissue site-specific requirement of mast cell and complement components C3/C5a receptor in IgG immune complex-induced injury of skin and lung. *J. Immunol.*, 167: 1022-1027.
- Dvorak, M.A. and S. Kissell, 1991. Granule changes of human skin mast cells characteristic of piecemeal degranulation and associated with recovery during wound healing in situ. *J. Leuk. Biol.*, 49: 197-210.

- Kaburagi, Y., M. Hasegawa, T. Nagaoka, Y. Shimasa, Y. Hamaguchi, K. Kazuhiro, E. Saito, K. Yanaba, K. Takehara, K. Takafumi, A.D. Steeber, T.F. Tedder and S. Sato, 2002. The cutaneous reverse Arthus reaction requires intercellular adhesion Molecule 1 and L-selectin expression. *J. Immunol.*, 168: 2970-2978.
- Kaminer, M.S., G.F. Murphy, B. Zweiman and R.M. Lavker, 1995. Connective tissue mast cell exhibit time-dependent degranulation heterogeneity. *Clin. Diagn. Lab. Immunol.*, 2: 297-301.
- Krishnaswamy, G., J. Kelley, D. Johnson, G. Youngberg, W. Stone, S-K. Huang, J. Bieber and D.S. Chi, 2001. The human mast cell: functions in physiology and disease. *Frontiers Biosci.*, 6: 1109-1127.
- Ramírez-Hernández, C., G. Hernández-Vidal, A. Wong-González, E. Gutiérrez-Ornelas, M.R. Ackermann and R. Ramírez-Romero, 2004. Mast cell density during initiation and progression of the local Shwartzman reaction. *J. Inflamm. Res.*, 53: 107-110.
- Ramírez-Romero, R. and K.A. Brogden, 2000. The potential role of the Arthus and Shwartzman reactions in the pathogenesis of pneumonic pasteurellosis. *Inflamm. Res.*, 49: 98-101.
- Ramírez-Romero, R., K.A. Brogden, J. Gallup, R.A.F. Dixon and M.R. Ackerman, 2000. Reduction of pulmonary mast cell in caves with *Mannheimia (Pasteurella) haemolytica* pneumonia. *J. Comp. Path.*, 123: 29-35.
- Rodríguez-Aguirre, A.C., C.F. Rodríguez-Ortega, A.M. Nevárez-Garza, L.E. Rodríguez-Tovar, G. Hernández-Vidal and R. Ramírez-Romero, 2008. Short-term diabetes has no influence on mast cell infiltration and reactivity during the local Shwartzman reaction. *J. Anim. Vet. Sci.*, 7: 264-268.
- Udaka, K., 1971. The Arthus Reaction. In: Movat HZ. *Inflammation, Immunity and Hypersensitivity*. 1st Edn. New York, pp: 389-423.
- Yanaba, K., Y. Kaburagi, K. Takehara, D.A. Steeder, T.F. Tedder and S. Sato, 2003. Relative contributions of selectins and intercellular adhesion molecule-1 to tissue injury induced by immune complex deposition. *Am. J. Pathol.*, 162: 1463-1473.
- Yuasa, K., M. Ono, T. Watanabe and T. Takai, 2001. Lyn is essential for Fcγ receptor III-mediated systemic anaphylaxis but not for the Arthus reaction. *J. Exp. Med.*, pp: 563-571.
- Zhang, Y., B.F. Ramos and B.A. Jakschik, 1991. Augmentation of reverse Arthus reaction by mast cell in mice. *J. Clin. Invest.*, 88: 841-846.
- Zweiman, B., A.R. Moskovitz and C. Allmen, 1998. Comparison of inflammatory events during developing immunoglobulin E- mediated late-phase reactions and delayed-hypersensitivity reactions. *Clin. Diagn. Lab. Immunol.*, 5: 574-577.