

B-Mode Real-Time Ultrasonography for Pregnancy Diagnosis and Fetal Number in Saanen Goats

¹R.M. Abdelghafar, ¹A.O. Bakhiet and ²B.H. Ahmed

¹College of Veterinary Medicine and Animal Production,

Sudan University of Science and Technology, P.O. Box 204 Khartoum-North, Khartoum, Sudan

²Faculty of Radiological Science and Nuclear Medicine, National Ribat University, Khartoum, Sudan

Abstract: Early pregnancy detection in goats was not practicable in the country until now. The present study evaluated the use of ultrasonography in detecting pregnancy and determining fetal number in a flock of Saanen goats. Thirty one dairy Saanen does aged between 7-31 months were used in the study, they were housed and managed at the main center of the Goat improvement project, Ministry of Agriculture, Animal Resources and Irrigation, Khartoum state, Sudan. Estrus was carefully observed and each doe was naturally mated twice at the 1st and 2nd day of estrus, thus the first day of estrus was designated as day 0 of gestation. B- Mode Real-time ultrasonography was performed starting from day 26-110 of gestation using Fukuda, Denchi, Japan equipped with 3.5 MHz extra abdominal curvilinear transducer. The accuracy of ultrasound in detecting pregnancy was 100% for both positive and negative cases. The accuracy of ultrasound in determining single, twins and triplets was 88.2, 77.7 and 50%, respectively. In conclusion B- Mode Real-time ultrasound was found to be accurate, safe and non-time consuming method for detecting pregnancy and estimating fetal number in Saanen goats.

Key words: B-mode real-time, ultrasonography, fetal number, saanen goats

INTRODUCTION

Ultrasonography has rapidly become established as one of the principal imaging techniques used in veterinary practice (Goddard, 1994). B-mode real-time ultrasonography is used primarily in sheep and goats for pregnancy diagnosis and estimation of fetal number (Griffin and Ginther, 1992; Russel and Goddard, 1995). It was available since 1980s, initially considered too time-consuming and expensive but has proved to be a reliable means of pregnancy detection in a number of domestic species regarding pregnancy status, number of fetuses and gestational age (Haibel, 1990). The early and precise detection of pregnancy in sheep is especially important from economic point of view, the separation of the flock into pregnant and non-pregnant permits scheduling of the technology of breeding (Yotov, 2005). In Sudan ultrasound is not yet adopted as a diagnostic tool in the clinics, only one study have been done in pregnancy diagnosis in Saanen goats (Abdelghafar, 2006).

The aim of the present study was to diagnose pregnancy, estimate fetal number and to determine fetal sex.

MATERIALS AND METHODS

Animals: Thirty one dairy Saanen goats aged between 7-31 months were used in the study. They were housed and managed within the premises of the Center for Goat Improvement Project at Hilat Kuku, Khartoum North. Fifteen of them were null parous, the remainder were multiparous. They were fed (*Medicago Sativa*) twice a day and concentrates (1/2 kilo per day each doe), with free access to water and minerals supplement. Estrus was carefully observed and every doe was naturally mated twice at the 1st and 2nd day of estrus, thus the first day of estrus was designated as day 0 of gestation. The experiment extended from July 2005- March 2006.

Ultrasound scanning: Animals were fasted for 14 h prior to the scanning; area of scanning was clipped shaved carefully. Animals were layed on their backs (dorsal recumbency) and well restrained on a flat table, a pillow was used as a cushion for their prominent spine.

Area of scanning extends across the width of the abdomen, passing from one side of the udder across in front of the udder, to the other side 15 cm anterior to the

udder. Liberal amount of coupling gel sonogel® Vertriebs was administered to the area to provide good contact with the skin. Real time ultrasound scanner (Fukuda Denshi, Co, Ltd. Japan) with 3.5 MHz extra abdominal curvilinear transducer was used in the study.

The transducer was held in a sagittal plane and moved in a systematic w-shaped searching pattern from one side of the abdomen to the other, when pregnancy confirmed then cross and oblique sections were taken,

Statistical analysis: Data was subjected to chi square analysis correlation as described by (Gomez and Gomez 1984). The Statistical Packages for Social Sciences (SPSS) program Version 11.5 was used for the analysis.

RESULTS

Ultrasound findings: The accuracy of ultrasound (US) in pregnancy diagnosis was 100% for both positive (29) cases and negative (2) cases, this was confirmed at delivery. Animal was considered pregnant when fluid-filled (GS) in the uterus (Fig. 1) and/or cotyledons (Fig. 2) and/or fetal parts (Fig. 3) and (Fig. 4) were recognized.

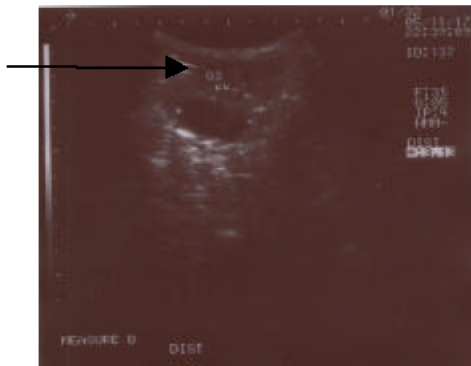


Fig. 1: Gestational sac (arrow head)

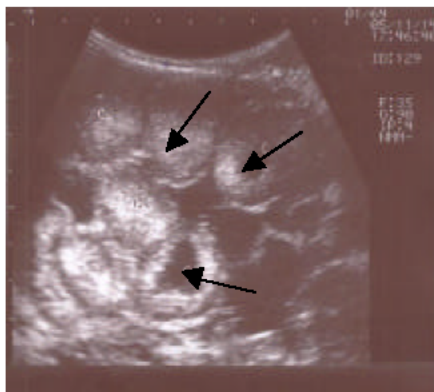

Fig. 2: Cotyledons at day 87 of gestation

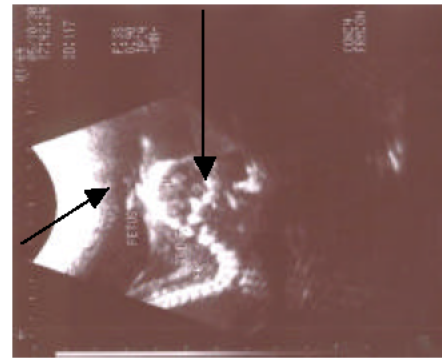


Fig. 3: Fetal head and spine

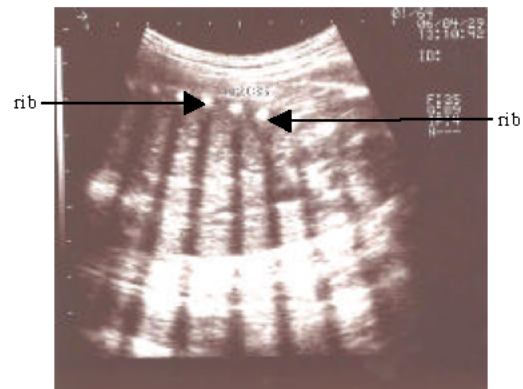


Fig. 4: Fetal rib cage realize distal acoustic shadowing

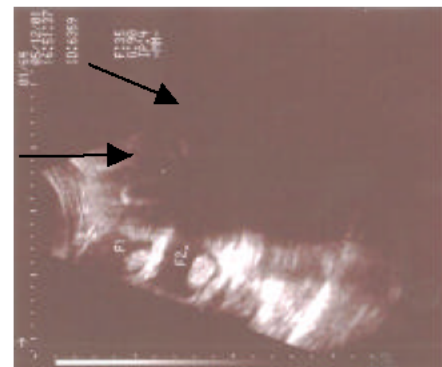


Fig. 5: Twins at day 38 of gestation (arrows)

Concerning fetal number, the overall accuracy of (US) in detecting fetal number was 79.3%, the correlation coefficient between US and fetal number was found to be highly significant ($r = 0.742$). The accuracy of detecting single fetuses was 83.3%, the accuracy of detecting twins was 77.7%. The accuracy of detecting triplets was 50%, out of 2 cases only one case was correctly diagnosed as bearing triplets.

DISCUSSION

In the present study the accuracy of ultrasound was 100% for detecting pregnant (29) cases and non-pregnant (2) cases, this is in agreement with Medan *et al.* (2004) who found 100% accuracy and Gonzalez *et al.* (2004) who found 98.7 accuracy. Concerning fetal number; the over all accuracy of ultrasound was 79.3%, the accuracy for detecting singles and twins were 83.8 and 77.7%, respectively. The accuracy for detecting triplets was 50% out of 2 does bearing triplets one was incorrectly diagnosed as bearing twins; Padilla-Rivas *et al.* (2005) reported that in Boer goats more than two kids some times are difficult to identify. Geol and Agrawal (1992) reported that it is difficult to differentiate between twins and triplets or quadruplets at any stage of gestation while Karen *et al.* (2001) reported that the accuracy of ultrasound in detecting ewes carrying two fetuses or more was disappointing. Mc Gahan and Coats (1996) reported that multiple pregnancies should be reported in those instances where multiple embryos are seen, due to variability in fusion between the amnion and the chorion. The appearance of more than one sac-like structure in early pregnancy is often noted and may be confused with multiple gestations. Regarding fetal sex the ultrasound was the only method to detect fetal sex. In our opinion the accuracy of determining fetal sex depends on the position of the fetus and the skill of the sonographer. Although this study was the first of its kind to be done in Sudan, high accuracies were obtained due to the good technique we adopted and good preparation of the animal. Adequate fasting of the animal helps to evacuate the Gastrointestinal Tract (GIT) from gases which is seemed to be the enemy of sound waves transmission. Careful shaving and clipping provided good contact between the probe and the patient. Karen *et al.* (2004) found the sensitivity of ultrasound scanning for early pregnancy in ewes by using 5 MHz transrectal transducer, was 21.8, 32.3, 63.3 and 50% at days 18-24, 25-30, 31-40 and 41-50, respectively, without fasting and lifting the abdominal wall where as it was 46, 92.5, 92.3 and 96.8% with fasting 12 h prior to the scanning and lifting of the abdominal wall. Dorsal recumbency provided good convenience for the operator and with the use of the pillow it also provides a convenience for the animal. Using extra abdominal approach provided ample area of scanning (approximately 15 cm); also 3.5 MHz transducer provided good penetration. On conclusion; where the necessary equipment and skills of the sonologist are available, Real-time B-Mode ultrasound is a convenient, rapid, non-invasive and reliable mean of pregnancy diagnosis in Saanen goats. Preparing of a cradle with special design for the positioning of the animal is recommended.

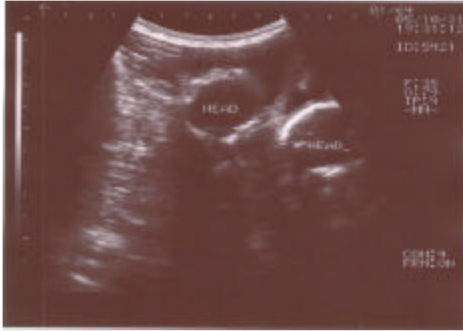

Fig. 6: Twins at day 60 of gestation

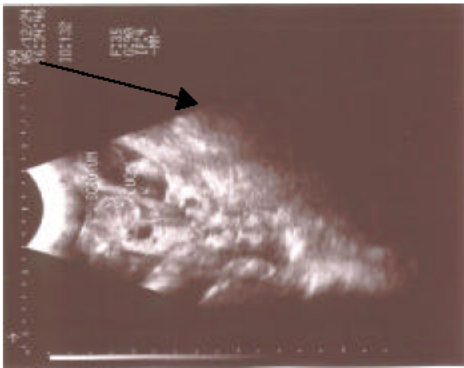


Fig. 7: Male fetus realize the scrotum (arrow)

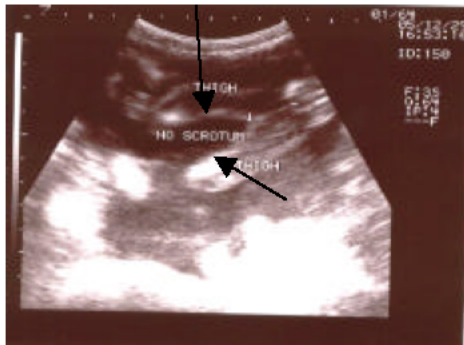

Fig. 8: Female fetus, realize the two thigh (arrows)

The animal was designated as bearing twins when two heads and/or two beating hearts and/or two bodies were recognized (Fig. 5 and 6). All fetuses were viable according to their movements or heart beats.

Regarding fetal sex out of four fetuses two fetuses were diagnosed as male and one fetus as female. The fetus was considered male (Fig. 7) when scrotum and/or penis was recognized and the fetus considered female when there is no scrotum between the hind limb (Fig. 8).

ACKNOWLEDGEMENT

The authors would like to thank Police Dog Administration, Ministry of Interior for providing the ultrasound machine (FUKUDA). And Ministry of Agriculture, Animal Resources and Irrigation, Khartoum State, Sudan for providing the experimental animals.

REFERENCES

- Abdelghafar, R.M., 2006. B- Mode real time ultrasonography for pregnancy diagnosis and fetometry in Saanen goats. M. Sc. Thesis, Sudan Univ. Sci. Tech., pp: 71.
- Goddard, P.J., 1994. In *Veterinary ultrasonography* (1995). Cab International. Wallingford, Oxon. OX108DE. UK.
- Goel, A.K. and K.P. Agrawal, 1992. A review of pregnancy diagnosis techniques in sheep and goats. *Sm. Rumin. Res.*, 9: 255-264.
- Gomez, K.A and A.A. Gomez, 1984. *Statistical Procedure for Agricultural Research*, (2nd Edn.), Wiley and Sons Inc.
- Gonzalez, F., F. Cabrera, M. Batista, N. Rodriguez, D. Alamo, J. Sulon, J. Beckers and G. Anselmo, 2004. A comparison of diagnosis of pregnancy in the goat via transrectal ultrasound scanning, progesterone and pregnancy-associated glycoprotein assays. *Theriogenology*, 62: 1108-1115.
- Griffin, P.G. and O.J. Ginther, 1992. Research applications of ultrasonic imaging in Reproductive Biology. *J. Anim. Sci.*, 70: 953-972.
- Haibel, G.K., 1990. Use of ultrasonography in reproductive management of sheep and goat herds. *Vet. Clin. North Am. Food Anim. Pract.*, 6: 597-613.
- Karen, A., P. Kovacs, J.F. Beckers and O. Szenci, 2001. Pregnancy diagnosis in sheep: Review of the most practical methods. *Acta.Vet. Brno.*, 70: 115-126.
- Karen, A., K.K. Szabados, J. Reiczigel, J.F. Beckers and O. Szenci, 2004. Accuracy of transrectal ultrasonography for determination of pregnancy in sheep: Effect of fasting and handling of the animals. *Theriogenology*, 61: 1291-1298.
- Mc Gahan, J.P. and T.L. Coates, 1996. *Obstetrical Ultrasound: Normal Anatomy and Measurements*. In: Goldberg, B. B. and Pettersson, H. In the Nicer Year Book *Ultrasonography*, Elanders Norge AS. Oslo, pp: 307-340.
- Medan, M., G. Watnabe, G. Absy, K. Sasaki, S. Sharaw and K. Taya, 2004. Early pregnancy diagnosis by means of ultrasonography as a method of improving reproductive efficiency in goats. *J. Reprod. Dev.*, 50: 4.
- Padilla-Rivas, G.R., B. Sohnrey and W. Holtz, 2005. Early pregnancy detection by real-time ultrasonography in Boer goats. *Sm. Rumin. Res.*, 58: 87-92.
- Russel, A.J. and P.J. Goddard, 1995. *Small Ruminant Reproductive Ultrasonography*. In: Goddard, P.J. *Veterinary Ultrasonography*. Cab International Wallingford, Oxon OX108DE UK, pp: 257-274.
- Yotov, S., 2005. Diagnostics of early pregnancy in Stara Zagora dairy sheep breed. *Bulgarian J. Vet. Med.*, 8: 41-45.