

## Evaluation of the Effect of Anthelmintic Agents Albendazole, Fenbendazole and Praziquantel in Treatment of Coenurosis Disease in Sheep

Ciamak Ghazaei

Department of Veterinary Microbiology, Mohaghegh Ardabil University, Iran

**Abstract:** Coenurosis is a rare infection caused by the larval stage of the tapeworm (also referred to as *Coenurus Cerebralis*) *Taenia Multiceps*, a Platyhelminth in the class Cestoda. These adults of *Taenia* spp. live in the intestines of dogs and other canines and pass eggs which are then ingested by grazing animals, usually sheep. Oncospheres escape from the eggs and form coenuri in various tissues. Localization in the CNS of sheep causes the Coenurosis or staggers. In this survey Anthelmintic agents (albendazole, praziquantel, fenbendazole) was tested against coenurosis in naturally infected sheep at a different dose. The autopsy revealed calcification of the cysts in the brains of treated animals while the cysts in the untreated sheep were apparently still alive. This study showed that the best result arrived by using of albendazole with dosage 25 mg kg<sup>-1</sup> and Albendazole is considered the drug of choice.

**Key words:** coenurosis, *coenurus cerebralis*, sheep, *T. multiceps*

### INTRODUCTION

In certain, some areas of the World, coenurosis is one of the most common causes of disease of the Central Nervous System (CNS) in sheep that is also called Gid and Stagger<sup>[1,2]</sup> The real prevalence of coenurosis is difficult to assess, because farmers and veterinary surgeons often diagnose the disease and send the animal for slaughter without confirmation or report. A large proportion of infected lambs may also be sold fat before clinical signs have developed. Usually this is a condition seen in the older lamb and adult sheep due to *Coenurus cerebralis*, the cystic larval stage or metacestode of the dog tapeworm *Taenia multiceps*. The life of *T. multiceps* depends on the ingestion of the larval stage by the carnivore (dogs or other canids)<sup>[1,3,4]</sup> Following ingestion of grass contaminated with eggs, embryos burrow their way through the intestinal wall and reach the brain via the bloodstream. Once in the brain a cyst develops taking several months to grow to a size which will result in the appearance of clinical signs. The fully developed coenurus may be 5-6 cm in diameter and cause increased intracranial pressure, which results in ataxia, hypermetria, blindness, head deviation, headache, stumbling and paralysis<sup>[1,3,4]</sup>.

Sheep or sometimes goats, deer, antelope, chamois, rabbits, hares, horses and less commonly cattle and also human the intermediate hosts for *T. multiceps* ingest the taenia egg<sup>[1,2,5]</sup> (Coenuri are transmitted to humans through the consumption of egg-containing feces-contaminated food or water) The egg hatches in the small

intestine and the coenuri (the larval tapeworm) burrows through the intestinal wall and travels to the brain and spinal cord via the blood stream. The coenurus typically develops in the brain, reaching the infective stage in about 6 to 8 months. When dogs or other canids (foxes, wolves and jackals) ingest infected sheep tissue, usually through the feeding of offal, the protoscoleces attach to the small intestinal wall and the worms begin to form proglottids (one of the segments of the tapeworm containing both the male and female reproductive organs). Proglottids containing eggs detach from the end of the worm and pass out in the feces. When the intermediate hosts ingest food or water contaminated by infected feces, the oncosphere hatches in the small intestine and makes its way into the blood vessels into the intestinal wall. The embryo is carried in the blood stream throughout the body but most frequently develops in the central nervous system. Protoscoleces bud from the inner surface of the cyst wall and attach to the target organ and the cycle repeats<sup>[1,2,4,5]</sup>.

The pattern of clinical disease which develops depends on the location of the cyst which exerts pressure on adjacent brain tissue. Most commonly cysts exert pressure on the cerebral hemi-spheres and this can result in inco-ordination, with the head held to one side and a tendency to circle in that direction, there may be blindness in the opposite eye, nystagmus, hyperexcitability and muscle tremors. A jerky or very ataxic gait may be observed when the cerebellum is involved and where the cyst occupies a superficial position there may be some softening of the bones of the

skull. Affected animals may survive for several weeks following the onset of clinical signs. Unless treated surgically, the animal will die after recumbency<sup>[1,3,6]</sup>.

Generally, since in this disease disorders is found in the Central Nervous System (CNS), major clinical symptoms occurs as behavioural disorders and ataxia. In relative with treatment, should be stated that Chemotherapy treatment has been attended recently which in this investigation aimed to effective of different Anthelmintic agents in treatment of coenurosis so that responsive rate of animals be evaluated against such recommendations and prescription.

The aim of the present study was to evaluate the effect of albendazole, fenbendazole and praziquantel using the intraoperative periods as multivalence therapy against coenurosis. In the present study, it was proposed to reach various aims and for this reason, convenient experimental groups were formed.

## MATERIAL AND METHOD

In this survey a total of twenty five affected sheeps were selected, consist of five animal per each group that one as control group.

### Group1:

Albendazole with dosage 25 mg kg<sup>-1</sup> treated for the duration six days.

### Group2:

Praziquantel with dosage 100 mg kg<sup>-1</sup> treated for the duration seven days.

### Group3:

Fenbendazole with dosage 25 mg kg<sup>-1</sup> treated for the duration eight days.

### Group4:

BY fenbendazole with dosage 0.5 for each affected sheep + praziquantel with dosage 100mg kg<sup>-1</sup> treated six times by interval of 20 days.

### Group5:

**Control group:** All of the animals in control group where as no treatment was given, wasted until tenth day of design execution. Three animals of different treated groups wasted, that one animal belonging to praziquantel treatment group and two animals belonging to fenbendazole treatment group.

## RESULTS AND DISCUSSION

The results of this investigation has been followed in the (Table 1). In addition to, it is observed that in ninety

Table1: Treatment examinations coenurosis in sheep

Wastage number	Recovery time	Treatment period(Days)	No. of animal	Treatment kind
-	12-16	6	5	Albendazole
1	12-17	7	5	praziquantel
2	14-20	8	5	fenbendazole
-	12-17	2	5	fenbendazole + praziquantel
5	-	-	5	Without treatment

Table 2: Classifying results of patients in five groups studied.(extracted from table1)

Total	5	4	3	2	1	Groups
17	-	5	3	4	5	Treated
8	5	-	2	1	-	Wasted
25	5	5	5	5	5	Total

percent of treated animals, had been removed clinical signs and in ten percent remaining, signs removed considerable. The pathoanatomical study of sheeps(control group) revealed coenurosis cysts localized in the hemispheres, in the cerebellum or simultaneously in the hemisphre and the cerebellum. Their size varied from 2-5 cm in diameter and their number was from 1 to 3 at a time. A degree of compressive atrophy of the adjacent nervous tissue and the bones overlying the calvarium was observed. Also other signs such as swelling of brain and yellowish-red lines to across 2-4 mm that is pathways of encosphere migration in brain, has been observed.

The autopsy of the treated sheeps, revealed state of calcification of cyst in all of groups that is observed most commonly in group treated with albendazole and in group treated with composed (fenbendazole+praziquantel).In some treated animals cyst degeneration with cyst fluid concentration, otherwise increase of cyst fluid viscosity as milky- yellowish color were observed.

Therapeutic effects of different antiparasitic drugs in Fig. 1 and duration of treatment and at least time of recovery affected animals with coenurosis has been showed in the Fig. 2.

So could be extracted summary as Table 2 from Table1, that doing Chi-square test shows in level  $\alpha=0/05$ , there is significant difference between control and treated groups.

Therapeutic measures include antiparasitic drugs and surgery. Although surgical treatment of coenurosis is frequently successful, but however use of surgery in animals, specially in small ruminants is limited and restricted to economically and genetically superior and valuable animals and cannot be advisable in field conditions. There was agreement that albendazole, fenbendazole and praziquantel are effective antiparasitic agents, destroying most viable cysts and it may be used as regular treatment for larval stage of tapeworm<sup>[7,8]</sup>.

As demonstrated by experiments in animals, albendazole and praziquantel are effective antiparasitic drugs against cystic larval stage. Initial studies with

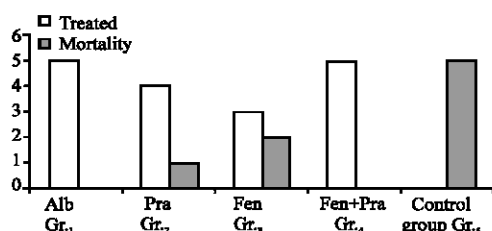


Fig. 1: Description of results of various treatment

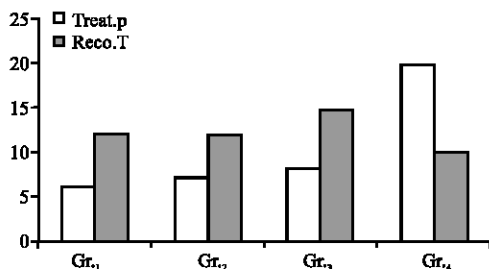


Fig. 2: Treatment duration and at least time recovery in the treatment.

praziquantel noted that low doses had some effect against cysts and doses as high as 50 to 75 mg kg<sup>-1</sup> day<sup>-1</sup> were well tolerated. In 1977 Bankov and in 1982 Verster succeeded for the first time in treating coenuriasis in sheep with praziquantel<sup>[8]</sup>. The formation of cysts in the brain was prevented by chemotherapy with 50 mg kg<sup>-1</sup> b.w. No dose ranging studies were performed with albendazole and fenbendazole in coenurosis. There is limited experience with higher doses of both drugs. There has been concern about the safety of albendazole in sheep and goats. The present study demonstrated the high efficacy of albendazole given at a dose of albendazole has better penetration into cerebrospinal fluid and because of this its effect increase<sup>[9]</sup> however, seems to respond better to a treatment with albendazole than to praziquantel and fenbendazole.

Also Present results indicate the efficacy of the coadministration of fenbendazole plus praziquantel combination against coenurosis has very useful effects. In order to preserve the full potential of praziquantel it is recommended that administration of the drug be used in full dose and in combination with benzimidazole broad-spectrum anthelmintics such as fenbendazole in full dose. In all of treatment group, Between the second and fifth days of antiparasitic therapy, there was usually a diminution of neurological symptoms. Three techniques have been suggested for reducing the development of resistance and more effects: 1) Use a full dose of dewormer whenever treatment is done, 2) Added dosing frequency by increasing stocking rates or use dose-and-move. 3) Treat all new introductions with the best products available and perhaps with a double dose. Thus

chemotherapeutic approach using drugs like albendazole, praziquantel, and fenbendazole may have been tried. Finally, three important problems including drug prescription period, recovery time and therapeutic certainty being that in this study (Table 1) was showed therapeutic effects of albendazole and composed (fenbendazole+praziquantel) was crucial, but therapeutic effects of both recently drugs fenbendazole and praziquantel had not more fitted separately.

Between two successfully method of therapy above, due to short duration of coenurosis treatment period with albendazole is preferred. So can be concluded that using Anthelmintic agents Adult Dose for treatment of coenurosis, this can result successfully. Also according to this investigation increasing of treatment period, can arrive successful results and nowadays the medicament is administered daily without interruption.

## REFERENCE

1. Soulsby, E.J.L., 1982. Helminths. Arthropods and Protozoa of Domesticated Animals. 7th Edn, Baillier and Tindall UK.
2. Smyth, J.D., 1994. Introduction to animal Parasitology. 3rd Edn., Cambridge University press.
3. Edwards, G.T. and I.V. Herbert, 1982. Observations on the course of *Taenia multiceps* infections in sheep: Clinical signs and post-mortem findings. Br. Vet. J., 138: 489-500.
4. Herbert, I.V., G.T. Edwards and J.M. Willis, 1984. Some host factors which influence the epidemiology of *Taenia multiceps* infections in sheep. Ann. Trop. Med. Parasitol., 78: 243-248.
5. Skerritt, G.C., 1991. Coenurosis. In: diseases of sheep. B. 2nd Edn., Martin and I.D. Aitken (Eds.). Blackwell Scientific Publications, Oxford.
6. Skerritt, G.C. and M.F. Stallbaumer, 1984. Diagnosis and treatment of coenuriasis (gid) in sheep. Vet. Rec., 115: 399-403.
7. Aminzhanov, M., M. Musinov and V.A. Baratov, 1988. Chemoprophylaxis of coenurus cerebralis intestation in sheep using fenbendazole and praziquantel. Vetrinarya, 10: 46-47.
8. Eslami, A. and T.T. Bazargani, 1986. The efficacy of praziquantel against coenurus in naturally sheep. Vet. Med. Rev., 1: 97-99.
9. Adams, 1999. Veterinary Pharmacology and Therapeutic. Iowa State University Press Ames.