

## ***Cytauxzoon felis*-like in the Mountain Lion (*Puma concolor*): A Case Report**

Juliano Raquel Soares, Souza Alda Izabel, Netto, Nilton Tércio,  
Scheide Renata and Scofield Alessandra  
Doctoral Student in Animal Sciences, School of Veterinary Medicine, UFG,  
Goiânia-GO. P.O. Box 131, Goiânia, GO, Brazil

**Abstract:** The Laboratory of Clinical Pathology of UNIDERP performs routine examinations, when requested, of animals from the Center for Wild Animal Rehabilitation (CRAS) of Campo Grande, MS, Brazil. During one of these routine procedures, erythrocytic parasites identified as *Cytauxzoon felis*-like were detected in blood smears obtained from a mountain lion (*Puma concolor*) with parasitemia being 20%. No clinical alterations or infestation with ticks were observed in this animal, and hematological and serum biochemical exams showed only slight alterations. Blood and serum were collected three months later from six mountain lions housed at the CRAS and another animal tested positive for parasites in blood smears with parasitemia of 10%, without showing any clinical, hematological or blood biochemical changes characteristic of cytauxzoonosis. This animal presented parasitemia and laboratory results slightly lower than those observed in the previous animal. Two domestic cats (*Felis catus*) were inoculated, but the animals did not show any clinical signs of cytauxzoonosis. The identification of this blood-borne parasite in wild felines maintained in captivity in the absence of pathogenic manifestations suggests that the mountain lion acts as a natural host for *C. felis*-like, or that this strain is less pathogenic. Since this is the first report of cytauxzoonosis in *Puma concolor* in Brazil, further epidemiological studies are necessary to determine the true impact of infection of wild felines with this protozoan.

**Key words:** *Cytauxzoon felis*-like, mountain lion, *Puma concolor*, cats, blood parasitosis

### **Introduction**

The distribution of diseases transmitted by ticks in North America has suffered modifications as a result of the urbanization of rural areas, greater human mobility in forest areas, and movement of wild and domestic animals, favoring contact between species that act as hosts susceptible to these diseases. A better understanding of these diseases is necessary not only to determine their impact on wild and domestic animal populations, but also to estimate their true risk to human health. Among these illnesses is cytauxzoonosis, which is asymptomatic in the bobcat (*Lynx rufus*) but shows a fatal evolution when transmitted to domestic cats (Kocan and Kocan, 1991).

*Cytauxzoon felis* is a protozoon of the class Piroplasmidia, experimentally transmitted by ixodid ticks *Dermacentor variabilis* (Blouin *et al.*, 1984), which parasitizes erythrocytes of wild and domestic cats, with schizogony occurring in cells of the phagocytic mononuclear system of the vertebrate host (Hoskins and Hoskins, 1991).

Kocan *et al.* (1992), studying the formation of merozoites of *C. felis* in cats experimentally infested by ticks, observed the occurrence of schizogony in macrophages of the pulmonary and hepatic endothelium. According to these authors, the formation of merozoites occurs rapidly by fission, with the formation of small rosette-like masses, with an elongated and multicellular sporont being visible at the margin of the cell. Merozoites penetrate erythrocytes by endocytosis, apparently not causing any injury to these cells.

Cytauxzoonosis has mainly been described in a restricted region in the South and Southeast of the United States, with the natural hosts being the bobcat (*Lynx rufus*) and the Florida panther (*Felis concolor coryi*), which do not show signs of this parasitic disease (Butt *et al.*, 1991; Hoskins and Hoskins, 1991).

Natural infections were related in guepardo (Zinkl *et al.*, 1981), Florida panther (Butt *et al.*, 1991; Rotstein *et al.*, 1999); white tiger (Garner *et al.*, 1996), Bengal tiger (Jakob and Wesemeier, 1996) and Texas puma (Rotstein *et al.*, 1999).

*C. felis*-like was observed in *Panthera leo* from a zoo in the State of Rio de Janeiro (Brazil), there were partial or total occlusion of blood vessels (Peixoto *et al.*, 1999). Soares *et al.* (1999a) found intraerythrocytic corpuscle in *Panthera onca* and *Leopardus tigrinus* (Soares *et al.*, 1999b). Later, clinical signs, pathology and parasitological aspects were studied in cats (Scofield *et al.*, 1999; Soares, 2002; Scofield *et al.* 2002).

The most frequent clinical signs of cytauxzoonosis are lethargy, anorexia, depression, dehydration, fever, jaundice and increased capillary refill time. Laboratory findings were normocytic normochromic anemia, leukopenia, thrombocytopenia, high levels of bilirubin, glucose and alanine aminotransferase activity, low serum concentrations of albumin and potassium, and bilirubinuria (Hoover *et al.*, 1994). The mortality rate is high in domestic cats and Bengal tigers (*Panthera tigris*), with death occurring within 3 to 12 days after the onset of clinical signs (Kocan and Kocan, 1991; Butt *et al.*, 1991; Jakob and Wesemeier, 1996 and Meier and Moore, 2000). However, Meinkoth *et al.* (2000) reported 18 cases of animals which survived natural infection with *C. felis*. All animals tested positive

for the parasite in blood smears, with parasitemia persisting for a variable period of 3 to 154 days, and the survival rate was not related to treatment, with only one animal receiving specific treatment. The authors suggested the existence of a less pathogenic parasite strain.

The direct diagnosis of the parasite can be made by light microscopy analysis of stained blood smears, in histological sections of liver, lungs, spleen and lymph nodes of naturally infected animals or animals inoculated for parasite isolation, and by the polymerase chain reaction (PCR) (Hoskins and Hoskins, 1991; Kocan *et al.*, 1992; Allsopp *et al.*, 1994; Meinkoth *et al.*, 2000; Soares, 2001).

Meier and Moore (2000) identified the parasite in macrophages after post mortem cytological analysis of tissues such as liver, lung and spleen obtained from a naturally infected cat. The indirect diagnosis can be made by the detection of anti-*Cytauxzoon* antibodies using microfluorometry (Cowell *et al.*, 1988).

Motzel and Wagner (1990) studied the treatment of experimentally inoculated domestic cats, surprisingly, however, two inoculated untreated animals survived. The blood of these animals was inoculated into two cats, with no manifestation of the disease.

The aim of this work was to report that this protozoan is present in wild felines in Brazil and your virulence and epidemiology must be investigated.

## Material and Methods

The Laboratory of Clinical Pathology of UNIDERP performs routine examinations, when requested, of animals from the Center for Wild Animal Rehabilitation (CRAS), Campo Grande, MS, Brazil.

**First collection:** Whole blood and serum obtained from a mountain lion (*Puma concolor*) captured in the municipality of Ponta Porã, MS, and sheltered at the CRAS was sent to the Laboratory of Clinical Pathology.

**Second collection:** About one month later, whole blood samples were collected from six mountain lions of the CRAS for new examination.

**Experimental inoculation:** During collection, all animals were submitted to dissociative anesthesia with xylazine and ketamine before venipuncture. A 100-ml blood sample (in 25 ml sodium citrate) was collected from animals with a positive diagnosis of *C. felis* for experimental inoculation into two female cats. The blood was maintained under refrigeration for 3 hours and 20 ml were injected subcutaneously into the cats.

Blood smears were obtained monthly following Lubinsky (1960) method, and the inoculated cats were submitted to hematological and biochemical examination.

## Results

The results of the first collection did not show any alterations in normal values, but determination of hematozoa in blood smears revealed intraerythrocytic ovoid parasites (Fig. 1), with parasitemia being 20%.

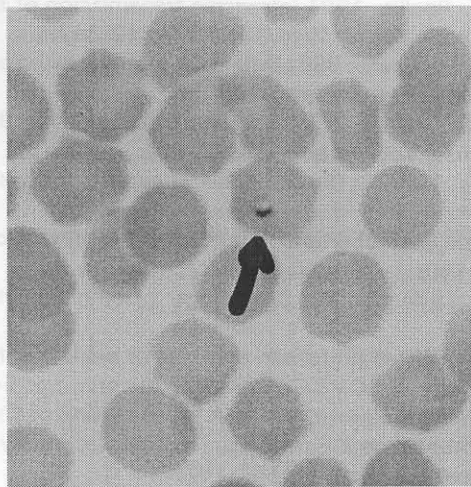


Fig. 1: Intraerythrocytic ovoid parasites (*C. felis*-like) in blood smear of *Puma concolor*

During the second collection, the presence of activated monocytes of *C. felis* was observed in another animal, a young female, upon blood cell cytoscopy, with a parasitemia of 10%. The tests carried out during the second

collection showed discrete alterations to male parasited previously (global leukopenia due to absolute neutropenia and lymphocytosis) and to female (increased fibrinogen, global leukopenia due to neutropenia, urea levels above normal). The animals were clinically healthy. No alterations were identified in inoculated cats.

## Discussion

The intraerythrocytic ovoid parasites found in animals were similar to the morphological type described by Scofield *et al.* (2002), animals had none characteristic signal of cytauxzoonosis such as anemia, hypoproteinemia and an increased icteric index (Hoover *et al.*, 1994).

The positive parasitological diagnosis and the absence of clinical signs compatible with the disease suggest that the mountain lion (*Puma concolor*) may represent a natural reservoir of this parasite, as observed for the bobcat (*Lynx rufus*) and Florida panther (*Felis concolor coryi*) which do not show any signs of pathogenesis of this disease (Hoskins and Hoskins, 1991). This hypothesis is highly plausible since the Florida panther is a phylogenetically close subspecies of *Puma concolor* (Oliveira, 1994).

The second hypothesis would be the existence of a less pathogenic *C. felis* strain which is unable to cause lesions in susceptible feline species, as already reported by Meinkoth *et al.* (2000). This is an important hypothesis because the experimentally inoculated cats did not show the characteristic fatal syndrome of cytauxzoonosis (Kocan and Kocan, 1990; Butt *et al.*, 1991; Jakob and Wesemeier, 1996; Meier and Moore, 2000).

Although lions that died with cytauxzoonosis were parasited with *Amblyomma cajennense* (Peixoto *et al.*, 1999) and other animals in the same place were naturally infected by *C. felis*-like (Soares *et al.*, 1999 ab), the vector of this parasite is unknown. In this case report the absence of any type of tick in the mountain lions supports the suspicion that another type of vector might be involved in the epidemiology of this disease, as suggested by Soares (2001), indicating the need for further investigations to determine the importance of these isolated findings and the extent to which the health of animals susceptible to this blood parasitosis is compromised.

In conclusion, this case report that *C. felis*-like was identified in blood smear from two *Puma concolor* specimens captured in the State of Mato Grosso do Sul and housed at the CRAS, Campo Grande, MS. Experimental inoculation in two domestic cats did not reveal any pathogenic action of this blood-borne parasite.

## Acknowledgment

We thank Dr. Cléber de Oliveira Soares, Embrapa Beef Cattle, Campo Grande, MS, for his invaluable contribution to the confirmation of the parasitological diagnosis.

## References

- Allsopp, M. T. E. P., T. Cavalier-Smith, D. T. Dewaal, B. A. Allsopp, 1994. Phylogeny and evolution of the piroplasms. *Parasitology*, 108: 147-152.
- Blouin, E. F., A. A. Kocan, B. L. Glenn, K. M. Kocan, 1984. Transmission of *Cytauxzoon felis* Kier, 1979 from bobcats, *Felis rufus* (Schreber), to domestic cats by *Dermacentor variabilis* (Say). *J. Wild. Dis.*, 20: 241-242.
- Butt, M. T., D. Bowman, M. C. Barr, M. E. Roelke, 1991. Iatrogenic transmission of *Cytauxzoon felis* from a Florida panther (*Felis concolor coryi*) to a domestic cat. *J. Wild. Dis.*, 27: 342-347.
- Cowell, R. L., J. C. Fox, R. J. Panciera, R. D. Tyler, 1988. Detection of anticytauxzoon antibodies in cats infected with *Cytauxzoon* organisms from bobcats. *Vet. Parasit.*, 28:43-52.
- Garner, M. M., N. P. Lung, S. Citino, E. C. Greiner, J. W. Harvey, B. L. Homer, 1996. Fatal cytauxzoonosis in a captive-reared white tiger (*Panthera tigris*). *Vet. Pathol.*, 33: 82-86.
- Hoover, J. P., D. B. Walker, J. D. Hedges, 1994. Cytauxzoonosis in cats: eight cases (1985-1992). *J.A.V.M.A.*, 205: 455-460.
- Hoskins, J. D., J. D. Hoskins, 1991. Canine haemobartonellosis, canine hepatozoonosis and feline cytauxzoonosis. *J. South African Vet. Assoc.*, 63:129-140.
- Jakob, W., H. H. Wesemeier, 1996. A fatal infection in a Bengal tiger resembling cytauxzoonosis in domestic cats. *J. Comp. Pathol.*, 114:439-444.
- Kocan, A. A., K. M. Kocan, 1991. Tick-transmitted protozoan diseases of wildlife in North America In: Symposium: Vectors of Wildlife Diseases, Proc. 22 Annual SOVE Conference, Arizona, pp: 54.
- Kocan, A. A., K. M. Kocan, E. F. Blouin, S. W. Mukolwe, 1992. A redescription of *Cytauxzoon felis* in the domestic cat, 1992. In: Williams, J.C.; Kocan, K.M.; Gibbs E.P.J. (Ed.), *Tropical Veterinary Medicine: Current issues and perspectives* Annals of New York Academy of Sci., pp:161-167.
- Lubinsky, G., 1960. Note of the use of McLrvine's buffer solutions in staining blood Protozoa. *Can. J. Zool.*, 38: 437-438.
- Meier, H. T., L. E. Moore, 2000. Feline cytauxzoonosis: a case report and literature review. *J. Am. An. Hosp. Assoc.*, 36: 493-496.

- Meinkoth, J., A. A. Kocan, L. Whitworth, G. Murphy, J. C. Fox, J. P. Woods, 2000. Cats surviving natural infection with *Cytauxzoon felis*: 18 cases. *J. Vet. Int. Med.*, 14:521-525.
- Motzel, S. L., J. E. Wagner, 1990. Treatment of experimentally induced cytauxzoonosis in cats with parvaquone and buparvaquone. *Vet. Parasit.*, 35: 131-138.
- Oliveira, T. G., 1994. Neotropical Cats, Ecology and Conservation, UFMA Ed., São Luís.
- Peixoto, P. V., C. O. Soares, C. D. Santiago, S. S. Barros, C. L. S. Barros, B. M. Cunha, 1999. Citauzoonose fatal em leões (*Panthera leo*) no Brasil. In: SONVET (Ed), Annals 26th Brazilian Medicine Veterinary Congress, Campo Grande, 1999.
- Rotstein, D. S., S. K. Taylor, J. W. Harvey, J. Bean, 1999. Hematologic effects of cytauxzoonosis in Florida panthers and Texas cougars in Florida, *J. Wild. Dis.*, 35: 613-617.
- Scofield, A., C. O. Soares, G. B. Manera, A. H. Fonseca, P. V. Peixoto, A. A. P. Gonzalez, 1999. Citauzoonose felina experimental em gato doméstico (*Felis catus*). In: Anals of 11th Sem. Bras. Parasitol., Salvador, pp: 236.
- Scofield, A., 2002. Caracterizações morfológica, morfométrica e ultraestrutural de *Cytauxzoon felis simile*. Dissertação de Mestrado, Curso de Pós-graduação em Ciências Veterinárias – Parasitologia Veterinária: UFRRJ. pp: 76.
- Scofield, A., C. J. F. Oliveira, R. C. Madureira, C. O. Soares, A. H. Fonseca, 2002. Tipos morfológicos intraeritrocíticos de *Cytauxzoon felis simile* em gatos domésticos no Brasil, In: SSMV-SOMVERGS (Ed), Proc. 29th Conbravet, Gramado, CD-Rom.
- Soares, C. O., P. V. Peixoto, A. Scofield, A. H. Fonseca, C. L. Massard, C. D. Santiago, 1999a. *Cytauxzoon* sp. Neitz & Thomas, 1948 (Apicomplexa: Theileriidae) em *Panthera onca*. In: Anals of 11th Sem. Bras. Parasitol., Salvador, pp: 235.
- Soares, C. O., P. V. Peixoto, A. Scofield, A. H. Fonseca, C. D. Santiago, 1999b. *Cytauxzoon* sp. Neitz & Thomas, 1948 (Apicomplexa: Theileriidae) em *Felis tigrina* (*Leopardus tigrinus*) no Brasil. In SONVET (Ed), Annals 26th Brazilian Medicine Veterinary Congress, Campo Grande, 1999.
- Soares, C. O., 2001. Cytauxzoonose felina é diagnosticada e isolada pela primeira vez na América Latina. *Clín. Vet.*, 32:56-58.
- Soares, C. O., 2002. Estudos Biológicos e Clínico-patológico da Citauzoonose Causada por *Cytauxzoon felis simile* (Apicomplexa: Theileriidae), no Brasil. Tese de Doutorado, Curso de Pós-graduação em Ciências Veterinárias – Parasitologia Veterinária: UFRRJ. pp:150.
- Zinkl, J. G., S. E. McDonald, A. B. Kier, S. J. Cippa and P. J. Small, 1981. *Cytauxzoon*-like organisms in erythrocytes of two cheetahs. *J.A.V.M.A.*, 179:1261-1262.