

Role of Stem Cells in Treatment of *Acanthamoebic* Corneal Ulcer

^{1,2}Khadiga Ahmed Ismail, ^{1,3}Yousry Abdel-Hameid Hawash, ⁴Ahmed Mahmoud Khalifa and ⁴Osama Mahmoud Khalifa

¹Department of Laboratory Medicine, Faculty of Applied Medical Sciences,
Taif University, Taif, Saudi Arabia

²Department of Parasitology, Faculty of Medicine, Ain-Shams University, Cairo, Egypt

³Department of Parasitology, National Liver Institute, Menoufia University, Shebin El- Koom,
Menoufia, Egypt

⁴Faculty of Medicine, Ain-Shams University, Cairo, Egypt

Abstract: Regeneration of lost human tissue is well known, the research on regenerative medicine has gained scientific advancements. The growing understanding of biological concepts in the regeneration of ocular tissues as well as experiments on stem cells result in shift in the treatment of corneal diseases. Stem cells have been successfully isolated from variety of human tissues including mesenchymal tissues. Initial evidence from several studies has documented the likely breakthrough that stem cells offer for various life-threatening diseases that have so, far defeated modern medical care. So, this research aimed to study the role of stem cells in treatment of *Acanthamoebic* corneal ulcer. Test experiment included *Acanthamoeba*-infected female albino rats started local treatment by chlorhexidine 0.02% after 2 weeks post infection and Mesenchymal Stem Cells (MSCs) injected. Female rats were subdivided into 4 groups. Group (Gp) 1:15 rat infected and injected with MSCs intravenously at 2 weeks post-infection. Gp 2:15 rat infected and intravenously injected with MSCs at 3 weeks post-infection. Gp 3:15 rat infected and injected locally subconjunctival at 2 weeks post-infection. Gp 4:15 rat infected and locally subconjunctival injected at 3 weeks post-infection with MSCs. Control groups were composed of age and weight-matched control female rats, subdivided into: Gp 5-8. Gp 5 was composed of 10 *Acanthamoeba*-infected and non-injected (non-treated negative control) rats. Each 10 of them was sacrificed on dates corresponding to sacrifice dates of each test groups (at one week post treatment). Gp 6 is composed of 10 rats infected and intravenously injected by PBS (vehicle). Each were sacrificed on dates corresponding to sacrifice dates of Gp 1 and 2 (at one week post treatment). Gp 7:10 rats infected and locally subconjunctival injected by PBS (vehicle). Each 10 was sacrificed on dates corresponding to sacrifice dates of Gp 3 and 4 (at one week post treatment). Gp 8:10 *Acanthamoeba*-infected and locally treated by chlorhexidine 0.02% positive control rats which are infected and not injected with MSCs. Each 10 of them was sacrificed on dates similar to sacrifice dates of each test group (at one week post treatment). Rates were sacrificed on the planned dates then corneal specimens and blood samples were collected. There were significant decrease in the level of Vascular Endothelial Growth Factor (VEGF) in group 1, 3 and highly significant decrease in the level of Nitric Oxide (NO) in group 1-3 in comparison to positive control group 8. There were 20% engraftments with MSC in group 1. Treatment of *Acanthamoeba* corneal ulcer with chlorhexidine 0.02% and MSCs accelerated regeneration of the corneal epithelium and restored the antioxidant protective mechanism.

Key words: Stem cells, *Acanthamoeba* spp., corneal ulcer, chlorhexidine, blood samples, antioxidant protective

INTRODUCTION

Corneal injury caused by chemical or thermal burns, mechanical injury, invading microorganism as *Acanthamoeba* and immune or hereditary disorders results in corneal inflammation, ulceration, neovascularization, conjunctivalization and stromal

scarring, all of which may lead to blindness. Current treatment strategies include anti-inflammatory drug administration, stem cell transplantation and corneal transplantation. However, these treatments have certain clinical limitations. Anti-inflammatory drugs are not sufficient to suppress angiogenesis, conjunctivalization and corneal scarring (Reinhard *et al.*, 2004). Corneal

transplantation remains the main and effective method for visual rehabilitation once a disease has affected corneal clarity (Tan *et al.*, 2012). Even though corneal transplantation is the most successful solid organ transplantation, immune rejection is still the major cause of graft failure. Over the last decade, Mesenchymal Stem Cells (MSCs) treatment has been proposed and used as a possible treatment strategy for cardiovascular diseases, renal wound repair, diabetes, systemic lupus erythematosus and solid organ transplantation (Cashman *et al.*, 2013). MSCs are a promising stem cell population because of their self-renewal, pluripotential capability, low immunogenicity properties and notable immunomodulatory and anti-inflammatory activities. Methods for the isolation and proliferation of MSCs are also simple. MSCs are mainly derived from bone marrow tissue. MSCs can also be isolated from niche of other tissues, including corneal limbal stroma (Stewart and Stewart, 2011).

Acanthamoeba is an opportunistic amphizoic protozoan which is found in the environmental sources. *Acanthamoeba* can be found in quite different media including sea water, treated water, swimming pool, aquarium, bottled water, soil, air dust, sewage water, contact lenses washing solution, food stuff, air conditioners and dialysis machines (Marciano-Cabral and Cabral, 2003). This protozoan can enter the human body in the form of cyst or trophozoite via polluted water, soil or air (Edrisian *et al.*, 2008). Several studies have reported that *Acanthamoeba* can attack to Central Nerve System (CNS) leading to granulomatous encephalitis. *Acanthamoeba* also target other organs such as eye which end up with amoebic keratitis as well as skin lesions in the patients with immunodeficiency and in healthy individuals (Steinberg *et al.*, 2002). Lack of awareness about proper washing, disinfecting contact lenses and use of polluted contact lens solution with *Acanthamoeba* causes *Acanthamoeba* keratitis. Therefore, the knowledge of contact lenses wearer about maintenance of contact lenses is very critical. The presence of other microorganisms accompanied with *Acanthamoeba* in contact lenses has a considerable role in the increase of number of trophozoite adhesion to lenses and thus, the increase prevalence of *Acanthamoeba* Keratitis (AK) (Winiacka-Krusnell and Linder, 2001).

Early diagnosis and treatment of AK are essential for improving the visual outcome of patients (Cardine *et al.*, 2002). The gold standard of diagnosis is cultivation of *Acanthamoeba* from corneal scrapings. The recommended technique for cultivation is the use of non-nutrient agar covered with a bacterial lawn (Schuster, 2002). However, cultivation is a slow process and needs a long incubation

time (Schuster and Visvesvara, 2004a). Conventional Polymerase Chain Reaction (PCR) has been found to be rapid, sensitive and can be done with a small amount of the specimen (Safar, 2010).

Treatment of AK has been fairly successful using a variety of drugs. Brolene is found to be effective but may be accompanied by drug toxicity and development of resistance (Schuster and Visvesvara, 2004b). Polyhexamethylene biguanide and chlorhexidine have been proved to be effective with treatment success of 78 and 86%, respectively (Lim *et al.*, 2008). However, side effects in the form of cataract, iris atrophy and peripheral ulcerative keratitis have been attributed to the use of those drugs (Dart *et al.*, 2009). *Acanthamoeba* strains have been identified and isolated from Wadi Hanifah fresh water in Saudi Arabia (Al-Herrawy and Al-Rasheid, 1998). This research aimed to study the MSCs role in the treatment of corneal ulcer caused by *Acanthamoeba*.

MATERIALS AND METHODES

Isolation of *Acanthamoebae* from corneal scrapings:

Corneal scrapings were obtained from patients attending ophthalmology out patients department who were clinically suspected to have *Acanthamoeba* keratitis.

Culture of the obtained samples: The obtained corneal samples were inoculated onto non-nutrient agar plates covered with a lawn of *Escherichia coli* (Schuster, 2002).

Animal groups: A total of 100 healthy albino females rats weighing approximately 200-250 g. All animals were fed standard diet and drinking water. All rats were housed 5/cage with a temperature and relative humidity maintained within the target range of 18-22°C and 40-70%, respectively and a 12-h light/dark cycle. Intra-stromal corneal injection of 1 µL of *Acanthamoeba* suspension containing 1×10^6 parasites/mL. Injection were done under general anaesthesia in one eye of each rat.

The animals are divided into groups: The experiment included 4 groups of *Acanthamoeba*-infected (confirmed by slit lamp examination and start local treatment by chlorhexidine 0.02% after 2 weeks post infection) and MSCs injected female rats which were subdivided into 4 groups. Group (Gp) 1:15 rat infected and injected with MSCs intravenously at 2 weeks post-infection. Gp 2:15 rat infected and intravenously injected with MSCs at 3 weeks post-infection. Gp 3:15 rat infected and injected locally subconjunctival at 2 weeks post-infection. Gp 4:15 rat infected and locally subconjunctival injected at 3 weeks

post-infection with MSCs. Control groups were composed of age and weight-matched control female rats, subdivided into: Gp 5-8. Gp 5 was composed of 10 *Acanthamoeba*-infected and non-injected (non-treated) rats. Each 10 of them was sacrificed on dates corresponding to sacrifice dates of each test groups (at one week post treatment). Gp 6 is composed of 10 rats infected and intravenously injected by PBS (vehicle). Each were sacrificed on dates corresponding to sacrifice dates of Gp 1 and 2 (at one week post treatment). Gp 7: 10 rats infected and locally injected by PBS (vehicle). Each 10 was sacrificed on dates corresponding to sacrifice dates of Gp 3 and 4 (at one week post treatment). Gp 8: 10 *Acanthamoeba*-infected and locally treated by chlorhexidine 0.02% positive control rats which are infected and not injected with MSCs. Each 10 of them was sacrificed on dates similar to sacrifice dates of each test group (at one week post treatment). Rats were sacrificed on the planned dates then corneal and blood specimens were collected.

Preparation of the stem cells: Bone marrow were obtained under aseptic conditions. Tibiae and femurs of 6-week-old donor male rat were thoroughly washed by sterile Phosphate-Buffered Saline (PBS). Bone marrow cavities were flushed by Dulbecco's Modified Eagle's Medium (DMEM, Lonza, Switzerland) supplemented with 15% fetal bovine serum (Lonza, Switzerland) into a sterile petri-dish. Nucleated cells were isolated and resuspended in DMEM culture medium supplemented with 1% penicillin-streptomycin (Lonza, Switzerland) and sterile sodium bicarbonate 7.5% aqueous solution (Lonza, Switzerland). Cells were incubated at 37°C in 5% humidified CO₂ and were examined daily by inverted microscope. Trypsinization and cell viability testing were done by 9-10 days when cell count reaches a final concentration of 5-8×10⁶/mL. A single dose of 500,000 male-derived, non-fractionated MSCs suspended in PBS were injected into each *Acanthamoeba*-infected female rat by a sterile insulin needle.

Corneas were scraped and subjected to the following Conventional PCR assay: Genomic DNA were extracted from the rat corneal tissue homogenate in each group using Wizard Genomic DNA purification kit (Promega, Madison, Wisconsin). The presence or absence of the sex determination region on male Y chromosome (sry) gene in recipient female rat was assessed by PCR. PCR products will be separated using 2% agarose gel electrophoresis and stained with ethidium bromide. Positive (rat male genomic DNA) and negative (female genomic DNA) controls were included in each assay.

Enzyme-Linked Immunosorbent Assay (ELISA): VEGF protein levels in the corneas were determined using a rat VEGF ELISA Kit (rVEGF-ELISA) Cat. No. EK0540. The corneas were cut into small pieces and the tissue was homogenized with a mortar. The samples were lysed in 500 µL of extraction buffer and centrifuged at 10,000 rpm for 10 min. The supernatants were used for ELISA. Measurements were conducted according to the instructions of the kit in summary samples and standards were added and incubated the strips at 37°C for 90 min. Then add biotinylated antibodies and incubate the strips at 37°C for 60 min. After that wash strips 3 times with 0.01 MTBS. Then add ABC working solution and incubate the strips at 37°C for 30 min. Wash strips 5 times with 0.01 MTBS. After that add TMB color developing agent and incubate the strips at 37°C in dark for 25-30 min. Finally, add TMB stop solution and read. VEGF concentrations were expressed as pg/mL.

Determination of serum NO levels: Serum nitrate concentration as a stable end-product of nitric oxide was measured by an endpoint one-step enzymatic assay using nitrate reductase. The concomitant reduction of nitrate to nitrite by NADPH was monitored by the oxidation of the coenzyme and the decrease in absorbance at 340 nm. The concentrations measured in mol/L. All blood samples for NO level estimation were withdrawn after overnight fasting (12 h) to omit nitrates from external sources.

Data interpretation: The statistical analysis was done using Statistical Package for Social Science (SPSS for Windows; SPSS Inc, Chicago, Illinois). Data were presented as mean±Standard Error (SE). The means were analyzed by one-way ANOVA followed by Bonferonni post hoc test. The difference were considered significant when the p<0.05.

RESULTS AND DISCUSSION

Acanthamoeba was first recognized as an ocular pathogen in 1973 and was the cause of an epidemic in the 1980's due to contaminated contact lenses (O'day and Head, 2000) (Fig. 1-3).

A variety of drugs have been used for treatment of AK including chlorhexidine, polyhexamethylene biguanide, propamide isethionate, dibromopropamide isethionate, neomycin, paromomycin, polymyxin B, clotrimazole, ketoconazole, miconazole and itraconazole (Schuster and Visvesvara, 2004b). Miltefosine, a hexadecyl phosphocholine has also been shown to have amoebicidal potential (Walochnik *et al.*, 2002).

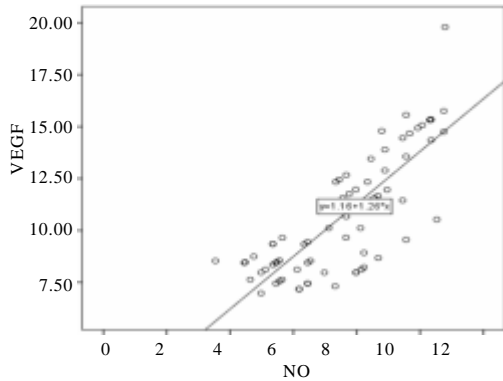


Fig. 1: Correlation of VEGF and NO level in study groups

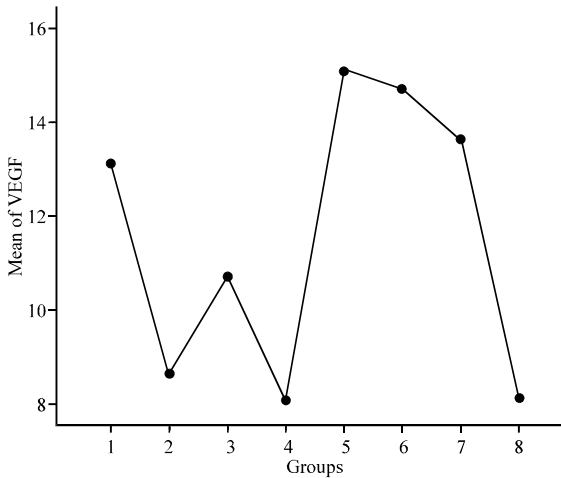


Fig. 2: Mean levels of VEGF in study groups

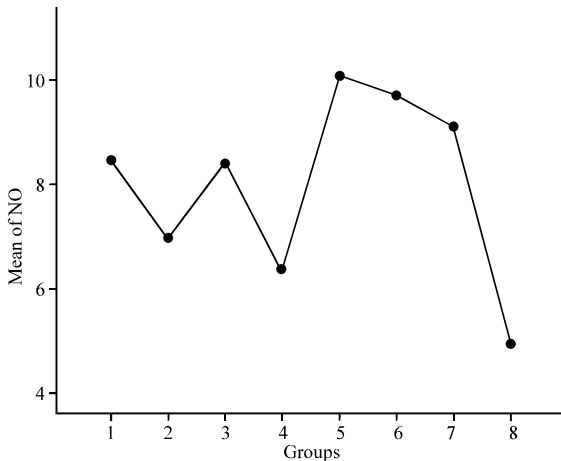


Fig. 3: Mean levels of NO in study groups

Treatment failures occur and may be due to inherent or acquired resistance perhaps attributed to strain and species susceptibility differences or to advanced corneal disease (O’day and Head, 2000).

Table 1: Compare VEGF level in group 1 to other groups

Groups	Test statistic ±SE	Sig.	95% Confidence interval	
			Lower bound	Upper bound
1 vs. 2	4.491±0.599	0.000 ^a	2.6147	6.368
1 vs. 3	2.398±0.641	0.009 ^b	0.3914	4.406
1 vs. 4	5.040±0.611	0.000 ^c	3.1263	6.954
1 vs. 5	1.973±0.796	0.224 ^d	4.468	0.522
1 vs. 6	1.590±0.748	0.410 ^e	3.935	0.753
1 vs. 7	0.500±0.748	0.998 ^f	2.845	1.843
1 vs. 8	4.979±0.660	0.000 ^g	2.9117	7.046

^aHighly significant decrease in VEGF level in group 1 in comparison to group 2 (p<0.001); ^bSignificant decrease in VEGF level in group 1 in comparison to group 3 (p<0.05); ^cHighly significant decrease in VEGF level in group 1 in comparison to group 4 (p<0.001); ^dNon significant decrease in VEGF level in group 1 in comparison to group 5 (p>0.05); ^eNon significant decrease in VEGF level in group 1 in comparison to group 6 (p>0.05)

Table 2: Compare VEGF level in group 2 to other groups

Groups	Test statistic ±SE	Sig.	95% Confidence interval	
			Lower bound	Upper bound
2 vs. 3	2.092±0.629	0.030 ^a	4.064	0.120
2 vs. 4	0.548±0.599	0.983 ^b	1.328	2.425
2 vs. 5	6.464±0.787	0.000 ^c	8.932	3.997
2 vs. 6	6.082±0.738	0.000 ^d	8.396	3.768
2 vs. 7	4.992±0.738	0.000 ^e	7.306	2.678
2 vs. 8	0.487±0.649	0.995 ^f	1.545	2.520

^aSignificant decrease in VEGF level in group 2 in comparison to group 3 (p<0.05); ^bNon significant decrease in VEGF level in group 2 in comparison to group 4 (p>0.05); ^cHighly significant decrease in VEGF level in group 2 in comparison to group 5 (p<0.001); ^dHighly significant decrease in VEGF level in group 2 in comparison to group 6 (p<0.001); ^eHighly significant decrease in VEGF level in group 2 in comparison to group 7 (p<0.001); ^fNon significant decrease in VEGF level in group 1 in comparison to group 8 (p>0.05)

MSCs are a promising stem cell population because of their self-renewal, pluripotential capability, low immunogenicity properties and notable immunomodulatory and anti-inflammatory activities (Stewart and Stewart, 2011).

In this research, treatment of *Acanthamoeba* corneal ulcer by chlorhexidine 0.02% and MSCs which were injected through different ways intravenous and subconjunctival and in different time post infection. The stem cells migrate into the damaged corneal surface by *Acanthamoeba* infection and support corneal healing as there were decrease in the level of inflammatory mediators as VEGF and NO. Our results showed that the treatment of *Acanthamoeba* corneal ulcers with combined chlorhexidine 0.02% and MSCs restored the regenerated corneal epithelium as showed in Table 1-4. This was accompanied by highly reduced neovascularization this in agreement of the study of Ma *et al.* (2006) they concluded that the treatment effect of MSCs was a result of the inhibition of inflammation and angiogenesis rather than epithelial differentiation.

Table 3: Compare VEGF level in group 3 to other groups

Groups	Test statistic ±SE	Sig.	95% Confidence interval	
			Lower bound	Upper bound
3 vs. 4	2.641±0.641	0.003 ^a	0.634	4.649
3 vs. 5	4.372±0.819	0.000 ^b	6.939	1.804
3 vs. 6	3.989±0.773	0.000 ^c	6.410	1.568
3 vs. 7	2.899±0.773	0.009 ^d	5.320	0.478
3 vs. 8	2.580±0.687	0.009 ^e	0.426	4.734

^aSignificant decrease in VEGF level in group 3 in comparison to group 4 (p<0.05); ^bHighly significant decrease in VEGF level in group 3 in comparison to group 5 (p<0.001); ^cHighly significant decrease in VEGF level in group 3 in comparison to group 6 (p<0.001); ^dSignificant decrease in VEGF level in group 3 in comparison to group 7 (p<0.05); ^eSignificant decrease in VEGF level in group 3 in comparison to group 8 (p<0.05)

Table 4: Compare VEGF level in group 4 to other groups

Groups	Test statistic ±SE	Sig.	95% Confidence interval	
			Lower bound	Upper bound
4 vs. 5	7.013±0.796	0.000 ^a	9.509	4.517
4 vs. 6	6.631±0.748	0.000 ^b	8.975	4.287
4 vs. 7	5.541±0.748	0.000 ^c	7.885	3.197
4 vs. 8	0.061±0.660	1.000 ^d	2.128	2.006

^aHighly significant decrease in VEGF level in group 4 in comparison to group 5 (p<0.001); ^bHighly significant decrease in VEGF level in group 4 in comparison to group 6 (p<0.001); ^cHighly significant decrease in VEGF level in group 4 in comparison to group 7 (p<0.001); ^dNon significant decrease in VEGF level in group 4 in comparison to group 8 (p>0.05)

The protection of the cornea against toxic environmental influences after the injury of the cornea is due to the antioxidant mechanism located in the corneal epithelium which is very important (Cejka *et al.*, 2016). Besides the immunomodulatory and anti-inflammatory properties of MSCs these stem cells reveal important antioxidant effects. MSCs can exert direct antioxidant activities through the secretion of antioxidant molecules. In this study there were significant decrease in NO level in MSCs treatment the expressions of antioxidant enzymes were restored and balanced with prooxidant enzymes in the epithelium this may be one mechanism supporting corneal reepithelialization and healing. In *Acanthamoeba* infected corneas treated with stem cells the levels of NO were significantly decreased compared to control group as in Table 5-7 this in agreement with study done by Bassi *et al.* (2012).

There were good response at early stage of intervention as the percentage of engraftments increased as showed in Table 8 and 9 which in agreements of study done by Crop *et al.* (2009) they showed that infusion time is an important factor for MSCs to effectively exert their treatment function.

Cejka *et al.* (2016) demonstrated that there were positive correlation between level of VEGF and NO which goes with our results as in Fig. 1.

Table 5: Compare NO level in group 1 to other groups

Groups	Test statistic ±SE	Sig.	95% Confidence interval	
			Lower bound	Upper bound
1 vs. 2	1.494±0.483	0.050 ^a	0.021	3.009
1 vs. 3	0.032±0.517	1.000 ^b	1.588	1.653
1 vs. 4	2.121±0.493	0.001 ^c	0.5760	3.667
1 vs. 5	1.639±0.643	0.194 ^d	3.655	0.375
1 vs. 6	1.257±0.604	0.438 ^e	3.150	0.635
1 vs. 7	0.667±0.604	0.954 ^f	2.560	1.225
1 vs. 8	3.534±0.533	0.000 ^g	1.8651	5.2041

^aSignificant decrease in NO level in group 1 in comparison to group 2 (p<0.05); ^bNon significant decrease in NO level in group 1 in comparison to group 3 (p>0.05); ^cHighly significant decrease in NO level in group 1 in comparison to group 4 (p<0.001); ^dNon significant decrease in NO level in group 1 in comparison to group 5 (p>0.05); ^eNon significant decrease in NO level in group 1 in comparison to group 6 (p>0.05); ^fNon significant decrease in NO level in group 1 in comparison to group 7 (p>0.05); ^gHighly significant decrease in NO level in group 1 in comparison to group 8 (p>0.001)

Table 6: Compare NO level in group 2 to other groups

Groups	Test statistic ±SE	Sig.	95% Confidence interval	
			Lower bound	Upper bound
2 vs. 3	1.462±0.508	0.095 ^a	3.0545	0.1305
2 vs. 4	0.627±0.483	0.897 ^b	0.8882	2.143
2 vs. 5	3.134±0.636	0.000 ^c	5.1263	1.141
2 vs. 6	2.751±0.596	0.000 ^d	4.6202	0.883
2 vs. 7	2.161±0.596	0.013 ^e	4.030	0.293
2 vs. 8	2.040±0.524	0.005 ^f	0.398	3.682

^aNon significant decrease in NO level in group 2 in comparison to group 3 (p>0.05); ^bNon significant decrease in NO level in group 2 in comparison to group 4 (p>0.05); ^cHighly significant decrease in NO level in group 2 in comparison to group 5 (p<0.001); ^dHighly significant decrease in NO level in group 2 in comparison to group 6 (p<0.001); ^eSignificant decrease in NO level in group 2 in comparison to group 7 (p<0.05); ^fSignificant decrease in NO level in group 2 in comparison to group 8 (p<0.05)

Table 7: Compare NO level in group 3 to other groups

Groups	Test statistic ±SE	Sig.	95% Confidence interval	
			Lower bound	Upper bound
3 vs. 4	2.089±0.517	0.003 ^a	0.4684	3.710
3 vs. 5	1.672±0.662	0.204 ^b	3.745	0.401
3 vs. 6	1.289±0.624	0.447 ^c	3.244	0.665
3 vs. 7	.6996±0.624	0.950 ^d	2.654	1.255
3 vs. 8	3.502±0.555	0.000 ^e	1.762	5.242

^aSignificant decrease in NO level in group 3 in comparison to group 4 (p<0.001); ^bNon significant decrease in NO level in group 3 in comparison to group 5 (p>0.05); ^cNon significant decrease in NO level in group 3 in comparison to group 6 (p>0.05); ^dNon significant decrease in NO level in group 3 in comparison to group 7 (p>0.05); ^eHighly significant decrease in NO level in group 3 in comparison to group 8 (p<0.001)

Table 8: Compare NO level in group 4 to other groups

Groups	Test statistic ±SE	Sig.	95% Confidence interval	
			Lower bound	Upper bound
4 vs. 5	3.7614±0.643	0.000 ^a	5.776	1.746
4 vs. 6	3.379±0.604	0.000 ^b	5.272	1.486
4 vs. 7	2.789±0.504	0.000 ^c	4.682	0.896
4 vs. 8	1.413±0.533	0.157 ^d	0.256	3.0825

^aHighly significant decrease in NO level in group 4 in comparison to group 5 (p<0.001); ^bHighly significant decrease in NO level in group 4 in comparison to group 6 (p<0.001); ^cHighly significant decrease in NO level in group 4 in comparison to group 7 (p<0.001); ^dNon significant decrease in NO level in group 4 in comparison to group 8 (p>0.05)

Table 9: Number and percentage of engraftment among study groups

Groups	Number of engraftments	Percentage
1	3	20
2	2	13
3	3	20
4	1	6.5

CONCLUSION

MSCs transferred onto the damaged corneal surface early after *Acanthamoeba* infection, accelerated corneal reepithelialization and restored the regenerated corneal epithelium and providing potential new modality for the treatment of corneal ulcer caused by *Acanthamoeba*. Corneal inflammation was suppressed and corneal neovascularization reduced as there were significant decrease in the VEGF and NO. The efficacy of stem cell treatment of *Acanthamoeba* infection corneal ulcer were marked in early stage of infection than late stage of infection. So, it is recommended to start treatment early and The dose of MSCs is another element that influences the response to treatment further study could use other doses and evaluate response to achieve the best results.

ACKNOWLEDGEMENTS

This study was supported by a research grant (Project No. 1-438-5598) through the Research Support of Taif University, Saudi Arabia. The funders had no role in study design, data collection and analysis, decision to publish or preparation of the manuscript.

REFERENCES

Al-Herrawy, A.Z. and K.A. Al-Rasheid, 1998. Identification of *Acanthamoeba* strains isolated from a freshwater course in Saudi Arabia. J. Egypt. Publ. Health Assoc., 73: 621-633.

Bassi, E.J., D.C. de Almeida, P.M.M. Moraes-Vieira and N.O.S. Camara, 2012. Exploring the role of soluble factors associated with immune regulatory properties of mesenchymal stem cells. Stem Cell Rev. Rep., 8: 329-342.

Cardine, S., T. Bourcier, C. Chaumeil, O. Zamfir and V. Borderie *et al.*, 2002. Clinical management and prognosis in *Acanthamoeba* keratitis: A retrospective study of 25 cases. J. Fr. Ophthalmologie, 25: 1007-1013.

Cashman, T.J., V. Gouon-Evans and K.D. Costa, 2013. Mesenchymal stem cells for cardiac therapy: Practical challenges and potential mechanisms. Stem. Cell. Rev. Rep., 9: 254-265.

Cejka, C., V. Holan, P. Trosan, A. Zajicova and E. Javorkova *et al.*, 2016. The favorable effect of Mesenchymal stem cell treatment on the antioxidant protective mechanism in the corneal epithelium and renewal of corneal optical properties changed after alkali burns. Oxid. Med. Cell. Longevity, 2016: 1-12.

Crop, M., C. Baan, W. Weimar and M. Hoogduijn, 2009. Potential of mesenchymal stem cells as immune therapy in solid-organ Transplantation. Trans. Intl., 22: 365-376.

Dart, J.K., V.P. Saw and S. Kilvington, 2009. *Acanthamoeba* keratitis: Diagnosis and treatment update 2009. Am. J. Ophthalmol., 148: 487-499.

Edrisian, G.H., M. Rezaian and M. Ghorbani, 2008. Medical Protozoology. 1st Edn., Tehran University of Medical Sciences, ?Tehran, Iran.,

Lim, N., D. Goh, C. Bunce, W. Xing and G. Fraenkel *et al.*, 2008. Comparison of polyhexamethylene biguanide and chlorhexidine as monotherapy agents in the treatment of *Acanthamoeba* keratitis. Am. J. Ophthalmol., 145: 130-135.

Ma, Y., Y. Xu, Z. Xiao, W. Yang and C. Zhang *et al.*, 2006. Reconstruction of chemically burned rat corneal surface by bone marrow-derived human mesenchymal stem cells. Stem cells, 24: 315-321.

Marciano-Cabral, F. and G. Cabral, 2003. *Acanthamoeba* spp: As agents of disease in humans. Clin. Microbiol. Rev., 16: 273-307.

O'day, D.M. and W.S. Head, 2000. Advances in the management of keratomycosis and *Acanthamoeba* keratitis. Cornea, 19: 681-687.

Reinhard, T., H. Spelsberg, L. Henke, T. Kontopoulos and J. Enczmann *et al.*, 2004. Long-term results of allogeneic penetrating limbo-keratoplasty in total limbal stem cell deficiency. Ophthalmol., 111: 775-782.

Safar, E.H., 2010. Involvement of the eye with *Acanthamoeba*. Proceedings of the 3rd International Conference on the Arab Society for Medical Research Vol. 5, October 12-14, 2010, JASMR, Libya, North Africa, pp: 191-198.

Schuster, F.L. and G.S. Visvesvara, 2004. Free-living amoebae as opportunistic and non-opportunistic pathogens of humans and animals. Intl. J. Parasitol., 34: 1001-1027.

Schuster, F.L. and G.S. Visvesvara, 2004. Opportunistic amoebae: Challenges in prophylaxis and treatment. Drug Resist. Update, 7: 41-51.

Schuster, F.L., 2002. Cultivation of pathogenic and opportunistic free-living amebas. Clin. Microbial. Rev., 15: 342-354.

- Shahbazi, F., S. Shahabi, B. Kazemi, M. Mohebbi, A.R. Abadi and Z. Zare, 2008. Evaluation of PCR assay in diagnosis and identification of cutaneous leishmaniasis: A comparison with the parasitological methods. *Parasitol. Res.*, 103: 1159-1162.
- Steinberg, J.P., R.L. Galindo, E.S. Kraus and K.G. Ghanem, 2002. Disseminated acanthamebiasis in a renal transplant recipient with osteomyelitis and cutaneous lesions: Case report and literature review. *Clin. Infect. Dis.*, 35: e43-e49.
- Stewart, M.C. and A.A. Stewart, 2011. Mesenchymal stem cells: Characteristics, sources and mechanisms of action. *Vet. Clin. Equine Pract.*, 27: 243-261.
- Tan D.T., J.K. Dart and E.J. Holland, 2012. Corneal transplantation. *Lancet*, 379: 1749-1761.
- Vural, A., Z.A. Polat, A. Topalkara, M.I. Toker and H. Erdogan *et al.*, 2007. The effect of propolis in experimental *Acanthamoeba* keratitis. *Clin. Exp. Ophthalmol.*, 35: 749-754.
- Walochnik, J., M. Duchene, K. Seifert, A. Obwaller and T. Hottkowitz *et al.*, 2002. Cytotoxic activities of alkylphosphocholines against clinical isolates of *Acanthamoeba* spp. *Antimicrob. Agents Chemother.*, 46: 695-701.
- Winiiecka-Krusnell, J. and E. Linder, 2001. Bacterial infections of free-living amoebae. *Res. Microbiol.*, 152: 613-619.