

Oral Gingival Myiasis: A Case Report

¹M. Moshref, ²G. Ansari and ¹A. Lotfi

¹Department of Oral and Maxillofacial Pathology, ²Department of Pedodontics, Dental School, Shahid Beheshti University of Medical Sciences, Tehran, Iran

Abstract: Oral-gingival myiasis is known as an infectious condition in human due to the invasion of tissue by larvae of houseflies. This study presents a case of gingival myiasis in an 8 year-old Iranian girl, living in a rural community. She had reported concerns an live worms (larvae) crawling out of her gingival sulcus. Clinically, patient had a swelling and a tunnel shaped sulcus in palatal gingiva of her maxillary right lateral incisor tooth. The lesion was treated by a simple curettage and irrigated with saline solution. The larvae were identified and removed during the procedure and sent for further parasitologic investigations. Oral Myiasis like the present case, is seen in cases with poor oral hygiene. Special care is needed to manage and control its clinical complications to prevent recurrence.

Key words: Myiasis, gingivae, magot, worm, mouth breathing

INTRODUCTION

The name Myiasis has been taken from Myia in Greek for fly which was firstly introduced by Hope (1840). Myiasis is well known and frequently reported in vertebrate animals but is quite rare in human (Zumpt, 1965; James, 1947). Oral myiasis is a condition in which the soft tissue of different parts in the oral cavity are invaded by the parasitic larvae of flies. Myiasis was defined by Zumpt (1965) as the infestation of live human and vertebrate animals with dipterous larvae, which at least for a certain period feed on the host's dead or living tissue, body liquid, substances or ingested food. Flies of the order diptera are responsible for myiasis, the commonly implicated genus being *Sarcophaga* and *Chlorosoma* (Zumpt, 1965; James, 1947).

It is mainly associated with poor oral hygiene and is considered as one of the tropical diseases. The usual place for its invasion is open wounds and dead tissue but cavities such as ears, nostrils and even the oral cavity could become involved (Erfan, 1980; Lim, 1974; Shah and Daya, 1984; Grennans and Gutierrez, 1990; Bozzo and Lima, 1992). The most frequently involved cases of oral myiasis are reported as being mouth breathers, alcoholism, senility, injuries of the head and face, mental handicapped and cerebral palsy patients (Zumpt, 1965; Lim, 1974; Grennans and Gutierrez, 1990; Bozzo and Lima, 1992). Ocular, aural, oesophageal, intestinal, cutaneous and nasal myiasis are also reported to be seen in patients living in poor conditions with no age limitation (Bozzo and Lima, 1992; Grennan, 1964).

Depending on the condition of the involved tissue, myiasis can be classified into 3 following categories: Accidental myiasis; when larvae ingested along with food. Semi-Specific myiasis; where the larvae are laid on necrotic tissue of the wound. Obligatory myiasis, in which larvae affects undamaged skin (Erfan, 1980).

Myiasis is also subdivided into cutaneous myiasis, myiasis of external orifices (aural, ocular, nasal, oral, vaginal and anal) and myiasis of internal organs (intestinal and urinary), based on its anatomic sites (Lim, 1974).

Cases of oral myiasis have been reported in epileptic patients with lacerated lips following a seizure, it has been noted to appear more in children with incompetent lips and thumb sucking habits (Shah and Daya, 1984), patients with advanced periodontal disease (Grennans and Gutierrez, 1990) or those who had a tooth extraction (Bozzo and Lima, 1992). Fungating carcinoma of buccal mucosa (Lim, 1974), have also been reported as well as patients with tetanus. To have such potential for Myiasis involvement, some of such infections occur in those who keep their mouth open to maintain their airway including habitual mouth breathers, where the mouth is kept open during sleep. These are considered as the most susceptible candidates of Myiasis (Grennans and Gutierrez, 1990; Grennans, 1964).

This study presents, a case of gingival myiasis in an 8 year old girl who had been referred to the Department of Oral and Maxillofacial Pathology at Shahid Beheshti University for Diagnosis and had received a subsequent treatment as described in detail.

CASE REPORT

An 8 year-old girl was referred to the Department of Oral Pathology Shahid Beheshti university-Tehran for consultation. The patient's medical history was clear and her family history was noncontributory. The child's oral hygiene was good and her lips were somewhat incompetent (Fig. 1).

She was well oriented and cooperative with no history of pain and discomfort. However, she pronounced her worries on what she called worms coming out of her gingival sulcus, six of which had been collected and handed to the lab in a bottle.

Radiographic examination revealed no changes in the bony structure.

A thorough examination revealed that the oral mucosa was with a normal texture and color, except the upper right lateral incisor area where the complaint was

pointed at the palatal side (Fig. 2). The affected gingiva was erythematous and edematous. There was a tunnel shaped orifice, 2 mm in diameter, at the centre of the site. Frequent examination of the orifice and the tunnel suggested objects were in the move at times. The treatment plan was based on encouraging insect/larvae, if any to come out of the area. This was performed by closing the opening of the hole, using vaselin. This would provide hypoxia for about 1-2 min. A further manipulation was also performed using pair of surgical forceps associated with finger massage. The live maggots (larvae) were then removed from the lesion (Fig. 3 and 4).

Further search of the lesion revealed two dead larvae in the depth of the lesion. The larvae were measured at about 10 mm in length and 2-3 mm in diameter with a yellowish-white body and a darker head portion in macroscopic examination using stereo-microscope.

The live and active larvae was then stored in an isotonic saline solution and sent to a parasitology laboratory, where the larvae was nourished and in less than a week it was changed to a mature fly (Fig. 5).

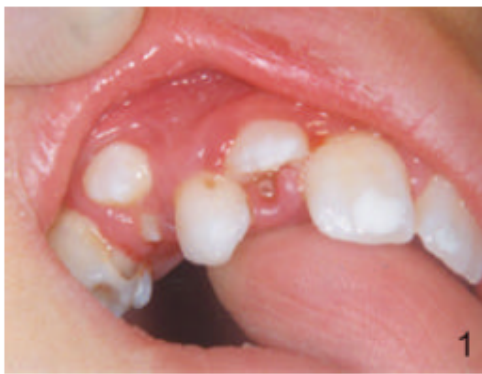

Fig. 1: The site of the larvae before any attempt for their removal

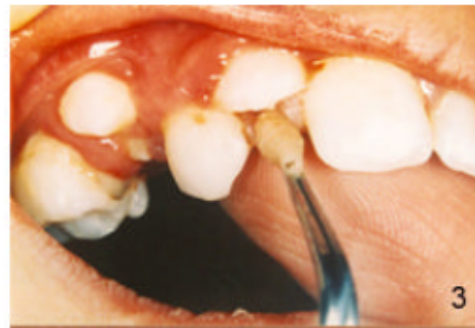

Fig. 3: The live maggots (larvae) while being removed from the lesion

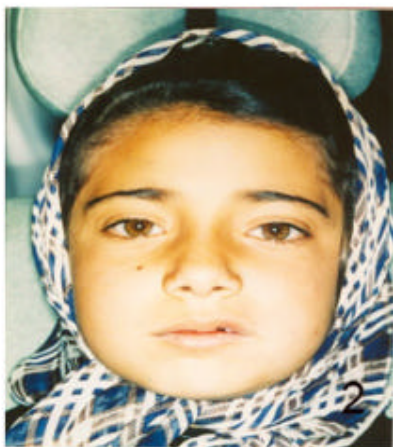

Fig. 2: Patient's incompetent lip is noticeable in her clinical photograph

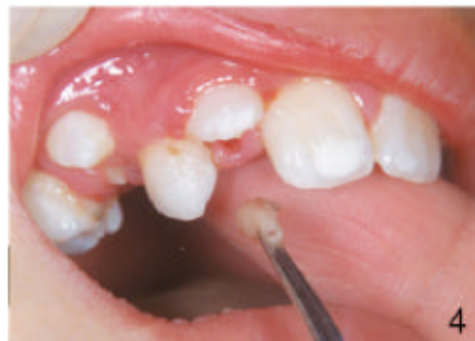

Fig. 4: Removed larvae is shown with its empty site on palatal surface of 12




Fig. 5: Maggot seen developed from the original larvae

The lesion was treated with a careful curettage and irrigation technique using sufficient amount of saline solution.

A definitive entomologic identification of the infesting parasite was established by the laboratory as a larvae of Sarcophagidae family, genus *Wohlfahrtia*.

Follow up examination of the patient, 5 days later, revealed decrease in the gingival swelling. Complete healing of the lesion was noted after 2 weeks.

DISCUSSION

The larvae of diptera develops normally in degenerating biologic tissues. At times, however, female flies deposit eggs, or larvae on open wounds or even in the natural body cavities of the neglected patients or unprotected sleeping individuals (Hargreaves and Morrison, 1965; Ali Khan and Ali Khan, 1974).

Zumpt (1965) stressed the important criterion of the myiasis definition as being the larvae continuation of its normal development in the host's body tissue at least temporarily. Cunningham and Zanga (1974) stated that, in general, myiasis is quite uncommon in children, it happens only if the indicators of a predisposing lesion attracts flies of oviposition. It has been noted that sarcophaga species could cause intestinal, traumatic, dural and nasal myiasis in both children and adults (Ali Khan and Ali Khan, 1974; Kenney *et al.*, 1976).

Ali-Khan and Ali-Khan (1975) reported 2 cases of human intestinal and cutaneous myiasis caused by sarcophaga so far. Two cases of gingival myiasis and one case of dental socket involvement had also been reported earlier in Iran (Zumpt, 1965; Sahba, 1981).

However, a report suggests that myiasis of the eye caused by diptera, ostridae is known to have occurred more previous in Iran (Minar, 1976).

Cutaneous myiasis has been suggested as causing no more than an unpleasant nuisance and the removal of the larvae constitutes a quick cure (Schreiber *et al.*, 1964). Such a result could soon be achieved in cases of oral myiasis as they can be detected by simple observation before any serious tissue involvement by larvae occurs. When larvae invades the tissues which are not easily seen by direct visual evaluation, the situation should be watched and investigated more seriously as it sometimes could be even fatal (Schreiber *et al.*, 1964).

It appears that, with the maturation process of the larvae, the maggot cause tissue inflammation. It's subsequent discomfort causes the patient to seek consultation with a medical or a dental specialist, such findings have also been previously reported (Salmon *et al.*, 1970).

The eggs are hatched in less than a week with its development period being highly dependent on the day temperature (Ali Khan and Ali Khan, 1975).

In the case reported here, it can be assumed that the eggs or larvae had been deposited either directly on the gingival surface, or indirectly on food and subsequently were transferred to the gingival sulcus. After, while the larvae hatched and started its development. The larvae had then penetrated into the gingival tissue where its development had rapid caused a very concise localized tissue destruction.

CONCLUSION

Myiasis is a very rare oral infectious condition caused by the insect's larvae. This case was treated by repeated irrigation and exertion of the larvae from its nest in gingivae.

REFERENCES

- Ali Khan, F.E.A. and Z. Ali Khan, 1974. Two cases of human Sarcophaga (Diptera Sarcophagidae) myiasis in Quebec, with description of larvae. *Can. J. Zool.*, 52: 643-647.
- Ali Khan, F.E.A. and Z. Ali Khan, 1975. A case of traumatic dermal myiasis in Quebec caused by phormia (Megin) (Diptera: Calliphoridae). *Can. J. Zool.*, 53: 1472-1476.
- Bozzo, L. and I.A. Lima, 1992. Oral myiasis caused by Sarcophagidae in an extraction wound. *Oral Surg. Oral Med. Oral Pathol.*, 74: 733-735.
- Cunningham, D.J. and J.R. Zanga, 1974. Myiasis of External Auditory Meatus. *J. Pediatr.*, 48: 857-858.
- Erfan, F., 1980. Gingival myiasis caused by Diptera (Sarcophaga). *Oral Surg. Oral Med. Oral Pathol.*, 49: 148-150.

- Grennan, S., 1964. A case of oral myiasis. *Br. Dental J.*, 80: 2-4.
- Grennan, S. and Y. Gutierrez, 1990. Diagnostic pathology of parasitic infections with clinical correlations. Philadelphia and London: Lea and Febiger, pp: 489-496.
- Hargreaves, W.H. and R.L.G. Morrison, 1965. The practice of tropical medicine London. Staples Press, pp: 403-406.
- Hope, F.W., 1840. On Insects and their larvae occasionally found in human body. *R. Ent. Soc. Trans.*, 2: 256-271.
- James, M.T., 1947. The flies that cause myiasis in Man, Washington, D.C, 1947. U.S Department of Agriculture, Misc. Publication No. 631.
- Kenney, M. *et al.*, 1976. Two case of enteric myiasis in man: Pseudomyiasis and true instar myiasis. *Am. J. Clin. Pathol.*, 66: 786-791.
- Lim, S.T., 1974. Oral Myiasis: A review. *Singapour Dental J.*, 13: 33-34.
- Minar, L., 1976. A case of eye myiasis is caused by first instar larvae of *Oestrus ovis* L. (Diptera: Oestride) in Iran. *M Folia Parasitol.*, 23: 283-284.
- Sahba, G.H., 1981. A case of gingival myiasis in man and animals in IRAN. (Abst) 3rd International Congress for Tropical Medicine, Malaria, Canada, pp: 22-93.
- Salmon, P.F., E.P. Catts and W.G. Knox, 1970. Human dermal myiasis caused by rabbit bot fly in connecticut. *J. Am. Med. Assoc.*, 213: 33-36.
- Schreiber, M.M., N.M. Schuenmell and J. Sampsell, 1964. Human myiasis. *J. Am. Med. Assoc.*, 188: 828-829.
- Shah, H.A. and P.K. Daya, 1984. Dental myiasis. *J. Oral Med.*, 39: 210-211.
- Zumpt, F., 1965. Myiasis in man and animals in the old world. In: A Text book for Physician, Veterinarians and Zoologists. London: Butterworth and Co. Ltd, pp: 109.